

UC Davis

Dermatology Online Journal

Title

Melanoma occurrence under long-term etanercept treatment for psoriasis: a case report

Permalink

<https://escholarship.org/uc/item/9qf6t40j>

Journal

Dermatology Online Journal, 22(10)

Authors

Atzori, Laura
Pilloni, Luca
Murgia, Severino
et al.

Publication Date

2016

DOI

10.5070/D32210032910

Copyright Information

Copyright 2016 by the author(s). This work is made available under the terms of a Creative Commons Attribution-NonCommercial-NoDerivatives License, available at <https://creativecommons.org/licenses/by-nc-nd/4.0/>

Letter

Melanoma occurrence under long-term etanercept treatment for psoriasis: a case report

Laura Atzori MD^{1,2}, Luca Pilloni MD³, Severino Murgia MD², Cristina Mugheddu MD², Monica Pau MD², Franco Rongioletti (Prof. and Chair) MD^{1,2}

Dermatology Online Journal 22 (10): 16

¹Dermatology Clinic, Department of Medical and Public Science, University of Cagliari, Italy

²Struttura Complessa di Dermatologia, Azienda Ospedaliero, University of Cagliari, Italy

³Pathology Unit, Department of Surgical Science, University of Cagliari, Italy

Correspondence:

Laura Atzori
Clinica Dermatologica
Via Ospedale 54
09124 Cagliari, Italy
Tel. 00390706092324 Fax. 00390706092580
Email: atzoril@unica.it

Abstract

Melanoma occurrence during treatment with anti-tumor necrosis factor is considered an incidental event, although very recent studies suggest a risk. Etanercept is a fusion protein that binds the tumor necrosis factor receptor and is included among TNF inhibitors, approved for the treatment of several autoimmune diseases, such as psoriasis.

We described a 79-year-old man with psoriasis, being treated with etanercept, who presented with a new brown to black macule on his right shoulder; this was immediately surgically excised. Histology showed a superficial spreading melanoma, 1.2 mm Breslow thickness, one mitosis/hpf, with no vascular or neural invasion (stage T2b). Sentinel lymph node biopsy was negative. There were no apparent melanoma risk factors: normal total nevus count, photo type IV, no childhood sunburns, no family history of melanoma, and no previous immune suppressive drugs and/or phototherapies. Etanercept 50 mg/week had been administered continuously for 5 years before the melanoma occurrence. After etanercept withdrawal his psoriasis slowly, but progressively relapsed.

Conclusions

This is the first melanoma case reported in a psoriasis patient, among a cohort of 216 patients since 2008 treated with anti-TNF, living in Sardinia, an Italian region considered at low risk for melanoma. This case supports the role of drug-induced immune surveillance compromise, in the absence of other personal and environmental confounding factors for melanoma. The possible anti-tumor necrosis factor association with melanoma is a controversial issue. Questions remain about the validity of this association, recommendations about preventative measures, and timing of skin screening efforts. In addition, the best choice for psoriasis treatment after melanoma detection has not been thoroughly studied.

Key words: Melanoma, tumor necrosis factor inhibitors, anti-TNF alpha, etanercept, psoriasis treatment.

Introduction

Melanoma occurrence during long-term tumor necrosis factor inhibition is a controversial issue. Although an increased risk for non-melanoma skin cancer has been associated with all immunosuppressive treatments, melanoma cases are regarded as incidental [1]. Conversely, case reports suggest a risk for the entire class of anti-TNF drugs [2-8]. In psoriasis patients, a recent meta-analysis excludes an increased risk of melanoma related to the natural course of the disease [9], but also no increased risk for melanoma was observed during anti-TNF randomized controlled studies [10, 11].

Etanercept is a recombinant human fusion protein, which binds to the 75 kilo-Dalton portion of the tumor necrosis factor receptor (TNFR), functioning as a decoy receptor, decreasing the natural effects of TNF. Hence, it is included among TNF inhibitors, a well-documented class of disease-modifying therapy approved for several autoimmune diseases, such as rheumatoid arthritis, ankylosing spondylitis, and psoriasis [12]. The present report is unique, as it describes the first melanoma observed in Southern Sardinia, a major Mediterranean island, considered at low risk for melanoma [13], occurring in a 79-year-old man during etanercept therapy for psoriasis. The case supports the hypothesis that anti-TNF inhibitors might be a risk factor for melanoma development in psoriasis patients, especially during long-term treatment.

Case synopsis

Our patient presented to his tri-annual visit with a new brown to black macule on his right shoulder, 1 x 0.7 cm, with a finely raised, palpable surface (Figure 1).

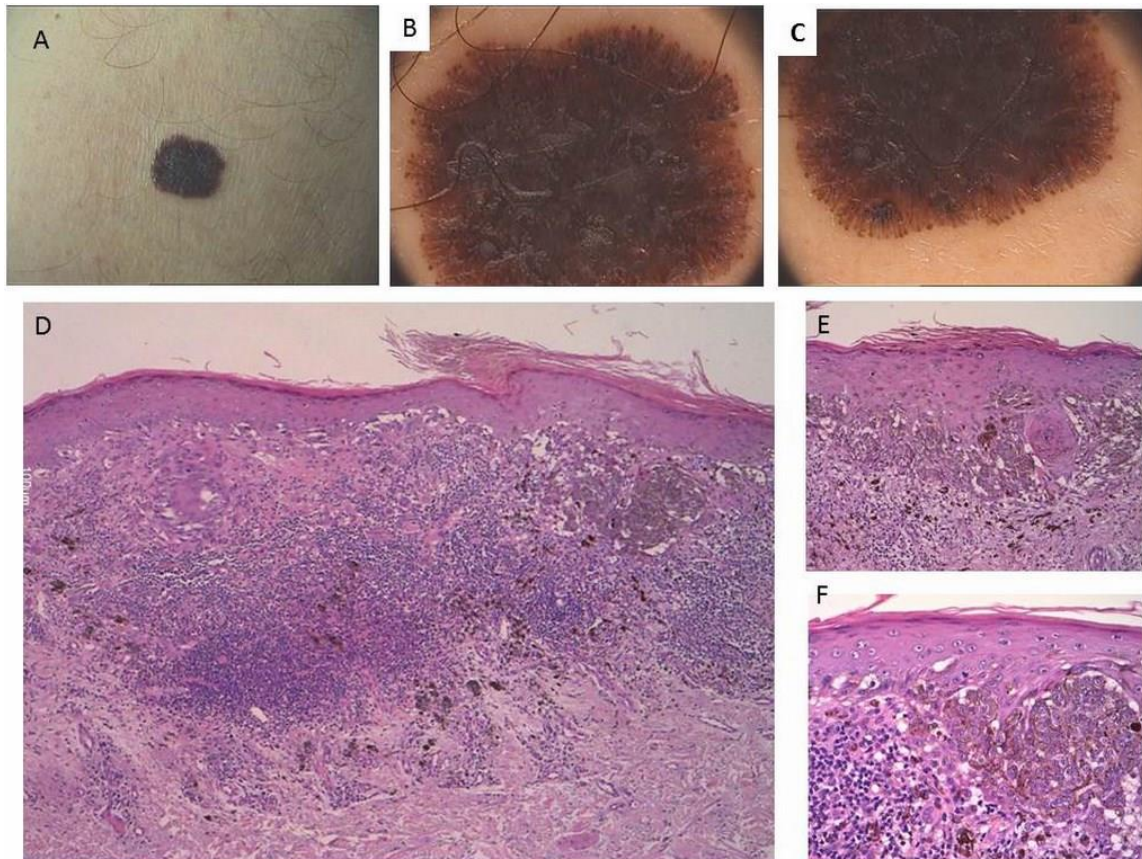


Figure 1. Brown to black macule on the right shoulder of a white Caucasian man, 1 x 0.7 cm, with a finely raised, palpable surface (inset A), Dermoscopy shows a compound pattern, with irregular network, de-structured central areas partially covered by grey-whitish veil, radial strikes, pseudopods; marginal brown globules (B, C). Histologic examination (D; H&E 4x) confirmed an irregular lentiginous proliferation of atypical epithelioid melanocytes, with extensive substitution of basal keratinocytes, dermo-epidermal clefts, and small nests of melanocytes with similar cytology predominantly in intra-epidermal location (D, H&E 4x; E, H&E 10x). A mild density pagetoid spread is detected at higher power (F; H&E 20x). An irregular dermal inflammatory infiltrate was also present.

Dermoscopy showed a compound pattern: an irregular network, de-structured central areas partially covered by grey-whitish veil, radial streaks, pseudopods, and marginal brown globules. Surgical excision produced a histologic diagnosis of superficial spreading melanoma (Figure 1): Breslow thickness 1.2 mm, one mitosis/hpf, no vascular or neural invasion (stage T2b). Sentinel lymph node biopsy was negative. Investigation for melanoma risk factors was unremarkable: normal total nevus count, photo type IV skin, no childhood sunburns, nor family history of melanoma. The medical chart reported mild hypertension, and atrial fibrillation treated with daily 5 mg enalapril, 8 mg doxazosin, and 250 mg ticlopidine. His psoriasis diagnosis dated back to 2000 and was controlled with topical therapy and cycles of oral retinoids. Periods of methotrexate use up to 15 mg/week were required at times. The use of etanercept had produced a sustained remission. Owing to melanoma, etanercept was dismissed and a slow, but progressive relapse of psoriasis and psoriatic arthritis occurred (Figure 2). Methotrexate treatment was reintroduced at 15 mg subcutaneously once weekly, with slow, but sustained improvement.

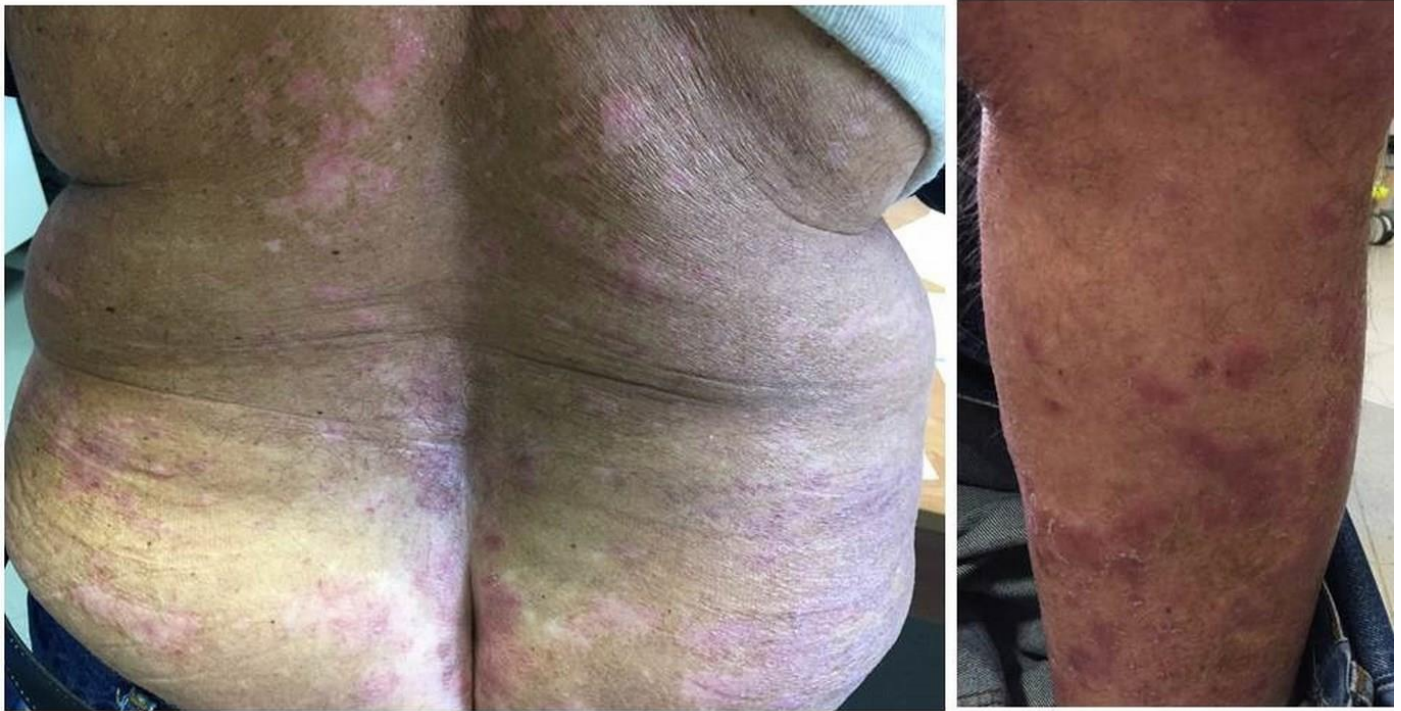

Figure 2. Psoriasis relapse after etanercept discontinuation, treated with methotrexate IM 15 mg/week with partial improvement

After 1 year, the patient's psoriasis is well controlled by the weekly 15 mg methotrexate subcutaneous injection and topical medication with emollients, short courses of calcipotriol ointment alone or with medium potency corticosteroid cream. There have been no melanoma recurrences and no new melanocytic lesions of concern.

Conclusions

This reported melanoma is the first observed among a cohort of 216 psoriasis patients, treated regularly with anti-TNF inhibitors at the Dermatology Clinic of Cagliari State University. With regard to the incidence of melanoma in the Italian population, data from the Italian Network of Cancer Registries (AIRTUM) confirm the well-known increasing melanoma trend, with an annual percentage change (APC) of 3.2 from 1999 to 2015, and a mean of 4000 new cases/year in males [13]. Considering the age of our patient, the expected rate in the 75-79 years age is of 30 new skin melanoma diagnoses per 100,000 males. The Italian national statistical institute (ISTAT, census 2011) has registered 10,072 males in the same age range living in the Province of Cagliari, thus a frequency of 3 new melanoma cases/year is predictable. Our institute database on melanoma cases records 4 new diagnoses in males within the considered age between the years 2011 and 2015. However, the catchment area is somewhat wider than the province of Cagliari, being the reference public institution of Southern Sardinia (unpublished data).

The patient had no high-risk individual predisposing factors, nor had he undergone previous immune suppressive treatment. Of course, natural sun bathing was encouraged, as he was living on a Mediterranean island. In addition, one must also consider the recent suggestion of a paradoxical protective role of sun exposure [14, 15]. It has been postulated that chronic anti-TNF

treatment, affecting immune surveillance and collateral interferon inhibition could impair defenses against melanoma cell proliferation [2, 6].

Surprisingly, melanoma reports are few with respect to anti-TNF drugs worldwide [2-9]. A French study suggests that a critical point is observation timing; 47.6 months is the mean period from beginning treatment to melanoma occurrence in their experience [6]. Our patient was treated with etanercept for 5 years before his melanoma diagnosis. Local tumor behavior seems aggressive, as in the space of 3 months from the last visit it had reached 1.2 mm of thickness, with one mitosis. Single case reports support an aggressive behavior [2-5], as well as a Swedish population study, which found an increased risk (50%) of invasive, but not *in situ* melanoma associated with anti-TNF inhibitors, despite careful clinical vigilance [7]. With regard to diagnosis and therapy of the melanoma patients, our dermatology clinic follows the European guidelines [16], and the updated recommendation of the Italian Association of Medical Oncology (AIOM, www.aiom.it/). Therapeutic decisions are carried out by the oncologist, working in our interdisciplinary team.

Unanswered questions include characterization of the carcinogenesis risk, timing from drug exposure to melanoma occurrence, as well as consensus on recommended timing for skin screening. Our experience suggests that all patients eligible for anti-TNF agents should undergo a dermatologic examination before starting therapy and then every 3-6 months thereafter, to detect new pigmented lesions or changes in pre-existing nevi. Another crucial determination is how to treat psoriasis after removal of TNF inhibitors. Our patient was disappointed with the severity of the melanoma diagnosis, and its implications. He had not considered the possibility of melanoma when he initiated etanercept therapy, although a generic risk of skin cancer development had been discussed. The challenge of supporting and treating the patient prompted us to re-introduce methotrexate, encouraged by some anti-melanoma activity documented in experimental models [17, 18].

References

1. Moulis G, Sommet A, Béné J, Montastruc F, Sailler L, Montastruc JL, Lapeyre-Mestre M. Cancer risk of anti-TNF- α at recommended doses in adult rheumatoid arthritis: a meta-analysis with intention to treat and per protocol analyses. *PLoS One*. 2012;7(11):e48991. doi: 10.1371/journal.pone.0048991. Epub 2012 Nov 14. [PMID: 23155441]
2. Kouklakis G, Efremidou EI, Pitiakoudis M, Liratzopoulos N, Polychronidis ACh. Development of primary malignant melanoma during treatment with a TNF- α antagonist for severe Crohn's disease: a case report and review of the hypothetical association between TNF- α blockers and cancer. *Drug Des Devel Ther*. 2013;7:195-9. doi: 10.2147/DDDT.S41889. Epub 2013 Mar 27. [PMID:23569358]
3. Alcalde-Vargas A, Trigo-Salado C, Leo-Carnerero E, Lorente-Lavirgen AI. Malignant melanoma in a patient with Crohn's disease and treated with anti-TNF alpha. *Rev Esp Enferm Dig*. 2013 Nov-Dec;105(10):639-40. [PMID: 24641467]
4. Katoulis AC, Kanelleas A, Zambacos G, Panayiotides I, Stavrianeas NG. Development of two primary malignant melanomas after treatment with adalimumab: a case report and review of the possible link between biological therapy with TNF-alpha antagonists and melanocytic proliferation. *Dermatology*. 2010 Aug;221(1):9-12. doi: 10.1159/000300136. Epub 2010 May 13. [PMID:20484878]
5. Safa G, Fromentoux S, Darrieux L, Hogenhuis JA, Tisseau L. Nodal Melanoma Metastasis under Infliximab Therapy in a Patient with Nevroid Melanoma First Misdignosed as Benign Nevus: A Potentially Dangerous Diagnostic Pitfall in the Era of Biologic Therapies. *Case Rep Dermatol*. 2013 Oct 11;5(3):290-4. doi: 10.1159/000355670. eCollection 2013. [PMID: 24403892]
6. Chabbert C, Adamski H, Guillet G, Sassolas B, Misery L, Perrinaud A, Machet L, Quereux G, Esteve E, Solau-Gervais E, Saraux A, Polard E, Lesimple T, Le Gall F, Dreno B, Dupuy A. Cutaneous melanoma in patients treated with tumour necrosis factor inhibitors: a retrospective series of 15 patients. *J Eur Acad Dermatol Venereol*. 2014 Nov;28(11):1540-4. doi: 10.1111/jdv.12347. Epub 2013 Dec 13. [PMID: 24329560]
7. Raaschou P, Simard JF, Holmqvist M, Askling J; ARTIS Study Group. Rheumatoid arthritis, anti-tumor necrosis factor therapy, and risk of malignant melanoma: nationwide population based prospective cohort study from Sweden. *BMJ*. 2013 Apr 8;346:f1939. doi: 10.1136/bmj.f1939. [PMID: 23568792]
8. Nardone B., Hammel JA, Raisch DW, Weaver LL, Schneider D, West DP. Melanoma associated with TNF-alpha inhibitors: a research on adverse drug events and reports (RADAR) project. *Br J Dermatol*. 2014 May;170(5):1170-2. doi: 10.1111/bjd.12779. [PMID: 24328939]
9. Pouplard C, Brenaut E, Horreau C, Barnetche T, Misery L, Richard M, Aractingi S, Aubin F, Cribier B, Joly P, Jullien D, Le-Maître M, Ortonne J-P, Paul C. Risk of cancer in psoriasis: a systematic review and meta-analysis of epidemiological studies. *J Eur Acad Dermatol Venereol*. 2013 Aug;27 Suppl 3:36-46. doi:10.1111/jdv.12165. Review. [PMID: 23845151]

10. Askling J, Fahrbach K, Nordstrom B, Ross S, Schmid CH, Symmons D. Cancer risk with tumor necrosis factor alpha (TNF) inhibitors: meta-analysis of randomized controlled trials of adalimumab, etanercept, and infliximab using patient level data. *Pharmacoepidemiol Drug Saf.* 2011 Feb;20(2):119-30. doi: 10.1002/pds.2046. Epub 2010 Dec 7. [PMID: 21254282]
11. Burmester GR, Panaccione R, Gordon KB, McIlraith MJ, Lacerda AP. Adalimumab: long-term safety in 23 458 patients from global clinical trials in rheumatoid arthritis, juvenile idiopathic arthritis, ankylosing spondylitis, psoriatic arthritis, psoriasis and Crohn's disease. *Ann Rheum Dis.* 2013 Apr;72(4):517-24. doi: 10.1136/annrheumdis-2011-201244. Epub 2012 May 5. Review. [PMID:22562972]
12. Lis K, Kuzawińska O, Bałkowiec-Iskra E. Tumor necrosis factor inhibitors - state of knowledge. *Arch Med Sci.* 2014 Dec 22;10(6):1175-85. doi: 10.5114/aoms.2014.47827. [PMID: 25624856]
13. Busco S, Buzzoni C, Mallone S, Trama A, Castaing M, Bella F, et al. Italian cancer figures - Report 2015: The burden of rare cancers in Italy. *Epidemiol Prev.* 2016 Jan-Feb;40(1 Suppl 2):1-120. [PMID: 26951748]
14. Rosso S, Sera F, Segnan N, Zanetti R. Sun exposure prior to diagnosis is associated with improved survival in melanoma patients: results from a long-term follow-up study of Italian patients. *Eur J Cancer.* 2008 Jun;44(9):1275-81. doi:10.1016/j.ejca.2008.03.009. Epub 2008 Apr 10. [PMID: 18406602]
15. Fortes C, Mastroeni S, Bonamigo R, Mannooranparampil T, Marino C, Michelozzi P, Passarelli F, Boniol M. Can ultraviolet radiation act as a survival enhancer for cutaneous melanoma? *Eur J Cancer Prev.* 2016 Jan;25(1):34-40. doi: 10.1097/CEJ.000000000000127. [PMID: 25646933]
16. Garbe C, Peris K, Hauschild A, Saiag P, Middleton M, Spatz A, et al. Diagnosis and treatment of Melanoma. European consensus-based interdisciplinary guideline--Update 2012. *Eur J Cancer.* 2012 Oct;48(15):2375-90. doi: 10.1016/j.ejca.2012.06.013. Epub 2012 Sep 13. [PMID: 22981501]
17. Nihal M, Wu J, Wood GS. Methotrexate inhibits the viability of human melanoma cell lines and enhances Fas/Fas-ligand expression, apoptosis and response to interferon-alpha: rationale for its use in combination therapy. *Arch Biochem Biophys.* 2014 Dec 1;563:101-7. doi: 10.1016/j.abb.2014.04.019. Epub 2014 May 23. [PMID: 24862567]
18. Schilrreff P, Cervini G, Romero EL, Morilla MJ. Enhanced antimelanoma activity of methotrexate and zoledronic acid within polymeric sandwiches. *Colloids Surf B Biointerfaces.* 2014 Oct 1;122:19-29. doi: 10.1016/j.colsurfb.2014.06.033. Epub 2014 Jun 20. [PMID: 25016541]