

UCLA

UCLA Previously Published Works

Title

Exacerbation of Minimal Change Disease Following mRNA COVID-19 Vaccination.

Permalink

<https://escholarship.org/uc/item/9p79q394>

Authors

Pirzadeh, Afshin

Emami, Sina

Zuckerman, Jonathan

et al.

Publication Date

2023-11-09

DOI

10.12659/AJCR.941621

Peer reviewed

Received: 2023.06.29

Accepted: 2023.09.15

Available online: 2023.09.29

Published: 2023.11.09

Exacerbation of Minimal Change Disease Following mRNA COVID-19 Vaccination

Authors' Contribution:

Study Design A
Data Collection B
Statistical Analysis C
Data Interpretation D
Manuscript Preparation E
Literature Search F
Funds Collection G

ABE 1 **Afshin Pirzadeh**
AE 1 **Sina Emami**
E 2 **Jonathan E. Zuckerman**
E 1 **Niloofar Nobakht**

1 Division of Nephrology, Department of Medicine, David Geffen School of Medicine at University of California Los Angeles (UCLA), Los Angeles, CA, USA
2 Department of Pathology, David Geffen School of Medicine at University of California Los Angeles (UCLA), Los Angeles, CA, USA

Corresponding Author: Afshin Pirzadeh, e-mail: APirzadeh@mednet.ucla.edu

Financial support: None declared

Conflict of interest: None declared

Patient: Male, 33-year-old
Final Diagnosis: Minimal change disease relapse
Symptoms: Edema • nephrotic syndrome
Clinical Procedure: Kidney biopsy
Specialty: Nephrology

Objective: Unusual clinical course

Background: Minimal change disease is a common cause of nephrotic syndrome in adults. There are few reported cases of vaccine-related podocytopathy with nephrotic-range proteinuria in the setting of a minimal change disease history. There have been rare reports of acute renal damage following vaccination to prevent COVID-19 and some cases of exacerbation of ongoing nephropathy. This report is a 33-year-old man with a 22-year history of nephrotic syndrome due to minimal change disease which exacerbated following a third dose of an mRNA SARS-CoV-2 vaccine for COVID-19.

Case Report: We report a case of nephrotic syndrome after the third dose of the BNT162b2 mRNA COVID-19 vaccine. The patient presented with mild edema in the bilateral lower extremities and sacrum. Laboratory investigations confirmed nephrotic-range proteinuria and hypoalbuminemia. A kidney sonogram demonstrated mild renal parenchymal disease and a small non-obstructing right renal calculus. Renal biopsy revealed diffuse podocyte foot process effacement, punctuate IgG podocyte cytoplasmic staining, and minimal global glomerulosclerosis, consistent with a diagnosis of a diffuse podocytopathy with a minimal change disease phenotype. The patient was started on oral prednisone treatment, which led to remission of his symptoms and normalization of lab test results with normal BUN and Cr and resolution of proteinuria. Treatment was tapered off over the course of 28 weeks.

Conclusions: We presents a case of longstanding minimal change disease that showed exacerbation following a third dose of an mRNA vaccine for SARS-CoV-2. Although this may be a rare association, this case supports that patients with chronic glomerulonephritis need to be monitored.

Keywords: BNT162 vaccine • COVID-19 • Nephrosis, Lipoid • Nephrotic Syndrome • Vaccination

Full-text PDF: <https://www.amjcaserep.com/abstract/index/idArt/941621>



1659



—



2



10



Publisher's note: All claims expressed in this article are solely those of the authors and do not necessarily represent those of their affiliated organizations, or those of the publisher, the editors and the reviewers. Any product that may be evaluated in this article, or claim that may be made by its manufacturer, is not guaranteed or endorsed by the publisher

Background

The COVID-19 pandemic has prompted a global vaccination campaign, with numerous vaccines being developed and administered worldwide, which saved millions of lives globally. The Pfizer-BioNTech COVID-19 mRNA vaccine, BNT162b2, has shown remarkable safety and efficacy in preventing COVID-19, with a 95% effectiveness rate [1]. Renal injury following COVID-19 vaccination is a rare adverse event reported in some cases. Studies have shown that acute kidney injury (AKI) can occur after vaccination, particularly in elderly patients [2].

Minimal change disease (MCD) is a common cause of nephrotic syndrome, particularly in children. Its name – “minimal change” – refers to the lack of significant changes visible under light microscopy. The exact cause of MCD is often idiopathic (unknown), but it can also be secondary to certain factors such as infections (eg, tuberculosis and hepatitis C virus), neoplasms (eg, leukemia and lymphoma), allergies, drugs (eg, NSAIDs and antibiotics), and other glomerular diseases (eg, IgA nephropathy, SLE, diabetes mellitus, and HIV). MCD presents with proteinuria, resulting in edema and intravascular volume depletion. Notably, it shows a positive response to corticosteroid therapy. Diagnosis is made based on clinical presentation and laboratory tests, including urine analysis, urine collection for quantitating proteinuria, complete metabolic panel, complete blood count, and tests to rule out other secondary causes [3].

There are few reported cases of minimal change disease following COVID-19 vaccination, and most of the cases improved with steroid management [4]. Teragaki et al reported a case of relapse of minimal change disease (MCD) following the third dose mRNA COVID-19 vaccination in a 43-year-old man with a 29-year history of MCD [5].

Here, we report the case of a 33-year-old man with 22 years history of nephrotic syndrome due to minimal change disease exacerbated following a third dose of an mRNA SARS-CoV-2 vaccine for COVID-19.

Case Report

A 33-year-old man with a past medical history of nephrotic syndrome at age 11 presented to our clinic with bilateral lower-extremity swelling and frothy urine 10 days after receiving his third dose of the BNT162b2 mRNA COVID-19 vaccine. He also reported bilateral leg numbness and lower back pain. He had no recent history of trauma or falls, and no bowel or bladder incontinence was noted. He ambulated safely and had no recent changes in urine output. He reported no fevers or chills, nausea, vomiting, chest pain, shortness of breath, or abdominal pain, and had no prior history of similar symptoms. He had

no recent travel history, no sick contacts, and no family history of autoimmune disease, coagulopathy, or neurologic disorders.

The patient quit smoking about 22 months prior to his symptoms, with his current tobacco use limited to chewing. He also reported current alcohol use and denied any illicit drug use. He was not taking any prescription or over-the-counter medications and had no history of nonsteroidal anti-inflammatory drug use.

Start vital sign with BP, heart rate, respiration rate, oxygen saturation, body temperature and BMI. His vital signs upon presentation were body temperature 36.7°C, blood pressure 167/107 mmHg, heart rate 95 bpm, respiration rate 18 bpm, and oxygen saturation 96% on room air, with a body mass index of 32.56 kg/m². The physical examination was consistent with bilateral lower extremity edema.

The initial laboratory investigations revealed a serum creatinine level of 0.85 mg/dL, blood urea nitrogen of 14 mg/dL, albumin of 2.2 g/dL, and total protein of 5.2 g/dL. Urinalysis showed 3+ protein and 1+ blood, while the 24-h urine protein was 7.5 g, with a urine protein creatinine (UPC) of 9.3 g/g.

An immunologic workup, including PLA2R, hepatitis panel, HIV, IFE, Parvovirus, ANA, C3/C4, cryocrit, C-ANCA, P-ANCA, RPR, and nasopharyngeal COVID-19 polymerase chain reactions, provided no significant findings. An abdominal ultrasound confirmed mildly hyperechoic kidneys, suggestive of mild renal parenchymal disease, with no hydronephrosis, and a small non-obstructing right renal calculus.

Patient's kidney biopsy (**Figure 1**) showed a cortex containing 33 glomeruli (3 globally sclerotic). The glomeruli were normal by light microscopy, without lesions of segmental sclerosis. There was minimal acute tubular epithelial cell injury and minimal interstitial fibrosis/tubular atrophy (<5%). There was no interstitial inflammation. Arteries and arterioles were unremarkable. Immunofluorescence studies were significant for diffuse global weak punctate IgG, kappa and lambda podocyte cytoplasmic staining, and low-grade segmental granular mesangial staining for IgA (1+), IgM (1-2+), C3 (1+), and kappa and lambda light chains (both trace). Electron microscopy demonstrated complete podocyte foot process effacement associated with variable microvillous transformation of podocytes, as well as small electron-dense deposits in segmental mesangial regions. There were no tubuloreticular inclusions. No deposits displayed any substructure.

The findings in the biopsy were compatible with a diffuse podocytopathy with a minimal change disease phenotype and provided an anatomic etiology for the nephrotic syndrome. The low-grade mesangial deposits likely were latent IgA deposits

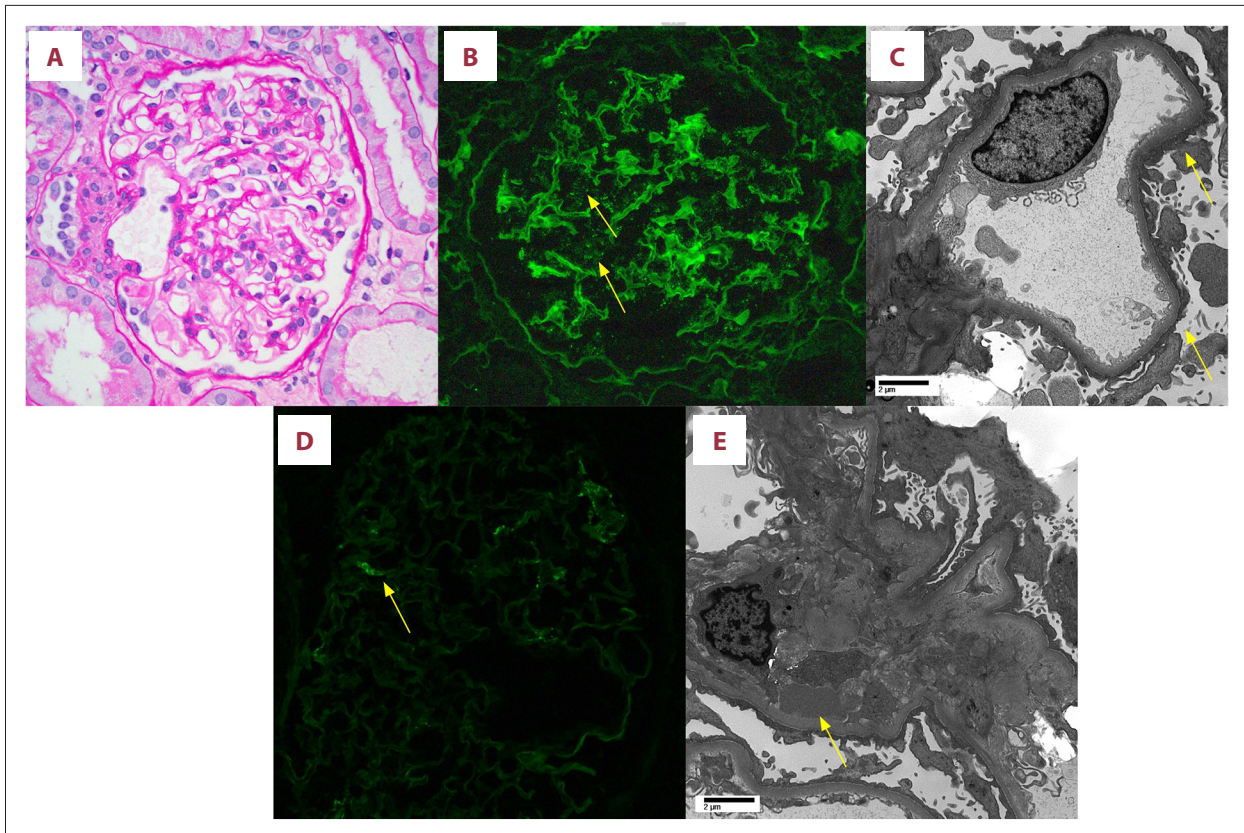


Figure 1. Kidney biopsy findings. (A) Light micrograph demonstrating unremarkable glomerulus (periodic acid Schiff stain; 400 \times). (B) Immunofluorescence stain for anti-human IgG demonstrating fine granular podocyte cytoplasmic “dusting” with IgG (arrows) (400 \times ; contrast enhanced from original image for enhanced visualization of weak deposits). (C) Electron micrograph demonstrating a representative glomerular capillary loop with extensive podocyte foot process effacement (arrows). (D) Immunofluorescence stain for anti-human IgA demonstrating segmental weak granular mesangial IgA deposition (400 \times). (E) Electron micrograph of a mesangial region demonstrating a rare mesangial electron-dense deposit (arrow).

or possibly a very low-grade IgA nephropathy, and provided an anatomic explanation for the hematuria. The presence of a delicate punctate IgG podocyte staining pattern raised the possibility of anti-nephrin antibodies as the mechanism of podocyte injury (commercial serologic testing for confirmation is currently unavailable).

The patient was started on 80 mg oral prednisone, which led to complete remission of disease in 4 weeks, with improvement of leg swelling and resolution of proteinuria. The dosage was tapered from 80 mg (47 days) to 60 mg (30 days), 40 mg (7 days), 30 mg (7 days), 20 mg (10 days), 10 mg (45 days), and 5 mg (60 days), and it was discontinued over the course of 28 weeks.

After 24 weeks of remission, the disease relapsed, with UPC increasing to 1.8 g/g; therefore, he was restarted on 60 mg of prednisone. Remission was achieved in 4 weeks with Alb/Cr <30 mg/g, UPC of 0.2 g/g, and normal kidney function with Cr=0.8 mg/dl in 4 weeks. Prednisone was tapered within 2

months after achieving remission with resolution of proteinuria and complete remission to normal kidney function (**Figure 2**).

Discussion

This case report highlights the potential for COVID-19 vaccination to trigger relapses of minimal change disease (MCD), even after prolonged remission. The findings emphasize the importance of vigilant monitoring of proteinuria after vaccination in MCD patients and the need for further research into the mechanisms and management of vaccine-associated MCD.

An international multicenter study of 98 cases of de novo glomerulonephritis (GN) attributed to COVID-19 vaccines investigated data from 44 centers in 13 countries, showing that most of the patients had received mRNA vaccines, as in the present case, and identified minimal change disease (MCD) and IgA nephropathy (IgAN) as the most common diagnoses, with onset of GN suspected after the second vaccine dose in over

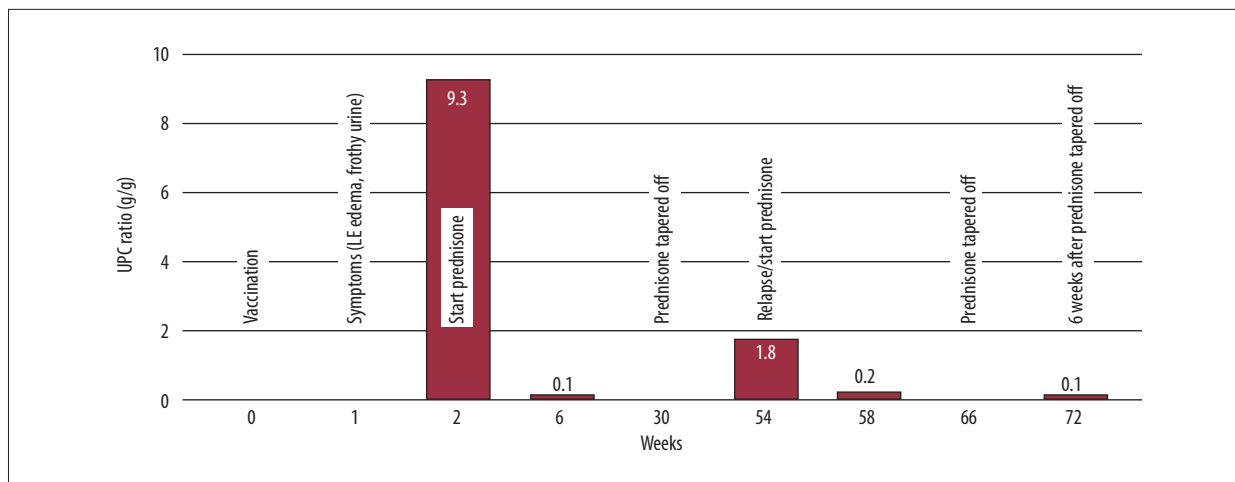


Figure 2. Timeline and clinical course of the patient. UPC – urine protein creatinine.

half of the patients. MCD occurred more frequently after the first dose, while IgAN and other histologies were more commonly associated with the second dose. The most common kidney-related symptoms were edema, hypertension, foamy urine, and macroscopic hematuria, which occurred most frequently in IgAN, and few other diagnoses. Clinical presentations included nephrotic syndrome, sub-nephrotic-range proteinuria, microscopic hematuria, and isolated hematuria. The study found that 11% of cases of vaccine-induced GN were self-limiting, with complete or partial remission achieved in 60% of cases overall. Higher rates of remission were observed in MCD and IgAN cases (86% and 61%, respectively), while other subgroups had lower rates of remission [6].

In a retrospective population-level cohort study, the researchers used a centralized clinical and pathology registry to identify 1105 adult patients in British Columbia, Canada, with biopsy-proven glomerular disease that was stable on December 14, 2020. During 281 days of follow-up, 134 patients experienced a relapse, with exposure to a second or third vaccine dose associated with a 2-fold higher risk of relapse, but a first vaccine dose was not associated with relapse risk (HR=0.67) [7].

A recent study investigated whether nephrin autoantibodies were present in patients with minimal change disease and explored the potential autoimmune etiology of the disease. The researchers evaluated sera from 2 independent patient cohorts for circulating nephrin autoantibodies, using various methods, and identified their presence during active disease, which was significantly reduced or absent during treatment response in a subset of patients with minimal change disease. They also correlated the presence of these autoantibodies with podocyte-associated punctate IgG in renal biopsies and identified a patient with steroid-dependent childhood minimal change disease who developed a massive post-transplant recurrence of proteinuria associated with high pretransplant circulating

nephrin autoantibodies. The discovery of nephrin autoantibodies in patients with minimal change disease agrees with published animal studies and provides further support for an autoimmune etiology [8].

The pathogenesis of vaccine-associated minimal change disease has been hypothesized, in which vaccine-induced immune response may trigger the production of cytokines, which leads to podocyte damage [9]. It has also been suggested that the vaccine may act as a trigger for a pre-existing autoimmune process [10]. There was very low-grade segmental mesangial IgA deposition. This may represent a low-grade IgAN, which has also been seen following COVID and Vaccines, or latent IgAN deposits, which are not uncommonly encountered in kidney biopsies, without clinical significance. This likely was not a significant factor in the nephrotic presentation. Our case report's strength lies in its potential to contribute to the evolving understanding of renal disorders occurring after COVID-19 vaccination. By considering antibody-based evidence, evaluating mesangial IgA deposition, and juxtaposing MCD and IgAN within the broader context of vaccine-related nephropathies, this report adds to the discourse on the intricacies of renal responses to vaccination.

Conclusions

This report presents a case of longstanding minimal change disease which shows exacerbation following a third dose of an mRNA vaccine for SARS-CoV-2. Although this may be a rare association, this case supports that patients with glomerulonephritis needed to be monitored after vaccination for COVID-19. Further studies are needed to understand the relationship between COVID-19 vaccination and nephropathies, as well as optimal management strategies for these rare but potentially serious adverse events in relapsing cases.

Declaration of Figures' Authenticity

All figures submitted have been created by the authors who confirm that the images are original with no duplication and have not been previously published in whole or in part.

References:

1. Polack FP, Thomas SJ, Kitchin N. C4591001 Clinical Trial Group. Safety and efficacy of the BNT162b2 mRNA COVID-19 vaccine. *N Engl J Med.* 2020;383(27):2603-15
2. Luo H, Li X, Ren Q, et al. Acute kidney injury after COVID-19 vaccines: A real-world study. *Ren Fail.* 2022;44(1):958-65
3. Zamora G, Pearson-Shaver AL. Minimal change disease. In: *StatPearls.* Treasure Island (FL): StatPearls Publishing; July 10, 2023
4. Hummel A, Oniszczuk J, Kervella D, et al. Idiopathic nephrotic syndrome relapse following COVID-19 vaccination: A series of 25 cases. *Clin Kidney J.* 2022;15(8):1574-82
5. Teragaki M, Tanaka M, Yamamoto H, et al. Relapse of minimal change disease following the third mRNA COVID-19 vaccination: A case report and literature review. *CEN Case Rep.* 2023 [Online ahead of print]
6. Waldman M, Sinaii N, Lerma EV, et al. COVID-19 vaccination and new onset glomerular disease: Results from the IRocGN2 international registry. *Kidney360.* 2023;4(3):349-62
7. Canney M. A population-based analysis of the risk of glomerular disease relapse after COVID19 vaccination. *J Am Soc Nephrol.* 2022;33:2247-57
8. Watts AJB, Keller KH, Lerner G, et al. Discovery of autoantibodies targeting nephrin in minimal change disease supports a novel autoimmune etiology. *J Am Soc Nephrol.* 2022;33(1):238-52
9. Lebedev L, Sapojnikov M, Wechsler A, et al. Minimal change disease following the Pfizer-BioNTech COVID-19 vaccine. *Am J Kidney Dis.* 2021;78(1):142-45
10. Hartley JL, Bailey N, Sharma A, Shawki H. Nephrotic syndrome with minimal change disease after the Pfizer-BioNTech COVID-19 vaccine: Two cases. *BMJ Case Rep.* 2022;15(3):e244638