

UC Davis

Dermatology Online Journal

Title

Elejalde syndrome (ES)

Permalink

<https://escholarship.org/uc/item/96833983>

Journal

Dermatology Online Journal, 21(3)

Authors

Mohammadzadeh Shanehsaz, Siavash
Rezazadeh, Azadeh
Dandashli, Anwar

Publication Date

2015

DOI

10.5070/D3213023521

Copyright Information

Copyright 2015 by the author(s). This work is made available under the terms of a Creative Commons Attribution-NonCommercial-NoDerivatives License, available at <https://creativecommons.org/licenses/by-nc-nd/4.0/>

Peer reviewed

Case presentation

Elejalde syndrome (ES)

Siavash M. Shanehsaz¹, Azadeh Rezazadeh¹, Anwar Dandashli²

Dermatology Online Journal 21 (3): 13

¹Dermatology and Leishmaniasis Research Center , Kerman University of Medical Sciences, Kerman, Iran

²Department of Dermatology and Venereology, Aleppo University Hospital, Aleppo, Syria

Correspondence:

Dr. Siavash M. Shanehsaz
Email: mdsiavash@yahoo.com

Abstract

Silvery hair and severe dysfunction of the central nervous system (Neuroectodermal melanolysosomal disease or Elejalde Syndrome) characterize this rare autosomal recessive syndrome. The main clinical features include silver-lead hair, bronze skin after sun exposure, and neurologic involvement. Large granules of melanin unevenly distributed in the hair shaft are observed. Abnormal melanocytes and melanosomes and abnormal inclusion bodies in fibroblasts may be present. We report a 10-year-old girl with silver-lead (silvery) hair, bronze skin color on sun-exposed areas, generalized hypopigmentation of covered body parts, and congenital seizures. The child was the elder of two children born of a consanguineous marriage. The younger sibling, a female neonate, had the same clinical presentation.

Keywords: Elejalde Syndrome, Silvery hair, bronze skin color, Aleppo, Syria.

Introduction

Silvery hair and central nervous system dysfunction characterize Elejalde Syndrome (ES), a rare autosomal recessive syndrome. Elejalde Syndrome's main features include silver-lead (silvery) hair, intense tanning after sun exposure (bronze skin color on sun-exposed areas), severe neurological impairment either congenital or developing during childhood (seizures, severe hypotonia, mental retardation), and a wide spectrum of ophthalmologic abnormalities. Elejalde Syndrome does not involve impairment of the immune system. It appears related to or allelic to GS1, and thus associated with mutations in MYOVA. However, its gene mutation has yet to be defined [1]. Neurological manifestations are the predominant clinical features in these patients; these symptoms usually appear early, at birth or during childhood. Seizures, severe hypotonia, and mental retardation are the usual clinical findings [2]. In advanced disease, flaccid or spastic hemiplegia, quadriplegia, and ataxia have been reported. Other conditions in the differential diagnosis include Chédiak-Higashi syndrome and Griscelli syndrome. We report this case because of the rarity of this autosomal recessive syndrome.

Case synopsis

A 10-year-old girl presented with silver-lead (silvery) hair, bronze skin color on sun-exposed areas, generalized hypopigmentation of covered body parts, and congenital seizures. At birth, the silvery gray to golden hair and congenital seizures had been present and she developed the hyperpigmentation gradually over the years. The child was the elder of two children born of a consanguineous marriage. The younger sibling, a female neonate, had the same clinical presentation. Physical exam revealed silvery gray to golden hued hair over the scalp, eyebrows, and eyelashes (Figure 1,2,3). A silvery sheen was also present over most of the body hair. There was brownish-black pigmentation of the skin over the sun-exposed sites, especially on the face, neck,

and extensor aspects of the upper and lower limbs. The skin in the covered areas of the body was comparatively light colored. Ophthalmological examination revealed a visual acuity of 7/10 (both eyes). Examination of the fundus revealed mild vascular sheathing with features of papilledema. EEG was done and was abnormal. The magnetic resonance imaging of the brain revealed abnormalities. Immunologic studies included serum IgG, IgA, and IgM., Phagocytic function was tested with nitroblue tetrazolium and was within normal limits. Routine laboratory tests were within normal limits. Serological screening for connective tissue disease was negative. HIV and HBsAg serology were negative. Skin biopsy specimens observed by light microscopy showed irregular distribution and irregular size of melanin granules in the basal layer (Figure 4). Microscopic analysis of her hair showed melanin clumps irregularly distributed along the hair shafts. Chédiak-Higashi syndrome and Griscelli syndrome were excluded in the analysis of our patient for the following reasons: there was no clinical or laboratory evidence of immunologic impairment and abnormal giant intracytoplasmic granules in neutrophils could not be found in the peripheral blood smear (Table 1).

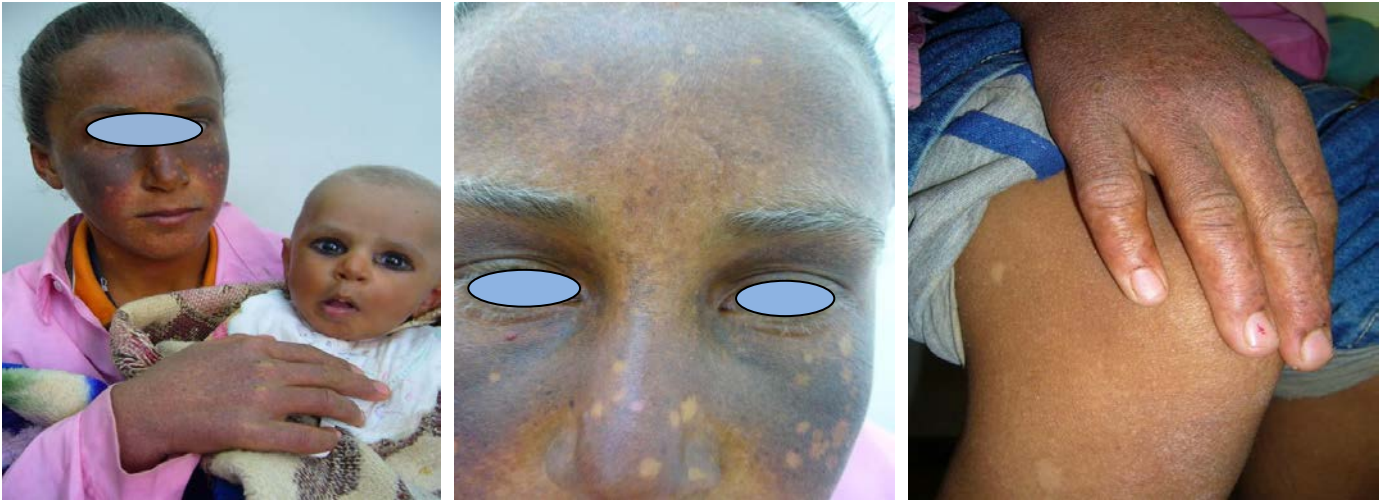

Figure 1,2,3. Silvery gray to golden hue of hair over the scalp, eyebrows, and eyelashes. Silvery sheen over most of the body hair. Brownish-black pigmentation of the skin over the sun-exposed sites, especially on the face, neck and extensor aspects of the upper and lower limbs. Generalized hypopigmentation of covered body parts. The younger sibling had same clinical presentation.

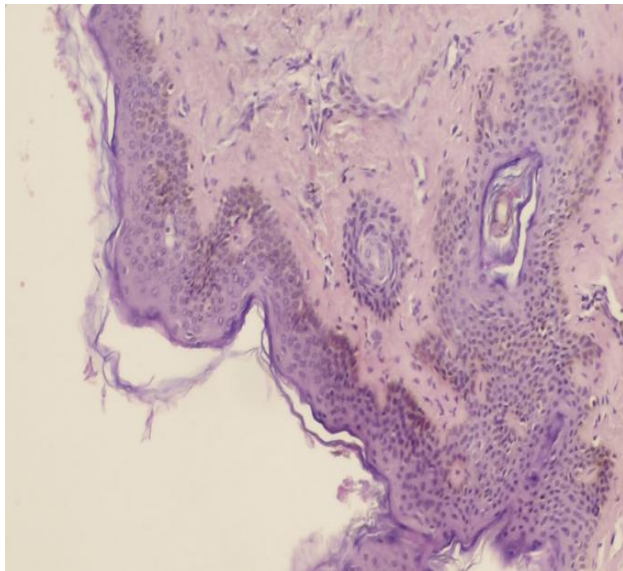


Figure 4. Skin biopsy specimens observed by light microscopical examination showed irregular distribution and irregular size of melanin granules in the basal layer.

Discussion

Silvery hair and severe dysfunction of the central nervous system (Neuroectodermal melanolyosomal disease or Elejalde Syndrome) characterize this rare autosomal recessive syndrome. The main clinical features include silver-lead hair, bronze skin after sun exposure, severe neurological impairment, and a wide spectrum of ophthalmologic abnormalities [3]. Elejalde Syndrome does not involve impairment of the immune system. It appears related to or allelic to GS1, and thus associated with mutations in MYOVA., However, the gene mutation responsible has yet to be defined [1]. Neurological manifestations are the predominant clinical features in these patients and they, usually appear early, at birth or

during childhood. Seizures, severe hypotonia, and mental retardation are the usual clinical findings. In advanced disease, flaccid or spastic hemiplegia, quadriplegia, and ataxia have been reported. Ophthalmologic abnormalities include nystagmus, diplopia, amaurosis, and absence of pupillary reflex [2]. Pigmentary abnormalities are the second most common clinical feature, which include silvery hair, a gradual bronze-colored tan of the sun-exposed areas, and generalized hypopigmentation of covered body parts. Early death owing to neurological involvement is the rule and the oldest patient reported with (ES) was 12 years old [4]. There is some degree of clinical and genetic overlap between Griscelli Syndrome (GS), Chédiak-Higashi syndrome, and (ES). All three disorders manifest during childhood and central nervous system involvement is common. Inheritance pattern is autosomal recessive for these disorders. Genetically, there is a similarity between (GS) and (ES) and some authors have considered (ES) as an allelic variant of (GS). Impaired melanosome transport, giving rise to failure of transfer of melanin to keratinocytes, results in the pigmentary abnormalities in patients with silvery hair syndromes., The affected genes are believed to be involved in lysosomal transport of melanosomes [5]. The two closely related genes for (GS) are located on chromosome 15q21. These genes, RAB27A

and MYO5A, function in vesicle trafficking at the cellular level. Mutations in RAB27A result in hemophagocytic abnormalities and thereby result in (GS) type 2, manifested as silvery hair with immunological defects [6]. Mutations in MYO5A (an actin-based motor molecule, required for pigmentation and synaptic activity in the central nervous system) result in pigmentary dilution along with neurological abnormalities, designated as (GS) type 1 [7,8,9]. Prognosis for long-term survival of patients with GS is relatively poor, and GS2 is usually rapidly fatal within 1–4 years without treatment [10,11]. Therapeutic measures for Elejalde syndrome patients have included the use of steroids, anticonvulsants, and antipyretics, and they have been unsuccessful in all patients. Thus, whether any medical therapy can be recommended for Elejalde syndrome patients is unclear.

Table1. Differential diagnosis of silvery hair syndromes

Silvery hair syndromes	Elejalde syndrome	Chédiak-Higashi syndrome	Griscelli syndrome
Inheritance pattern	AR	AR	AR
Clinical features	Silvery hair, profound dysfunction of the central nervous system	Oculocutaneous hypopigmentation and Silver-gray hue hair, a marked defective chemotaxis of neutrophils and an apparent association with lymphoid malignancy	Silver-gray to golden hue hair in childhood and variable cellular immunodeficiency
immunologic impairment	-	+	+
Histology	Large granules of melanin unevenly distributed in the hair shaft; Abnormal melanosomes and melanocytes and abnormal inclusion bodies in fibroblasts	Presence of characteristic granulocytic giant lysosomes; fine granular pigment distribution in the hair shaft	Presence of large pigment clumps in the hair shaft
Pathogenesis	Is allelic variant of (GS)	Mutation in 1q42-1q43 (LYST)	Mutation in 15q21 (RAB27A and MYO5A)

References

1. Bahadoran P, Ortonne JP, Ballotti R, De Saint-Basile G. Comment on Elejalde syndrome and relationship with Griscelli syndrome. *Am J Med Genet.* 2003;116A:408-9. [PMID: 12522801]
2. Cahali JB, Fernandez SA, Oliveira ZN, Machado MC, Valente NS, Sotto MN. Elejalde syndrome: Report of a case and review of the literature. *Pediatr Dermatol* 2004;21:479-82. [PMID: 15283796]
3. Carola Durán-McKinster, MD; Rodolfo Rodriguez-Jurado, MD; Cecilia Ridaura, MD; M. A. de la Luz Orozco-Covarrubias, MD; Lourdes Tamayo, MD; Ramon Ruiz-Maldonado, MD(1999) Elejalde Syndrome—A Melanolyosomal Neurocutaneous Syndrome Clinical and Morphological. *Arch Dermatol.* 135(2):182-186.
4. Ivanovich J, Mallory S, Storer T, Ciske D, Hing A. 12-year-old male with Elejalde syndrome (neuroectodermal melanolyosomal disease). *Am J Med Genet* 2001;98:313-6. [PMID:11170073]
5. Lambert J, Vancoillie G, Naeyaert JM. Elejalde syndrome revisited. *Arch Dermatol* 2000;136:120-1. [PMID:10632217]
6. Anikster Y, Huizing M, Anderson PD, Fitzpatrick DL, Klar A, Gross-Kieselstein E, et al . Evidence that Griscelli syndrome with neurological involvement is caused by mutation in RAB27A, not MYO5A. *Am J Hum Genet* 2002;71:407-14. [PMID:12058346]
7. Libby RT, Lillo C, Kitamoto J, Williams DS, Steel KP. Myosin Va is required for normal photoreceptor synaptic activity. *J Cell Sci* 2004;117:4509-15. [PMID:15316067]
8. Menasche G, Fischer A, de Saint Basile G. Griscelli syndrome types 1 and 2. *Am J Hum Genet* 2002;71:1237-8. [PMID:12452176]
9. Kraft P, Wilson M. Family-based association tests incorporating parental genotypes. *Am J Hum Genet* 2002;71:1238-9. [PMID:12452177]
10. Klein C, Phillippe N, Francoise LD, et al: Partial albinism with immunodeficiency (Griscelli syndrome), *J Paediatr*, 125: 886–895, 1994. [PMID:7996360]
11. de Saint Basile G: Griscelli Syndrome: Orphanet Encyclopedia, March 2001, last update May 2003: Available from: URL: <http://www.orpha.net/data/patho/GB/uk-griscelli.html>, Accessed July 30, 2003.