

UC Davis

Dermatology Online Journal

Title

Sclerosing perineurioma: case report and literature review

Permalink

<https://escholarship.org/uc/item/92s86728>

Journal

Dermatology Online Journal, 20(6)

Authors

Armengot-Carbo, Miquel
Millan, Fernando
Sanjuan, Josefina
[et al.](#)

Publication Date

2014

DOI

10.5070/D3206022854

Copyright Information

Copyright 2014 by the author(s). This work is made available under the terms of a Creative Commons Attribution-NonCommercial-NoDerivatives License, available at <https://creativecommons.org/licenses/by-nc-nd/4.0/>

Peer reviewed

Photo Vignette

Sclerosing perineurioma: case report and literature review

Miquel Armengot-Carbo¹, Fernando Millán¹, Josefina Sanjuan², Esther Quecedo¹, Enrique Gimeno¹

Dermatology Online Journal 20 (6): 15

Department of Dermatology¹ and Department of Pathology. Arnau de Vilanova Hospital². Valencia (Spain)

Correspondence:

Miquel Armengot-Carbó
Department of Dermatology. Arnau de Vilanova Hospital
C/ San Clemente 12. 46015 Valencia (Spain)
miquelarmengot@gmail.com
Telephone: (+34)600807750

Abstract

Perineuriomas are rare tumors derived from perineural cells usually presenting as a single asymptomatic papule or nodule located on an extremity of an adult. A sclerosing subtype has been rarely described. We report a case of painful sclerosing perineurioma in a 42-year-old woman.

Keywords: Nerve Sheath Neoplasms; Perineurioma; Pain; Extran neural perineurioma; Sclerosing perineurioma

Case synopsis

A 42-year-old woman complained about a firm, painful nodule on the dorsum of the right wrist, which had grown slowly for 2 years (Fig. 1). With a clinical suspicion of dermatofibroma, the lesion was surgically excised. Histological examination revealed a scanty cellular, well-delimited dermal nodule (Fig. 2A). This nodule was composed of concentrically arranged collagen bundles, within which were spindle to epithelioid cells distributed in a whorled onion bulb-like pattern (Fig. 2B) that were grouped in clusters in some areas (Fig. 2C). The nuclei were round or ovoid, with fine chromatin and small nucleoli. No mitotic activity was observed. Immunohistochemistry showed the tumor cells to be positive for epithelial membrane antigen (EMA) and claudin-1 (Fig. 2D), and negative for S100 protein. A diagnosis of sclerosing perineurioma was achieved based upon the histology and immunohistochemistry. The patient has had no relapse 5 years after complete excision of the nodule.

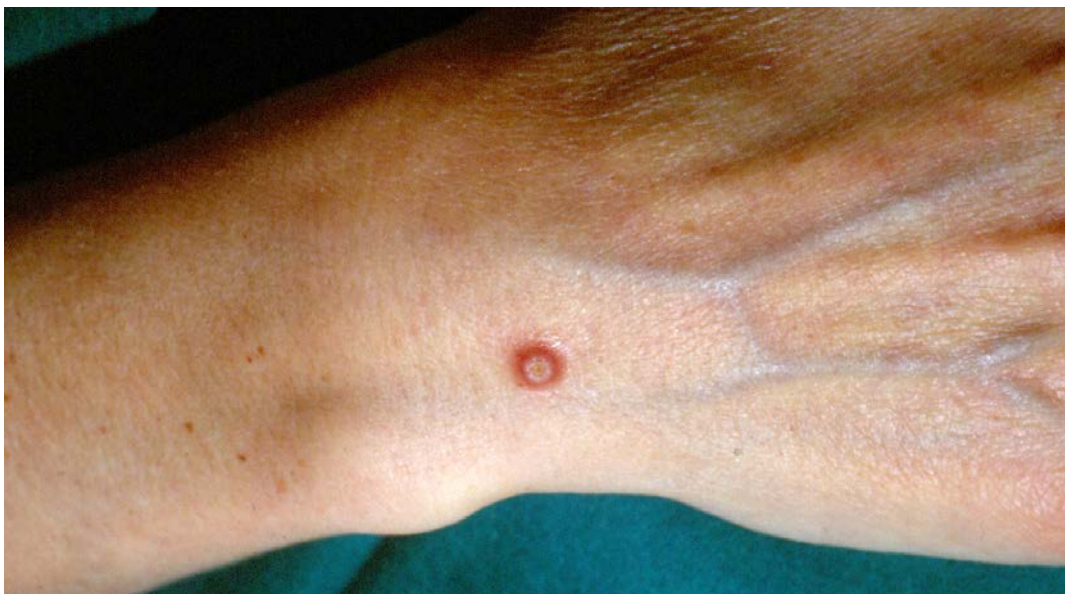

Figure 1. A firm, painful nodule on the dorsum of the right wrist

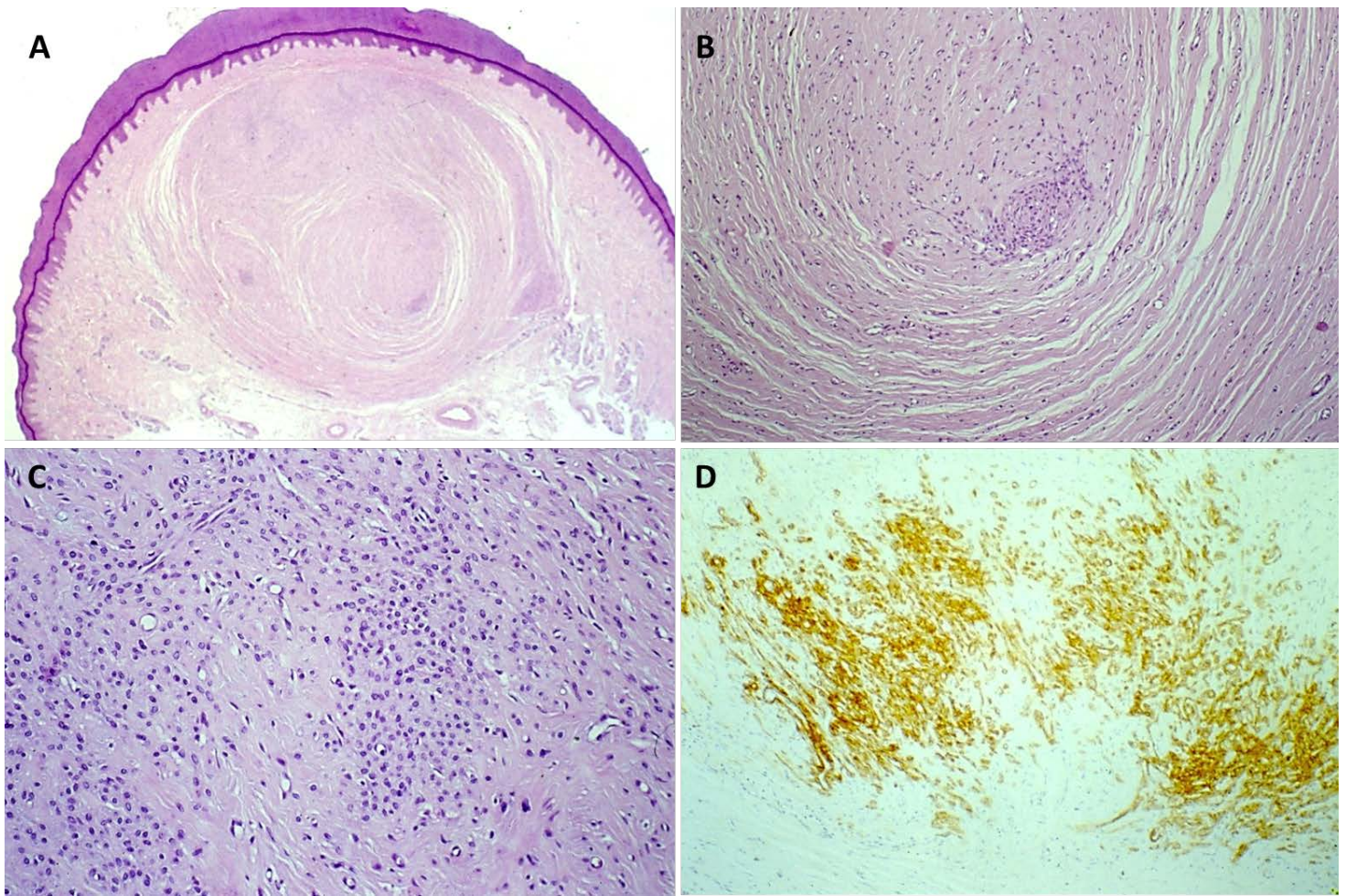


Figure 2. A. A scanty cellular, well-delimited dermal nodule (hematoxylin-eosin, x10) B. An abundant, concentrically arranged collagen stroma with multiple blood vessels and spindle to epithelioid cells distributed in a whorled onion bulb-like pattern (hematoxylin-eosin, x100) C. Cluster of epithelioid cells with a well-defined polygonal cytoplasm (hematoxylin-eosin, x200) D. Claudin-1 positivity (immunohistochemistry, x100)

Discussion

Perineuriomas are uncommon tumors derived from perineural cells. They are usually located on the extremities of young adults [1–3], although there have also been reports in children [4]. Other body locations occasionally reported include the oral cavity [5,6] and scrotal region [7]. Two main variants have been identified: an extremely rare intraneural form and a more common extraneural or soft tissue variant [2,8]. A sclerosing extraneural variant was first described in 1997 [9]; since then less than 50 cases of this presentation have been documented [3,10]. Sclerosing perineurioma characteristically occurs on the hands as a single, asymptomatic papule or nodule of fibrous consistency, which is often confused with dermatofibroma [1–3,9]. Non-acral [5,6,11], multiple, and bilateral presentations have also been described [12,13].

Histologically, sclerosing perineurioma presents as a well-circumscribed, scanty cellular nodule located in the dermis or hypodermis. The lesion exhibits a variable number of small epithelioid and fusiform cells, which are arranged in an onion bulb-like and trabecular growth pattern, within a dense collagen stroma [2,3,9]. Histologically, the lesion must be distinguished from other sclerosing and/or fusocellular tumors. Perineural differentiation is immunohistochemically demonstrated by S100 protein negativity and epithelial membrane antigen (EMA) positivity. It is in contrast to Schwann cells, which are positive for S100 protein and negative for EMA. Because EMA expression in perineuriomas can be diffuse or localized, other perineural differentiation markers such as claudin-1 may be useful. Claudin-1 shows a membranous granular positivity pattern in perineurioma and it proves negative in the mesenchymal cells. Consequently, this marker is useful for the differential diagnosis with dermatofibrosarcoma protuberans, fibromyxoid sarcoma, desmoplastic fibroblastoma, or fibromatosis [14]. Perineurioma is also characteristically positive for vimentin and there have been cases reported with positivity for cytokeratins, CAM 5.2, muscle-specific actin, collagen IV, laminin, GLUT-1, CD99, and CD34 [3,8,9,11,15]. In our patient, sclerosing perineurioma was positive for EMA and claudin-1, and negative for S100 protein. The diagnosis of sclerosing perineurioma must be kept in mind to avoid histological confusion with other lesions such as tendon sheath fibroma, sclerotic fibroma associated with Cowden syndrome, epithelioid neurofibroma, advanced stage giant cell tumor of tendon sheath, and fibrosing adnexal tumors [9].

Surgical excision is the definitive treatment and the tumor does not generally recur after resection, as seen in our case [3].

References

1. Robson AM, Calonje E. Cutaneous perineurioma: a poorly recognized tumour often misdiagnosed as epithelioid histiocytoma. *Histopathology*. 2000 Oct;37(4):332–339. [PMID: 11012740]
2. Rankine AJ, Filion PR, Platten MA, Spagnolo DV. Perineurioma: a clinicopathological study of eight cases. *Pathology (Phila)*. 2004 Aug;36(4):309–315. [PMID: 15370128]
3. García-Arpa M, González-López L, Vera-Iglesias E, Murillo C, Romero G. [Cutaneous sclerosing perineurioma]. *Actas Dermo-Sifiliográficas*. 2009 Aug;100(6):514–516. [PMID: 19709561]
4. Balarezo FS, Muller RC, Weiss RG, Brown T, Knibbs D, Joshi VV. Soft tissue perineuriomas in children: report of three cases and review of the literature [corrected]. *Pediatr Dev Pathol Off J Soc Pediatr Pathol Paediatr Pathol Soc*. 2003 Apr;6(2):137–141. [PMID: 12545405]
5. González-Arriagada WA, Leon JE, Vargas PA, Paes de Almeida O, Lopes MA. Intraoral sclerosing perineurioma: a case report and review of the literature. *Oral Surg Oral Med Oral Pathol Oral Radiol Endod*. 2010 May;109(5):e46–52. [PMID: 20416518]
6. Noonan VL, Greene DJ, Brodsky G, Kabani SP. Extraneural sclerosing perineurioma of the buccal mucosa: a case report and clinicopathologic review. *Head Neck Pathol*. 2010 Jun;4(2):169–173. [PMID: 20364337]
7. Gamblin TC, McKinney WB, Stephens RE Jr, Barron T. Perineuroma of the scrotum. *Urology*. 2002 Sep;60(3):515. [PMID: 12350508]
8. Macarenco RS, Ellinger F, Oliveira AM. Perineurioma: a distinctive and underrecognized peripheral nerve sheath neoplasm. *Arch Pathol Lab Med*. 2007 Apr;131(4):625–636. [PMID: 17425397]
9. Fetsch JF, Miettinen M. Sclerosing perineurioma: a clinicopathologic study of 19 cases of a distinctive soft tissue lesion with a predilection for the fingers and palms of young adults. *Am J Surg Pathol*. 1997 Dec;21(12):1433–1442. [PMID: 9414186]
10. Kim HJ, Yang I, Jung AY, Woo JY, Hong HS, Jeh SK, Kim HK, Kim JW. Ultrasound and MR findings in sclerosing perineurioma. *Skeletal Radiol*. 2011 Mar;40(3):353–355. [PMID: 21038078]
11. Fox MD, Gleason BC, Thomas AB, Victor TA, Cibull TL. Extra-acral cutaneous/soft tissue sclerosing perineurioma: an under-recognized entity in the differential of CD34-positive cutaneous neoplasms. *J Cutan Pathol*. 2010 Oct;37(10):1053–1056. [PMID: 20412342]
12. Huang H-Y, Sung M-T. Sclerosing perineuriomas affecting bilateral hands. *Br J Dermatol*. 2002 Jan;146(1):129–133. [PMID: 11841380]
13. Rubin AI, Yassaee M, Johnson W, Elenitsas R, Zaladonis J Jr, Seykora JT. Multiple cutaneous sclerosing perineuriomas: an extensive presentation with involvement of the bilateral upper extremities. *J Cutan Pathol*. 2009 Oct;36 Suppl 1:60–65. [PMID: 19187114]
14. Folpe AL, Billings SD, McKenney JK, Walsh SV, Nusrat A, Weiss SW. Expression of claudin-1, a recently described tight junction-associated protein, distinguishes soft tissue perineurioma from potential mimics. *Am J Surg Pathol*. 2002 Dec;26(12):1620–1626. [PMID: 12459629]
15. Canales-Ibarra C, Magariños G, Olsoff-Pagovich P, Ortiz-Hidalgo C. Cutaneous sclerosing perineurioma of the digits: an uncommon soft-tissue neoplasm. Report of two cases with immunohistochemical analysis. *J Cutan Pathol*. 2003 Oct;30(9):577–581. [PMID: 14507408]