

UC Davis

Dermatology Online Journal

Title

Unilateral nevoid telangiectasia syndrome (UNTS) associated with chronic Hepatitis C virus and positive immunoreactivity for VEGF

Permalink

<https://escholarship.org/uc/item/8q9268sf>

Journal

Dermatology Online Journal, 20(6)

Authors

Smith, JA
Kamangar, F
Prakash, N
[et al.](#)

Publication Date

2014

DOI

10.5070/D3206022867

Copyright Information

Copyright 2014 by the author(s). This work is made available under the terms of a Creative Commons Attribution-NonCommercial-NoDerivatives License, available at <https://creativecommons.org/licenses/by-nc-nd/4.0/>

Peer reviewed

Case Report

Unilateral nevoid telangiectasia syndrome (UNTS) associated with chronic Hepatitis C virus and positive immunoreactivity for VEGF

Smith JA BA², Kamangar F MD¹, Prakash N MD¹, Fung MA MD^{1,3}, Konia T MD^{1,3} and Fazel N MD DDS¹

Dermatology Online Journal 20 (6): 7

¹University of California Davis, Medical Center, Department of Dermatology, Sacramento, CA

²University of Arizona College of Medicine, Tucson, AZ

³University of California Davis, Medical Center, Department of Pathology and Laboratory Medicine, Sacramento, CA.

Correspondence:

Nasim Fazel, MD, DDS
University of California Davis, Department of Dermatology
3301 C Street, Suit 1300
Sacramento, CA 95816
Phone: 916-734-6111
Nasim.fazel@ucdmc.ucdavis.edu

Abstract

Unilateral Nevoid Telangiectasia Syndrome (UNTS) is characterized by superficial telangiectasias in a unilateral distribution. Vascular endothelial growth factor (VEGF) may play a role in the pathogenesis of UNTS in patients with underlying hepatic disease. We report a case of a patient with UNTS accompanied by chronic hepatitis C virus infection, with a normal serum estrogen profile and strong positive immunohistochemical staining of lesional skin with VEGF.

Introduction

Unilateral Nevoid Telangiectasia Syndrome (UNTS) is a rare disease characterized by superficial telangiectasias in a unilateral distribution, most frequently involving the C3-C4 and trigeminal nerve dermatomes [1-5]. The pathogenesis of UNTS is unknown. The most commonly proposed mechanism suggests an association with pathological and physiological hyperestrogenic states including pregnancy, puberty, and liver disease [1-4]. However, the majority of reported cases in the literature have normal estrogen levels and show no increase in estrogen and progesterone receptors in lesional skin. Most recently, Turan et al suggested that vascular endothelial growth factor (VEGF) may play a role in the pathogenesis of UNTS in patients with underlying hepatic disease [1]. We report a case of a patient with UNTS accompanied by chronic hepatitis C virus infection, with a normal serum estrogen profile and strong positive immunohistochemical staining of lesional skin with VEGF.

Case synopsis

A 54-year-old woman presented to our outpatient clinic for consultation of a painless erythematous lesion involving the left thigh. The lesion had been present for approximately three months and had not changed in size. The patient also reported an asymptomatic similar lesion involving the left chest and left arm present for over thirty years, which had been gradually increasing in size.

Her past medical history was significant for chronic hepatitis C secondary to prior intravenous drug abuse, squamous cell carcinoma of the left lung status-post resection, and a hysterectomy related to benign disease. She had no known history of

radiologic evidence of cirrhosis and her most recent liver biopsy showed chronic hepatitis with no fibrosis (Grade 1, Stage 0). She denied a personal or family history of skin cancer or similar skin findings. The patient denied a history of pruritus, diarrhea, syncope, headaches, or associated pain.

Physical Examination: Physical examination revealed multiple, non-palpable, blanching telangiectasias in a linear distribution along the T1-T2 dermatome involving the left chest, left shoulder, and left arm (Figure 1). In addition, on the left medial thigh there was a 1 cm confluent plaque with multiple 1 mm red papules within a background of surrounding telangiectasias involving the L3 dermatome (Figure 2). No oral lesions or palmar erythema were appreciated.

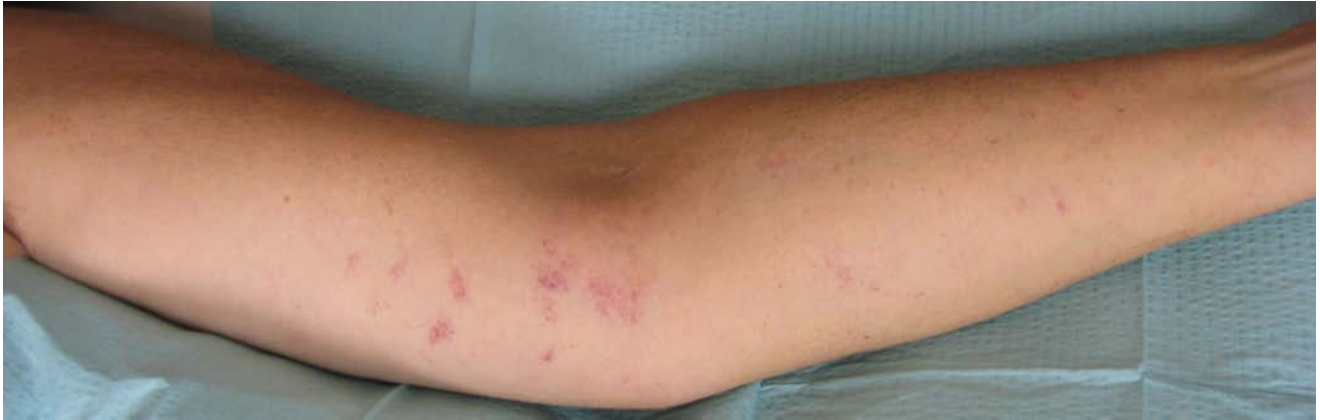

Figure 1. Left arm, multiple telangiectasia in a linear distribution along the T1-T2 dermatome.

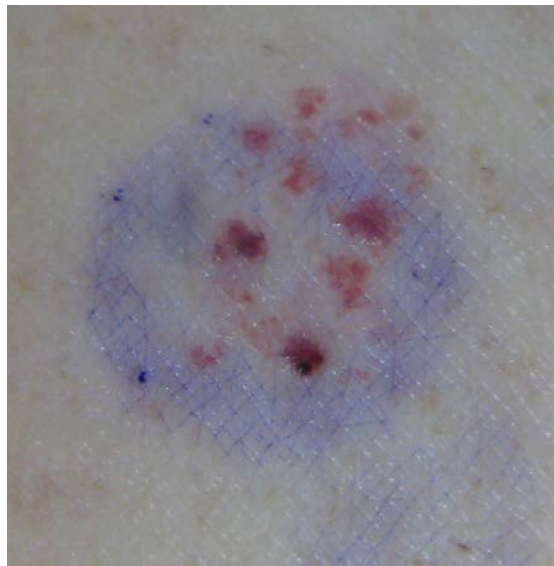


Figure 2. Left medial thigh, 1 cm confluent plaque of telangiectasia.

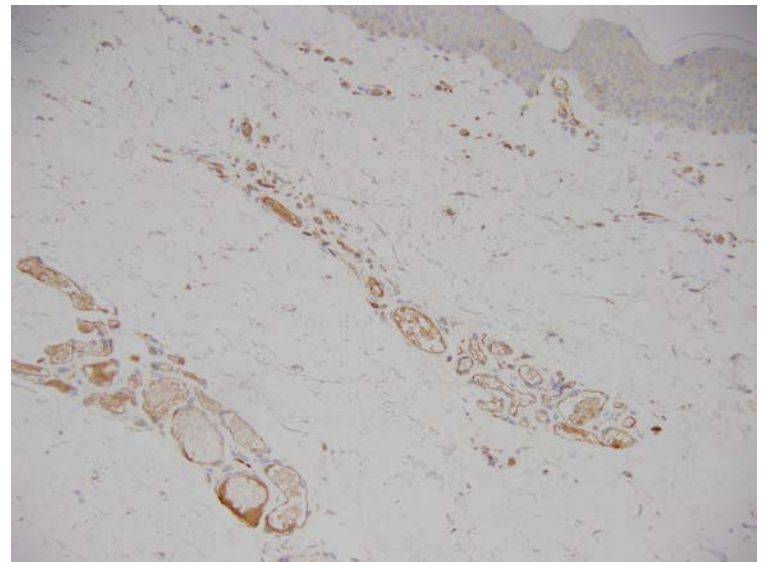
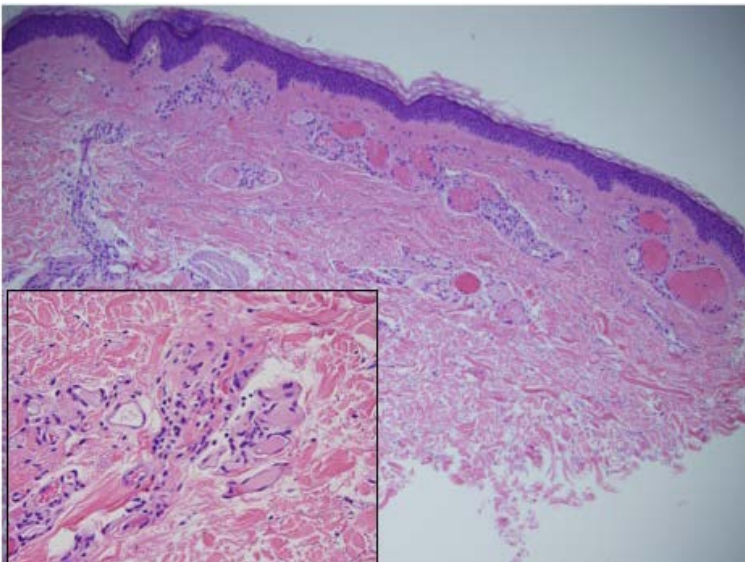


Figure 3. Histopathology, left upper extremity, clusters of dilated, thin walled vessels, some filled with erythrocytes or occluded by fibrin thrombi, within the papillary and reticular dermis.

Figure 4. Immunohistochemical stain, strong positivity for VEGF.

Laboratory Findings: A recent complete blood count and comprehensive metabolic panel were within normal limits (AST:35, ALT: 36). Serum ANCA was negative and ANA was mildly elevated at 1:160 in a centromeric pattern. Additionally, anti-centromere, anti-DNA, anti-SSA, anti-Smith, anti-JO-1, and anti-Scleroderma (SCL-70) antibodies were all negative. Serum hormone levels and VEGF levels were also obtained. Serum hormone levels included: progesterone: <0.02 ng/mL (<0.2-1.4 ng/mL), estradiol: 3.5 pg/mL (Postmenopausal: <10 pg/mL), Estrone: 8.1 pg/mL (Postmenopausal: 7-40 pg/mL), and total estrogens: 11.6 pg/mL (3-32 pg/mL). Serum VEGF levels were normal at 71 pg/mL (9-86 pg/mL).

Histopathologic Findings: Biopsies from the left upper extremity and left medial thigh showed small clusters of dilated, thin-walled vessels, some filled with erythrocytes or occluded by fibrin thrombi, within the papillary and reticular dermis (Figure 3). Immunohistochemical stains were performed for lymphovascular markers including D2-40, Glut-1, vascular endothelial growth factor (VEGF), and estrogen and progesterone (ER/PR) receptors. The blood vessel walls stained negative for D2-40, Glut-1, and both ER/PR receptors. However, strong positive staining for VEGF was noted (Figure 4).

Clinical Course and patient outcome: The patient was informed of the benign nature of this clinical entity and possible treatment options. The patient understood and was satisfied with the diagnosis and declined any treatment. She was advised to return to clinic if the lesions became symptomatic or changed in size and/or appearance.

Discussion

Unilateral nevoid telangiectasia syndrome (UNTS) is a rare vascular dermatosis characterized by multiple, unilateral, linearly arranged, blanching telangiectasias in a dermatomal pattern [1-5, 10-15, 22]. UNTS tends to involve the C3-C4 and trigeminal dermatomes and most commonly affects the face, neck, upper extremities, and thorax [1,6]. However, like in our patient, the lower extremities (lumbar and sacral dermatomes) may also be affected [15]. Out of 100 reported cases of UNTS in the literature, nine have involved at least one lumbar dermatome and there are three cases of sacral dermatomal involvement [15]. UNTS tends to be asymptomatic and does not require treatment [1-3,5 5-10].

Histology of these lesions shows normal appearing epidermis with underlying superficial dermal telangiectatic vessels [1-3, 6-7, 15]. These histological findings are not specific for UNTS and may also be seen in angioma serpiginosum, hemangiomas, and subtle venous malformations [2]. Therefore clinical correlation with the past medical history, patient demographics, and physical exam findings is important to establishing the correct diagnosis.

Immunohistochemistry may also be helpful when differentiating UNTS from other lymphovascular dermatologic conditions. For example, we used D2-40 and GLUT-1 in our panel of immunohistochemistry stains. D2-40 identifies lymphatic endothelium and is used to differentiate lymphatic lesions from other vascular lesions. Positive staining for D2-40 would suggest a lymphatic etiology rather than vascular. GLUT-1 is a human erythrocyte glucose transporter and is associated with cutaneous infantile hemangiomas and other vascular malformations [29-30].

UNTS can either be congenital (15% of reported cases) or in most cases acquired [1-5, 9-11,15]. The congenital subtype of UNTS is more commonly seen in males and is thought to be secondary to elevated maternal hormones in utero [2,9]. The majority of acquired cases are described in conditions associated with high estrogen levels including pregnancy, puberty, and oral contraceptive use [3]. The acquired form has a predilection for females with a 2:1 female to male ratio [2]. UNTS has also been reported with hyperthyroidism [20], portal hypertension, carcinoid syndrome [17], hepatitis, cirrhosis, and other chronic liver diseases [2-3, 10,17, 20, 23].

Tanglersampan et al proposed a new classification system to replace Wilkin et al's classification developed in 1983 [27]; the new classification system divides UNTS into congenital and acquired subtypes [6]. The acquired cases are further subdivided into two classes: systemic association and no association. The systemic associations include estrogen, liver, and skin related diseases [6] (Table 1).

Table 1. Tanglersampan et al's new classification system.

Wilkin et al's system of classification of UNTS, 1983	Tanglersampan et al's system of classification of UNTS, 2013
---	--

I: Congenital II: Acquired <ol style="list-style-type: none"> (a) Physiologic estrogen increase-related <ol style="list-style-type: none"> 1. Puberty in women 2. Adrenarche in men 3. Pregnancy 4. Childhood in women (b) Alcoholism/hepatic-related <ol style="list-style-type: none"> 1. Without systemic involvement 2. With systemic involvement 	I: Congenital II: Acquired <ol style="list-style-type: none"> (a) With association <ol style="list-style-type: none"> 1. Estrogen-related: Pregnancy, puberty in women, adrenarche in men, childhood in women 2. Liver-related: cirrhosis, alcoholism, liver metastasis from carcinoid tumor¹⁷, hepatitis C infection, hepatitis B infection 3. Skin-related: Pyogenic granuloma, polymorphous light eruptions⁶ 4. Others: Hyperthyroidism²⁰, chemotherapy related²³ (b) Without association
--	--

The pathophysiology and etiology of UNTS is unknown. Most attention has centered upon the theory that elevated serum estrogen levels result in target end organ stimulation and telangiectasia formation by unmasking a chromosomal mosaicism resulting in a localized increase of estrogen receptors in a dermatomal distribution [3-4]. Both Uhlin et al and Tanglertsampan et al found an increased level of estrogen receptors in the affected skin of patients with UNTS. However, the vast majority of cases reported have been estrogen receptor negative [3, 6-7] (Table 2).

Table 2. Reported Cases of UNTS with ER/PR Receptor and Serum Estrogen Evaluation.

Case	Condition	ER Receptor	PR Receptor	Serum ER Level	VEGF Receptor	Serum VEGF Levels
Vestey-1 ¹⁶	Pregnancy	Negative	N/A	Increased	N/A	N/A
Vestey-2 ¹⁶	Puberty	Trace	N/A	Normal	N/A	N/A
Beachman ¹⁷	Carcinoid tumor	Negative	Positive	N/A	N/A	N/A
Uhlin ⁷	OCP*	Positive	Positive	Normal	N/A	N/A
Tok ¹⁰	Pregnancy	Negative	Negative	N/A	N/A	N/A
Hynes-1 ⁴	HCV*	Negative	Negative	Normal	N/A	N/A
Hynes-2 ⁴	HCV*	Negative	Negative	Normal	N/A	N/A
Taskapan ¹⁸	None	Negative	Negative	Normal	N/A	N/A
Ramirez-Andreo ¹⁹	None	Negative	Negative	N/A	N/A	N/A
Karakas ¹²	Puberty	Negative	Negative	Normal	N/A	N/A
Kavak ²⁰	Hyperthyroid	Negative	Negative	Normal	N/A	N/A
Grimaldi ²¹	Puberty	Negative	Negative	Normal	N/A	N/A
Karabudak ²²	Puberty	Negative	Negative	Normal	N/A	N/A
Rodriguez-Martin ²³	Chemotherapy	Negative	Negative	Normal	N/A	N/A
Asfar ²⁴	Congenital	Negative	Negative	N/A	N/A	N/A
Senel ²⁵	Congenital	Negative	Negative	Normal	N/A	N/A
Kawakami ²⁶	Puberty	Negative	Negative	Normal	N/A	N/A
Wesen ²	None	Negative	Negative	N/A	N/A	N/A
Tanglertsampan ⁶	Hyperthyroid; possible liver disease	Positive (16%)	Positive (2%)	Normal	N/A	N/A
Turan ¹	HBV*	Negative	Negative	N/A	N/A	N/A
Current Case	HCV*	Negative	Negative	Normal	Positive	Normal

*HCV: Hepatitis C Virus

*HBV: Hepatitis B Virus

*OCP: Oral contraceptive pills

The method used by Uhlin and McCarty to determine receptor levels in their case did not involve the typical immunoperoxidase methods [2,3]. Instead, they used a complex and unique radioactive labeling method that is different from the standard ER/PR testing by immunohistochemistry used today. Although, Tanglertsampan did use standard immunohistochemistry for quantitative

receptor evaluation, the case showed only minimal positivity with 2% progesterone receptor staining and 16% staining for estrogen receptors in the lesional skin [6]. Interestingly, the serum estrogen level in these cases was normal and the only reported cases of increased serum and urine estrogen levels were in pregnant females [2].

Only a few cases of UNTS have been reported in association with hepatitis B and C infections [1,4, 11,12]. In our patient, the diagnosis of UNTS was made based on the clinical history of chronic hepatitis C along with the physical exam findings of unilateral telangiectasias in a dermatomal (T1-T2) distribution. In the other reported cases of UNTS with hepatitis infection, both serum estrogen levels and tissue estrogen/progesterone receptor levels were normal [1,4,11,12]. This is consistent with our patient's findings of normal serum progesterone and estrogen levels as well as negative immunoreactivity for estrogen and progesterone receptors.

Other theories for the cause of UNTS implicate neural alterations, hemodynamic disturbances, aberrations in perivascular supportive connective tissue, and angiogenic factors [2-3,8]. Recently, angiogenic factors have been proposed to play a major role in the pathogenesis of UNTS associated with underlying liver disease [1]. Akiyoshi et al showed elevated serum levels of vascular endothelial growth factor (VEGF) in patients with acute hepatitis [13]. Elevated VEGF results from hepatocellular damage and leakage of VEGF into the circulation [13]. Makhlof et al also reported an increase in VEGF levels in patients with chronic hepatitis C infection and cirrhosis [14]. To our knowledge, lesional immunopositivity for VEGF has not been reported.

Turan et al propose that there is a somatic mosaicism in hepatitis associated UNTS but that the telangiectasias may result from elevated serum levels of angiogenic factors like VEGF [1]. They were unable to obtain serum levels of VEGF and tissue immunoreactivity to support this hypothesis. Our patient's skin biopsy had strong immunopositivity for VEGF. However, the serum VEGF level was within normal range [71, 9-36 pg/mL]. Although the serum VEGF level was within normal limits, we do believe that the presence of strong positive immunohistochemical staining for VEGF on histopathology in our patient supports the theory of the role of angiogenic factors in the pathogenesis of UNTS.

Conclusion

Unilateral Nevoid Telangiectasia Syndrome is a rare vascular lesion that presents in a unilateral linear pattern. It tends to be asymptomatic and does not require treatment. UNTS can be either congenital or acquired and is often associated with physiologic hyperestrogenic states like pregnancy and other health conditions including liver disease. The pathogenesis of UNTS is still unknown but may be related to elevated circulating vascular endothelial growth factor (VEGF) secondary to liver injury. Further studies are needed to assess the role of angiogenic factors in the pathogenesis of UNTS.

*AST: Aspartate Aminotransferase, ALT: Alanine Aminotransferase, ANCA: Anti-neutrophil cytoplasmic antibody, ANA: Anti-nuclear antibody

References:

1. Turan H, Gonen I, Albayrak H, and Aliagaoglu C. Acquired unilateral nevoid telangiectasia syndrome accompanied by chronic hepatitis B virus infection. *Acta Dermatovenerol Croat.* 2013; 21(2):135-136. [PMID: 24001424].
2. Wenson S, Jan F, and Sepehr A. Unilateral nevoid telangiectasia syndrome: a case report and literature review. *Dermatology Online Journal.* 2011; 17 (5):2. [PMID:21635824].
3. Dadlani C, Hideko K, Walters R, Rosenman K, and Pomeranz MK.. Unilateral nevoid telangiectasia. *Dermatology Online Journal.* 2008;14(10):1-4. [PMID:19061602].
4. Hynes L and Shenefelt P. Unilateral Nevoid Telangiectasia: Occurrence in two patients with hepatitis C. *J Am Acad Dermatol.* 1997; 36:819-22. [PMID: 9146557].
5. Kreft B, Marsch WC, and Wohlrab J. Unilateral nevoid telangiectasia syndrome. *Dermatology.* 2004;209:215. [PMID: 15459535].
6. Tanglertsampan C, Chanthothai J, and Phichaqong T. Unilateral nevoid telangiectasia: case report and new classification syndrome. *Int J Dermatol.* 2013;52: 608-610. [PMID: 23590376].
7. Uhlin SR, McCarty KS Jr. Unilateral nevoid telangiectatic syndrome. The role of estrogen and progesterone receptors. *Arch Dermatol.* 1983; 119:226-228. [PMID: 6824361].
8. Arias M, Gonzalez R, Retamar R, Carolina M, Lopez S, Demarchi M, Maria C, and Choulela E. Unilateral nevoid telangiectasia. Report of four cases. *Dermatol Argent.* 2009;15(1):44-48.
9. Jorao JM, Haendchen LC, Berestinas TC, and Faucz LR. Acquired unilateral nevoid telangiectasia in a healthy man. *An Bras Dermatol.* 2010; 85:912-914. [PMID:21308321].
10. Tok J, Berberian BJ, Sulcia V. Unilateral nevoid telangiectasia syndrome. *Cutis.* 1994;53:53-54. [PMID: 8119080].
11. Almazan-Fernandez FM, Guiote MV, Burkhardt P, and Naranjo R. Unilateral nevoid telangiectasias in a Patient with chronic ehpatitis B virus infection. *Actas Dermosifilogr.* 2009;100:82-83. [PMID: 19268121].

12. Karakas M, Durdu M, Sonmezoglu S, Akman A, and Gumurdulu D. Unilateral nevoid telangiectasia. *J Dermatol.* 2004; 31:109-112. [PMID:15160864].
13. Akiyoshi F, Sata M, Suzki H, Uchimura Y, Mitsuyama K, Matsuo K, and Tanikawa K. Serum vascular endothelial growth factor levels in various liver diseases. *Dig Dis Sci.* 1998; 43: 41-45. [PMID: 9508533].
14. Makhlof MM, Awad A, Zakhari MM, Fouad M, and Saleh WA. Vascular endothelial growth factor level in chronic liver diseases. *J Egypt Soc Parasitol.* 2002; 32:907-921. [PMID: 12512823].
15. Guedes R and Leite L. Unilateral nevoid telangiectasia: A rare disease? *Indian J Dermatol.* 2012; 57 (2): 138-140. [PMID: 22615515].
16. Vesty JP, Buxton PK, and Hawkins RA. Unilateral naevoid telangiectatic syndrome-A study of two cases. *Clin Exp Dermatol.* 1985; 10:288-91. [PMID: 4006295].
17. Beachman BE, Kurgansky D. Unilateral naevoid telangiectasia syndrome associated with carcinoid tumor. *Br J Dermatol.* 1991; 124: 86-88. [PMID: 1993149].
18. Taskapan O, Harmanyeri Y, Sener O, and Asku A. Acquired unilateral nevoid telangiectasia syndrome. *Acta Derm Venereol.* 1997; 77: 62-63. [PMID: 9059682].
19. Franco G, Gonzalez M, Altamirano A, Aranda S, Zaragoza I, and Alvarez E. Telangiectasia nevoid unilateral. *Actas Dermosifiliogr.* 2003; 94:258-259.
20. Kavak A, Kutluay L. Unilateral nevoid telangiectasia and hyperthyroidism: A new association or coincidence? *J Dermatol.* 2004; 31:411-414. [PMID: 15187310].
21. Grimalid M, Pranteda G, Talerico C, Pranteda G, and Di Napoli A. Acquired unilateral naevoid telangiectasia in a healthy boy. *Acta Derm Venereol.* 2006; 86:469-470. [PMID: 17048359].
22. Karabudak O, Dogan B, Taskapan O, Harmanyeri Y. Acquired unilateral nevoid telangiectasia syndrome. *J Dermatol.* 2006; 33: 825-826. [PMID:17074005].
23. Rodriguez- Martin M, Saez M, Carnerero A, Garcia-Bustinduy M, Guimera F, Garcia FR, Cabrera de Paz R, Sidro M, Sanchez R, Herrera AM, and Noda A. Unilateral naevoid telangiectasia in a young man after chemotherapy: a simple coincidence or a new clinical association? *J Eur Acad Dermatol Venereol.* 2006;20:1001-1002. [PMID: 16922953].
24. Asfar FS, Ortac R, Diniz G. Unilateral nevoid telangiectasia with no estrogen and progesterone receptors in a pediatric patient. *Indian J Dermatol Venereol Leprol.* 2008; 74:163-164. [PMID:18388386].
25. Senel E, Gulec AT. Congenital unilateral naevoid telangiectasia with a wide dermatomal distribution. *Clin Exp Dermatol.* 2008; 33:633-634. [PMID:18477002].
26. Kawakami T, Kimura S, Soma Y. Unilateral nevoid telangiectasia on the lower extremity of a pediatric patient. *J Am Acad Dermatol.* 2010; 62: 528-530. [PMID: 20159330].
27. Wilkin JK. Unilateral dermatomal superficial telangiectasia. *Dermatologica.* 1978; 157:33-41. [PMID: 668969].
28. Paul LJ and Cohen PR. What is this vascular lesion? Unilateral nevoid telangiectasia. *Dermatologist.* 2011;19 (12):47-50. [PMID:N/A].
29. North PE, Waner M, Mizeracki A, Mrak RE, Nicholas R, Kincannon J, Suen JY, Mihm MC Jr. A unique microvascular phenotype shared by juvenile hemangiomas and human placenta. *Arch Dermatol.* 2001;137 (5):559-70. [PMID: 11346333].
30. North PE, Waner M, Mizeracki A, Mihm MC Jr. GLUT-1: a newly discovered immunohistochemical marker for juvenile hemangiomas. *Hum Pathol.* 2000;31(1):11-22. [PMID: 10665907].