

UC Davis

Dermatology Online Journal

Title

Trichoscopic features of tinea capitis in a straight-haired Hispanic woman

Permalink

<https://escholarship.org/uc/item/8cw0s639>

Journal

Dermatology Online Journal, 24(11)

Authors

Nguyen, Jannett
Chapman, Lance W
Smith, Janellen

Publication Date

2018

DOI

10.5070/D32411042011

Copyright Information

Copyright 2018 by the author(s). This work is made available under the terms of a Creative Commons Attribution-NonCommercial-NoDerivatives License, available at <https://creativecommons.org/licenses/by-nc-nd/4.0/>

Peer reviewed

Trichoscopic features of tinea capitis in a straight-haired Hispanic woman

Jannett Nguyen MD, Lance W Chapman MD MBA, Janelen Smith MD

Affiliations: Department of Dermatology, University of California Irvine, Irvine, California, USA

Corresponding Author: Jannett Nguyen, MD, Department of Dermatology, University of California Irvine School of Medicine, 118 Med Surg 1, Irvine, CA 92697-2400, Tel: 949-824-4405, Fax: 949-824-7454, Email: jannettn@uci.edu

Abstract

Comma and corkscrew hairs are trichoscopic markers of tinea capitis. Although comma hairs have been reported in both black and white patients with tinea capitis, corkscrew hairs were previously hypothesized to manifest exclusively in patients with curly or African hair types. However, we report a significant number of comma and corkscrew hairs in a Hispanic female patient with naturally straight hair and *Trichophyton tonsurans* tinea capitis. Thus, dermoscopy is a rapid, noninvasive, and cost-effective tool for evaluating tinea capitis and should be used in combination with culture in all patients regardless of hair texture or race.

Keywords: tinea capitis, trichoscopy, corkscrew hairs, comma hairs

Introduction

Tinea capitis is a superficial fungal infection of the scalp, and although diagnosis typically involves microbial culture, dermoscopy may also have diagnostic utility. Hair shaft abnormalities including comma and corkscrew hairs have been implicated as trichoscopic markers of tinea capitis. Comma hairs have been described in both black and white patients with tinea capitis [1, 2], but corkscrew hairs were initially only reported in patients of black descent [2-4]. A more recent study reported corkscrew hairs in a curly-haired Caucasian man, leading to the hypothesis that corkscrew hairs are exclusive to patients with either black hair type or

curly hair [5]. In contrast to this hypothesis, we found comma and corkscrew hairs in a Hispanic female patient with *Trichophyton tonsurans* tinea capitis and naturally straight hair.

Case Synopsis

A 38-year-old Hispanic woman presented with a pruritic full body rash and patchy alopecia of three years' duration. The patient's medical history was remarkable for chronic hepatitis C, cryoglobulinemia, diabetes mellitus type I, and end stage renal disease on dialysis. On physical examination, she had widespread, somewhat gyrate, erythema. On the nape of the neck and the scalp, she had broad patchy alopecia with yellow scale and excoriated erythematous papules (**Figure 1**).

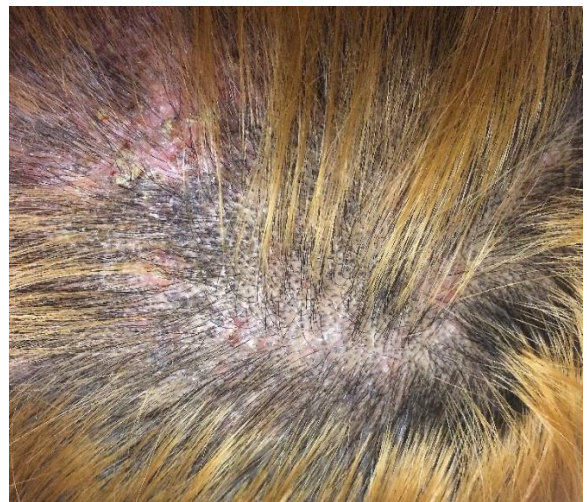

Figure 1. On examination, the patient had broad patchy alopecia with yellow scale and excoriated erythematous papules. A fungal culture isolated *Trichophyton tonsurans*.

Trichoscopy of the parietal scalp revealed widespread hair loss with hair shaft abnormalities including broken, comma, and corkscrew hairs (**Figure 2**). KOH examination of a cutaneous lesion was positive and culture of the scalp revealed heavy growth of *Trichophyton tonsurans*. The widespread tinea corporis was easily controlled with topical antifungals, but the tinea capitis was recalcitrant. Treatment with oral antifungals was initially postponed as she was undergoing successful treatment of hepatitis C. She recently began oral fluconazole and based on renal dosing, takes 200mg after dialysis and 100mg on all other days. Renal and liver function labs are being monitored monthly. Fluconazole has been shown to have similar efficacy as griseofulvin, terbinafine, and itraconazole for treatment of *Trichophyton* tinea capitis [6] and was chosen because it does not have significant interactions with the patient's other medications for her comorbid conditions. At one-month follow-up, the patient's disease is stable and she is tolerating the treatment well without adverse effects.

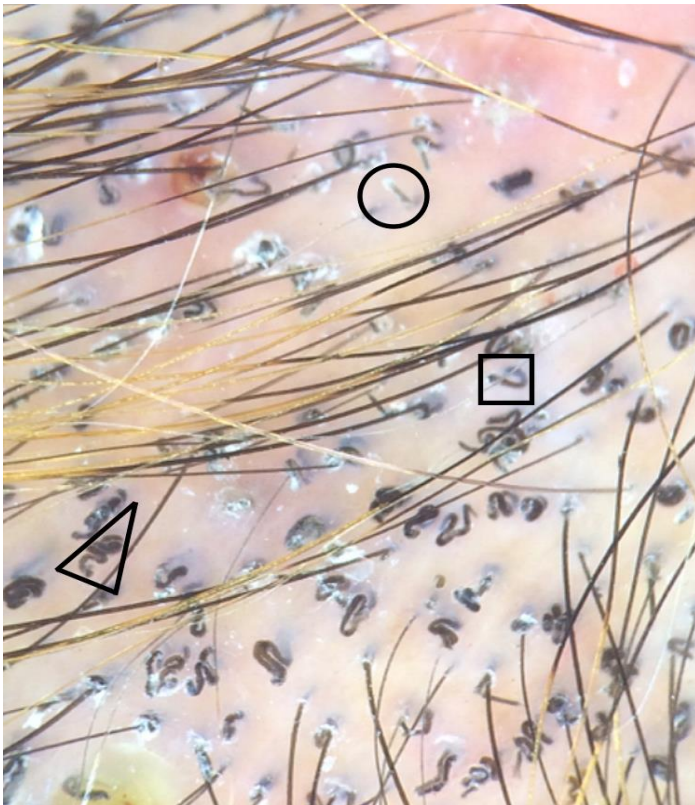


Figure 1. On examination, the patient had broad patchy alopecia with yellow scale and excoriated erythematous papules. A fungal culture isolated *Trichophyton tonsurans*.

Case Discussion

Hair shaft abnormalities including comma and corkscrew hairs have been implicated as specific markers of tinea capitis on dermoscopy. One of the first descriptions of comma hairs associated with tinea capitis was by Slowinska et al. [1], who described this in two Caucasian children with *Microsporum canis* tinea capitis. The authors postulated that infected hair shafts become filled with hyphae, causing hair shafts to bend, break, and manifest as comma-shaped. Comma hairs may reflect an intermediate stage of tinea capitis development that occurs prior to the formation of broken dystrophic hairs [1]. The connection between comma hairs and tinea capitis was confirmed by subsequent reports, including one by Hughes et al., which described comma hairs in six African children with tinea capitis of various etiologies including *T. soudanense*, *T. violaceum*, and *M. langeronii* [2]. Thus, comma hairs can be found in both white and black patients with either endothrix or ectothrix infections [1, 2].

Corkscrew hairs are thought to be variants of comma hairs and were initially reported in tinea capitis patients of black descent [2]. First, Hughes et al. reported four African children with *T. soudanense* dermatophytosis who had both comma and corkscrew hairs, leading the authors to hypothesize that corkscrew hairs may be specific to either black patients or to those infected with *T. soudanense*. However, subsequent reports suggested that *T. soudanense* is not the sole etiologic agent, as corkscrew hairs were also found in African patients with *T. tonsurans* and *T. violaceum* infections [3, 4]. Although initial descriptions of corkscrew hairs only involved black patients, Neri et al. reported corkscrew hairs in a curly-haired Caucasian man with *T. tonsurans* tinea capitis [5]. The authors postulated that corkscrew hairs are non-specific to black patients, but rather manifest in patients with curly hair.

Our present case describes a Hispanic woman with numerous corkscrew hairs in the setting of *T. tonsurans* tinea capitis, supporting the notion of Neri et al. that corkscrew hairs are not exclusive to black patients. However, unlike the patient described by

Neri et al., our patient does not have curly hair, but has naturally straight hair. Thus, we propose that corkscrew hairs may manifest in patients with endothrix tinea capitis regardless of race and hair texture. Our case recapitulates that dermoscopy can be a rapid, noninvasive, and cost-effective tool for evaluating tinea capitis in all patients. Notably, corkscrew hairs may disappear with appropriate systemic antifungal treatment and thus, dermoscopy can also help monitor treatment efficacy [4].

It is also important to consider vitamin C deficiency in patients with corkscrew hairs. Although our patient does have end stage renal disease requiring dialysis, she takes vitamin B complex and vitamin C supplements daily and lacks other mucocutaneous

findings of scurvy, making nutritional deficiency an unlikely etiology.

Conclusion

In summary, we report a case of a straight-haired Hispanic woman with *T. tonsurans* tinea capitis who was found to have numerous comma and corkscrew hairs on trichoscopy. This case counters the prior hypothesis that corkscrew hairs manifest exclusively in tinea capitis patients with African or curly hair types. Thus, a combination of culture and trichoscopy should be used in evaluating a patient with tinea capitis regardless of the patient's race or hair texture.

References

1. Slowinska M, Rudnicka L, Schwartz RA, Kowalska-Oledzka E, Rakowska A, Sicinska J, Lukomska M, Olszewska M, Szymanska E. Comma hairs: a dermatoscopic marker for tinea capitis: a rapid diagnostic method. *J Am Acad Dermatol*. 2008;59(5 Suppl):S77-9. [PMID: 19119131].
2. Hughes R, Chiaverini C, Bahadoran P, Lacour JP. Corkscrew hair: a new dermoscopic sign for diagnosis of tinea capitis in black children. *Arch Dermatol*. 2011;147(3):355-6. [PMID: 21422348].
3. Pinheiro AM, Lobato LA, Varella TC. Dermoscopy findings in tinea capitis: case report and literature review. *An Bras Dermatol*. 2012;87(2):313-4. [PMID: 22570042].
4. Vazquez-Lopez F, Palacios-Garcia L, Argenziano G. Dermoscopic corkscrew hairs dissolve after successful therapy of *Trichophyton violaceum* tinea capitis: a case report. *Australas J Dermatol*. 2012;53(2):118-9. [PMID: 22571559].
5. Neri I, Starace M, Patrizi A, Balestri R. Corkscrew hair: a trichoscopy marker of tinea capitis in an adult white patient. *JAMA Dermatol*. 2013;149(8):990-1. [PMID: 23783798].
6. Gupta AK, Adam P, Dlova N, Lynde CW, Hofstader S, Morar N, Aboobaker J, Summerbell RC. Therapeutic options for the treatment of tinea capitis caused by *Trichophyton* species: griseofulvin versus the new oral antifungal agents, terbinafine, itraconazole, and fluconazole. *Pediatr Dermatol*. 2001;18(5):433-8. [PMID: 11737692].