

# UC Davis

## Dermatology Online Journal

### Title

Complete resolution of erythema elevatum diutinum using oral sulfasalazine

### Permalink

<https://escholarship.org/uc/item/8267v8v9>

### Journal

Dermatology Online Journal, 23(10)

### Authors

Chen, Michael L  
Chlopik, Agata  
Hoang, Maija P  
et al.

### Publication Date

2017

### DOI

10.5070/D32310037013

### Copyright Information

Copyright 2017 by the author(s). This work is made available under the terms of a Creative Commons Attribution-NonCommercial-NoDerivatives License, available at <https://creativecommons.org/licenses/by-nc-nd/4.0/>

# Complete resolution of erythema elevatum diutinum using oral sulfasalazine

Michael L Chen<sup>1,2</sup>, Agata Chlopik<sup>3</sup> MD, Mai P. Hoang<sup>3</sup> MD, Gideon P Smith<sup>2</sup> MD PhD

Affiliations: <sup>1</sup>Harvard University, Cambridge, Massachusetts, <sup>2</sup>Department of Dermatology, Massachusetts General Hospital, Boston, Massachusetts, <sup>3</sup>Department of Pathology, Massachusetts General Hospital, Boston, Massachusetts

Corresponding Author: Michael L. Chen, Massachusetts General Hospital, 50 Staniford St. #200, Boston, MA, 02114, USA, Email: michael\_chen@college.harvard.edu

## Abstract

Erythema elevatum diutinum (EED) is a rare, chronic small-vessel vasculitis that presents as firm, red, violaceous, or brown papules and nodules on the extensor surfaces of the limbs. Oral dapsone is considered first-line therapy for EED; in the current case report, a patient presenting with EED began dapsone treatment and symptoms subsided within two weeks. Seven months later, the patient became pregnant and stopped dapsone owing to her concerns with dapsone use during pregnancy, resulting in recurrence of EED symptoms. We present a novel treatment approach with oral sulfasalazine, which was given to the patient in lieu of dapsone and resulted in complete resolution of EED symptoms.

*Keywords: erythema elevatum diutinum, dapsone, sulfasalazine, pregnancy*

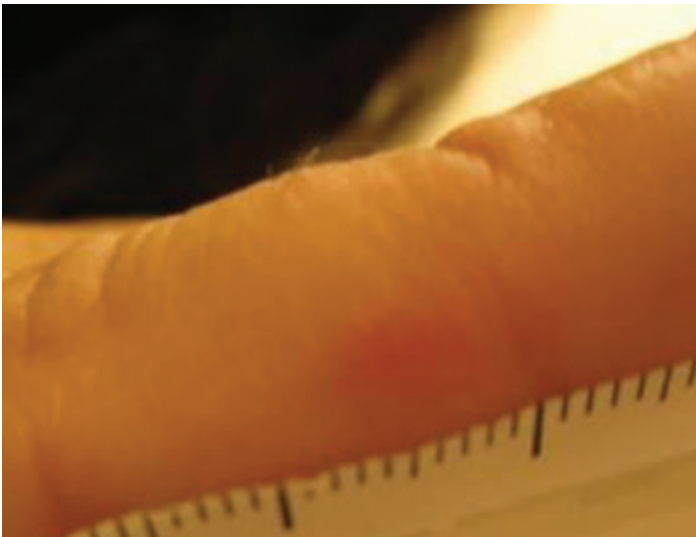
## Introduction

Erythema elevatum diutinum (EED) is a rare, chronic leukocytoclastic vasculitis characterized by firm, red, violaceous, or brown papules and nodules on the extensor surfaces of the limbs. As with most rare diseases, data on therapeutic effectiveness is sparse, but oral dapsone is currently considered first-line therapy [2] and was shown to be effective in 80% of EED cases [1]. However, dapsone may not be effective in certain EED presentations (e.g. fibrotic nodules) or tolerated in certain patient populations (e.g. those with renal or hepatic impairment, G6PD deficiency, anemia), [1,3]. We report a patient with complete resolution of EED using sulfasalazine.

## Case Synopsis

A 35-year old woman with a one-year history of worsening joint pain of the hands, knees, ankles, and feet was referred by the emergency department for a rash. At presentation to the dermatology outpatient clinic, the patient reported pain in her right third metacarpophalangeal joint (MCP) and small, mildly tender nodules over her right thumb, right fifth digit, right third MCP, left hand, left elbow, and lateral tongue. She reported a history of blue discoloration of her right second and third fingertips, which progressed to redness and swelling. Additionally, she reported headaches distinct from past migraines. The differential diagnosis, based on clinical findings, included perniosis in the setting of systemic lupus erythematosus (SLE), neutrophilic dermatosis, or localized vasculitis. Although SLE would explain her joint pain, it was clinically unlikely owing to a negative review of systems (ROS), including absence of photosensitivity, malar rashes, nephritis, pleurisy, blood clots, and gastrointestinal problems. Given the classic appearance and distribution of localized nodules, EED was suspected.

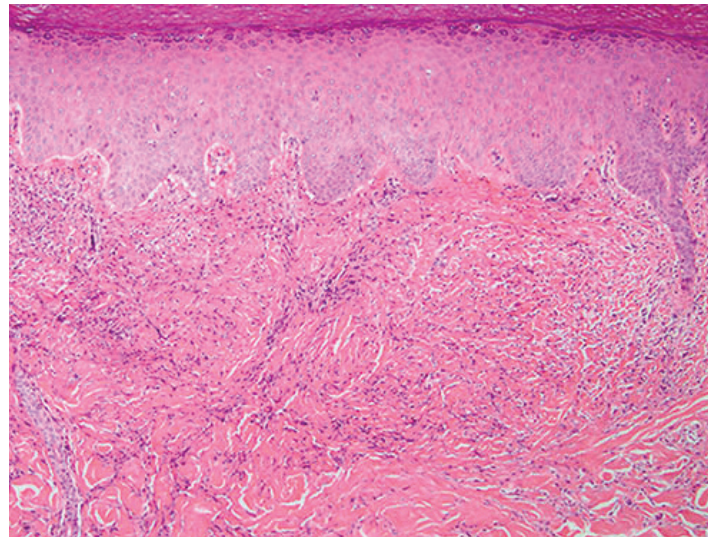
Laboratory results showed a complete blood count and basic metabolic panel within normal limits, calcium: 9.2 (8.5-10.9 mg/dL), and total protein: 6.8 (6.3-7.9 g/dL). Laboratory results were also negative for anti-double stranded deoxyribonucleic acid (anti-dsDNA), antinuclear antibodies, anti-Scl-70, anti-Ro/La, serum protein electrophoresis, and relevant urinalyses. The patient had no known risk factors for human immunodeficiency virus (HIV) or hepatitis, but an HIV and hepatitis screen were negative in the emergency room (ER) immediately prior to the



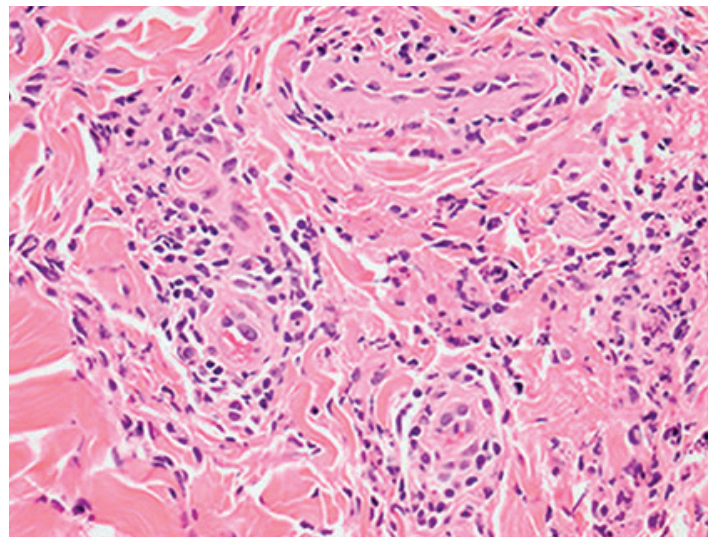
**Figure 1.** Biopsied lesion on the right fifth digit.

dermatology outpatient clinic visit. Both a magnetic resonance imaging scan of the head and a chest X-ray in the ER were unremarkable. The patient reported no symptoms of streptococcal infections and had no clinical history or any indication on exam; because the condition had been on-going, antistreptolysin O titer was not felt to be needed clinically. With a negative ROS for the relevant conditions and the work-up to date, anti-neutrophil cytoplasmic antibodies (ANCA) and antiphospholipid antibodies were not indicated.

A skin biopsy was performed on the right fifth digit (**Figure 1**) and histopathology showed an acanthotic epidermis and underlying diffuse infiltrate of neutrophils in the dermis (**Figure 2**). Features of vasculitis such as fibrinoid necrosis of vessel walls were not seen (**Figure 3**). The histologic differential diagnosis of EED includes other neutrophilic dermatoses such as leukocytoclastic vasculitis, granuloma faciale, and Sweet syndrome. Leukocytoclastic vasculitis was excluded because of the absence of vasculitis and the well-established EED lesions exhibiting a more diffuse dermal infiltrate of neutrophils [4]. Granuloma faciale was clinically unlikely because extrafacial manifestation is uncommon [5]. Granuloma faciale would be characterized by a well-established Grenz zone, sparing of hair follicles, and a higher proportion of eosinophils compared to neutrophils. Sweet syndrome was excluded owing to lack of papillary dermal edema and a denser infiltrate of neutrophils. These histopathologic findings with the clinical presentation supported a diagnosis of EED.



**Figure 2.** A prominent dermal infiltrate is noted in the dermis (H&E, 100%).



**Figure 3.** Neutrophils around dermal blood vessels but no features of vasculitis are seen at high magnification (H&E, 200%).

The patient began oral dapsona treatment with no EED flares following the second week of treatment. Seven months later, the patient became pregnant and stopped dapsona (pregnancy category C) treatment, as she was concerned with dapsona use in pregnancy. Within three days, the patient reported recurrence of extreme pain, swelling in the hands, and an inability to perform daily functions, sleeping fewer than two hours per night because of extreme pain.

Treatment with oral sulfasalazine was suggested to the patient. Soon after initiation of sulfasalazine, the patient reported full remission of EED symptoms. She continued sulfasalazine treatment with success

throughout pregnancy and after delivery without reappearance of nodules or other EED symptoms.

## Case Discussion

Dapsone is accepted as first-line treatment for EED. However, dapsone has proved ineffective in some cases [2,3]. This case report suggests sulfasalazine as a viable alternative to dapsone.

Sulfasalazine was selected for treatment because it is composed of sulfapyradine and 5-aminosalicylic acid linked by an azo group, which degenerates into its constituent components in the small intestine. Sulfapyradine and dapsone share a similar structure in that they are both sulfonamides and have similar antibiotic and anti-metabolic properties, such as inhibiting myeloperoxidase. Dapsone's efficacy in dermatitis herpetiformis and EED is believed to be a result of this ability to inhibit myeloperoxidase. Because sulfasalazine also has this feature, it was selected as a potential replacement of dapsone.

## Conclusion

We report a novel treatment approach for EED using oral sulfasalazine, which was given to the patient and resulted in complete resolution of EED symptoms. Although the difference in safety is not explicitly proven, and many physicians are comfortable with the safety of dapsone in pregnancy, some patients may feel more comfortable with sulfasalazine (category B) as their medication of choice during pregnancy over dapsone (category C).

## References

1. Momen SE, Jorizzo J, Al-Niaimi F. Erythema elevatum diutinum: a review of presentation and treatment. *J Eur Acad Dermatol Venereol*. 2014;28(12):1594-1602. [PMID: 25288365].
2. Wilkinson SM, English JS, Smith NP, Wilson-Jones E, Winkelmann RK. Erythema elevatum diutinum: a clinicopathological study. *Clin Exp Dermatol*. 1992;17(2):87-93. [PMID: 1516248].
3. Porneuf M, Duterque M, Sotto A, Jourdan J. Unusual erythema elevatum diutinum with fibrohistiocytic proliferation. *Br J Dermatol*. 1996;134(6):1131-1134. [PMID: 8763440].
4. Gibson LE, El-Azhary RA. Erythema elevatum diutinum. *Clin Dermatol*. 2000;18(3):295-299. [PMID: 10856661].
5. Thiyanaratnam J, Doherty SD, Krishnan B, Hsu S. Granuloma faciale: case report and review. *Dermatol Online J*. 2009;15(12):3. [PMID: 20040253].