

# UC Davis

## UC Davis Previously Published Works

### Title

A New Framework for Investigating the Biological Basis of Degenerative Cervical Myelopathy [AO Spine RECODE-DCM Research Priority Number 5]: Mechanical Stress, Vulnerability and Time

### Permalink

<https://escholarship.org/uc/item/7sm5419z>

### Journal

Global Spine Journal, 12(1\_suppl)

### ISSN

2192-5682

### Authors

Davies, Benjamin M  
Mowforth, Oliver  
Gharooni, Aref-Ali  
et al.

### Publication Date

2022-02-01

### DOI

10.1177/21925682211057546

Peer reviewed



# A New Framework for Investigating the Biological Basis of Degenerative Cervical Myelopathy [AO Spine RECODE-DCM Research Priority Number 5]: Mechanical Stress, Vulnerability and Time

Benjamin M. Davies, MRCS, BSc, MPhil<sup>1</sup> , Oliver Mowforth, MRCS<sup>1</sup> , Aref-Ali Gharooni, MBChB, MSc (Dist)<sup>1</sup> , Lindsay Tetreault, MD, PhD<sup>2</sup>, Aria Nouri, MD, MSc<sup>3</sup> , Rana S. Dhillon, MD<sup>4</sup>, Josef Bednarik, MD, PhD<sup>5</sup> , Allan R. Martin, MD, PhD<sup>6</sup>, Adam Young<sup>1</sup>, Hitoshi Takahashi<sup>7</sup>, Timothy F. Boerger, PhD<sup>8</sup> , Virginia FJ Newcombe, MD, PhD<sup>9</sup>, Carl Moritz Zipser, MD, FEBN<sup>10</sup>, Patrick Freund, MD, PhD<sup>10</sup>, Paul Aarne Koljonen, MBBS(HK), FRCSEd(Ortho), FHKCOS, FHKAM(Orthopaedic Surgery)<sup>11</sup> , Ricardo Rodrigues-Pinto, MD PhD, FEBOT<sup>12,13</sup> , Vafa Rahimi-Movaghar, MD<sup>14</sup>, Jefferson R. Wilson, MD, PhD, FRCSC<sup>15</sup> , Shekar N Kurpad, MD, PhD<sup>8</sup>, Michael G. Fehlings, MD, PhD, FRCSC, FACS<sup>15</sup> , Brian K. Kwon, MD, PhD, FRCSC<sup>16</sup>, James S. Harrop, MD, MSHQS, FACS<sup>17</sup>, James D. Guest, MD, PhD FACS<sup>18</sup>, Armin Curt, MD, FRCPC<sup>10</sup>, and Mark R. N. Kotter, MD MPhil, PhD<sup>1</sup>

<sup>1</sup>Department of Neurosurgery, University of Cambridge, Cambridge, UK

<sup>2</sup>New York University, Langone Health, Graduate Medical Education, Department of Neurology, New York, NY, USA

<sup>3</sup>Division of Neurosurgery, Geneva University Hospitals, University of Geneva, Genève, Switzerland

<sup>4</sup>Department of Neurosurgery, St Vincent's Hospital Melbourne, Fitzroy, VIC, Australia

<sup>5</sup>Department of Neurology, University Hospital Brno and Faculty of Medicine, Masaryk University, Brno, Czech Republic

<sup>6</sup>Department of Neurosurgery, University of California Davis, Sacramento, CA, USA

<sup>7</sup>Department of Pathology, Brain Research Institute, Niigata University, Niigata, Japan

<sup>8</sup>Department of Neurosurgery, Medical College of Wisconsin, Wauwatosa, WI, USA

<sup>9</sup>Division of Anaesthesia, Department of Medicine, University of Cambridge, Cambridge, UK

<sup>10</sup>University Spine Center, Balgrist University Hospital, Zurich, Switzerland

<sup>11</sup>Department of Orthopaedics and Traumatology, Li Ka Shing Faculty of Medicine, The University of Hong Kong, Hong Kong, China

<sup>12</sup>Spinal Unit (UVM), Department of Orthopaedics, Centro Hospitalar Universitário do Porto - Hospital de Santo António, Porto, Portugal

<sup>13</sup>Instituto de Ciências Biomédicas Abel Salazar, Porto, Portugal

<sup>14</sup>Department of Neurosurgery, Sina Trauma and Surgery Research Center, Tehran University of Medical Sciences, Tehran, Iran

<sup>15</sup>Division of Neurosurgery, Department of Surgery, University of Toronto, Toronto, ON, Canada

<sup>16</sup>Vancouver Spine Surgery Institute, Department of Orthopedics, The University of British Columbia, Vancouver, BC, Canada

<sup>17</sup>Department of Neurological Surgery, Thomas Jefferson University, Philadelphia, PA, USA

<sup>18</sup>Department of Neurosurgery and the Miami Project to Cure Paralysis, The Miller School of Medicine, University of Miami, Miami, FL, USA

## Corresponding Authors:

Mark R.N. Kotter, Department of Neurosurgery, University of Cambridge, Cambridge, UK. Email: [Mrk25@medschl.cam.ac.uk](mailto:Mrk25@medschl.cam.ac.uk)

Benjamin M. Davies, Department of Neurosurgery, University of Cambridge, Hills Road, Cambridge, UK. Email: [bd375@cam.ac.uk](mailto:bd375@cam.ac.uk)



Creative Commons Non Commercial No Derivs CC BY-NC-ND: This article is distributed under the terms of the Creative Commons Attribution-NonCommercial-NoDerivs 4.0 License (<https://creativecommons.org/licenses/by-nc-nd/4.0/>) which permits non-commercial use, reproduction and distribution of the work as published without adaptation or alteration, without further permission provided the original work is attributed as specified on the SAGE and Open Access pages (<https://us.sagepub.com/en-us/nam/open-access-at-sage>).

## Abstract

**Study Design:** Literature Review (Narrative)

**Objective:** To propose a new framework, to support the investigation and understanding of the pathobiology of DCM, AO Spine RECODE-DCM research priority number 5.

**Methods:** Degenerative cervical myelopathy is a common and disabling spinal cord disorder. In this perspective, we review key knowledge gaps between the clinical phenotype and our biological models. We then propose a reappraisal of the key driving forces behind DCM and an individual's susceptibility, including the proposal of a new framework.

**Results:** Present pathobiological and mechanistic knowledge does not adequately explain the disease phenotype; why only a subset of patients with visualized cord compression show clinical myelopathy, and the amount of cord compression only weakly correlates with disability. We propose that DCM is better represented as a function of several interacting mechanical forces, such as shear, tension and compression, alongside an individual's vulnerability to spinal cord injury, influenced by factors such as age, genetics, their cardiovascular, gastrointestinal and nervous system status, and time.

**Conclusion:** Understanding the disease pathobiology is a fundamental research priority. We believe a framework of mechanical stress, vulnerability, and time may better represent the disease as a whole. Whilst this remains theoretical, we hope that at the very least it will inspire new avenues of research that better encapsulate the full spectrum of disease.

## Keywords

cervical, myelopathy, spondylosis, spondylotic, stenosis, disc herniation, ossification posterior longitudinal ligament, degeneration, disability, recovery, questionnaire

## Introduction

Degenerative Cervical Myelopathy [DCM] is an all-encompassing term for cervical spinal cord dysfunction as a result of degenerative, arthritic, and/or congenital changes to the cervical spine.<sup>1</sup> DCM causes a wide range of symptoms, including pain, imbalance and difficulty walking, loss of dexterity, sensory loss, bowel or bladder dysfunction, and in extreme circumstances total paralysis. DCM is estimated to affect 1.4% to 3.1% of adults<sup>2</sup> and today is often associated with significant disability, despite treatment.<sup>3</sup> This has life-long implications, with dependency, unemployment, and mental health difficulties prevalent.<sup>4-8</sup>

AO Spine RECODE-DCM ([aospine.org/recode](http://aospine.org/recode)) [Research objectives and Common Data Elements for DCM] is an international consensus project which aims to accelerate knowledge discovery to improve outcomes, by developing a set of research tools.<sup>9</sup> This process included a James Lind Alliance research priority setting partnership, which brought together both individuals living and working with DCM, to establish the most important unanswered questions. Research prioritization aims to catalyze progress by consolidating resources on key knowledge gaps. The Number five priority identified was improving our understanding of the pathophysiology—that is, the biological basis of DCM.

Amongst the first descriptions of DCM was a surgical case series, published in 1928 by Byron Stookey,<sup>10</sup> which provided a detailed description of symptoms related to ventral compression of the spinal cord. Macroscopically, he reported indentation and displacement of the spinal cord and correlated it with the patient's neurological symptoms, including motor

and sensory disturbances. Initially mistaken for chondromas, Peet end Echols, clarified that the “tumours” are most likely “intervertebral disc protrusions”<sup>11</sup> and thus have a degenerative etiology. Presently, it is recognized that a variety of degenerative changes in the spine can trigger cervical myelopathy.<sup>1,12,13</sup> This led Nouri et al. (2015)<sup>13</sup> to propose “Degenerative Cervical Myelopathy” as a new umbrella term, subsequently endorsed through consensus by the AO Spine RECODE-DCM initiative ([aospine.org/recode](http://aospine.org/recode)).<sup>9</sup>

There are very few human post-mortem studies of DCM.<sup>12</sup> Histologically, Brain et al. noted significant deformation of the spinal cord<sup>14</sup> extensive white and gray matter degeneration, cavity formation, and loss of neurons and axons. In addition, a unique series of ultramicroscopic studies demonstrated evidence of demyelination and incomplete remyelination indicating simultaneous injury and repair.<sup>15</sup> Fehlings et al. suggested that the extensive loss of cells, at least in part, may be related to widespread cellular apoptosis in the spinal cord.<sup>16</sup> Our recent unpublished study investigating markers of macro-autophagy in post-mortem tissue has demonstrated a correlation between symptom severity and dysregulation of autophagy, providing the first human evidence for a mechanistic explanation for the apoptotic cell death observed in DCM tissue.

Together, these studies highlight the intricate relationship between structural changes in the spinal column and the functional consequences that occur in the spinal cord, which form the basis of DCM.

Pre-clinical studies to model DCM pathogenesis are also limited.<sup>17</sup> Compression-based studies include genetic models,

such as the *Twy-Twy* mouse that develops calcification of the ligamentum flavum at C1-C2, and studies of the insertion of synthetic polymers into the spinal canal.<sup>18,19</sup> Studies based on these models have implicated pathobiological changes and processes that include cell apoptosis,<sup>20,21</sup> ischemia,<sup>22,23</sup> axon degeneration,<sup>24</sup> myelin injury,<sup>15,25</sup> and inflammation.<sup>26</sup> While such models have been instructive, compression arising principally from the posterior and in the high cervical region differs from the typical clinical presentation, with the majority of patients presenting with anterior disc compression at C5-6 due to degeneration disc disease.<sup>27</sup>

The longstanding view has been that chronic tissue compression secondary to spinal canal narrowing from degenerative and/or congenital changes is the direct cause of the spinal cord injury in DCM. This concept is reflected in current surgical practice, where decisions are often based on the extent of cord compression visualized by MRI,<sup>28</sup> and less, as our recent clinical guidelines recommend,<sup>29</sup> on the severity of symptoms.

However, the chronic compression paradigm fails to account for the full spectrum of clinical disease (Figure 1), namely:

- (1) Spinal cord compression is common and most frequently incidental and asymptomatic, with approximately 10% of individuals developing symptoms.<sup>2</sup>
- (2) The extent of static spinal cord compression does not correlate well with the severity of symptoms, clinical phenotype, or disease trajectory.<sup>30-36</sup>
- (3) The functional decline in DCM is rarely linear; it can be stable, step wise, or particularly in advanced stages the decline appears to accelerate.<sup>37-39</sup>
- (4) Microstructural MRI has demonstrated that cord damage precedes the loss of spinal cord function and is not restricted to the area of compression.<sup>40-47</sup>

Whilst explanations for these observations have been advanced, including that dynamic spinal cord compression is not captured by routine, supine MRI,<sup>13,48</sup> we propose a broader paradigm, to unify these and other critical and emerging observations in DCM. Specifically, we propose that DCM is a function of mechanical stress, duration of injury and an individual's intrinsic vulnerability to central nervous system injury (Figure 2)

#### *Degenerative Cervical Myelopathy*

$$\int [\text{Mechanical Stress}] \cdot [\text{Vulnerability}] \cdot [\text{Time}]$$

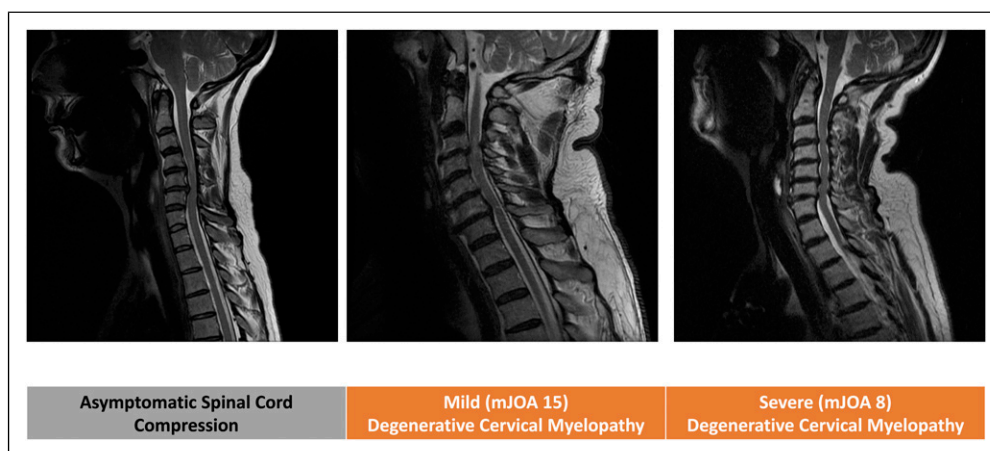
This article will focus on these unifying concepts, that may explain the discrepancies between radiological and clinical findings. Pragmatically therefore, we will not cover in detail the downstream molecular mechanisms demonstrated in DCM research that are well described elsewhere.<sup>12,17</sup>

#### *Mechanical Stress*

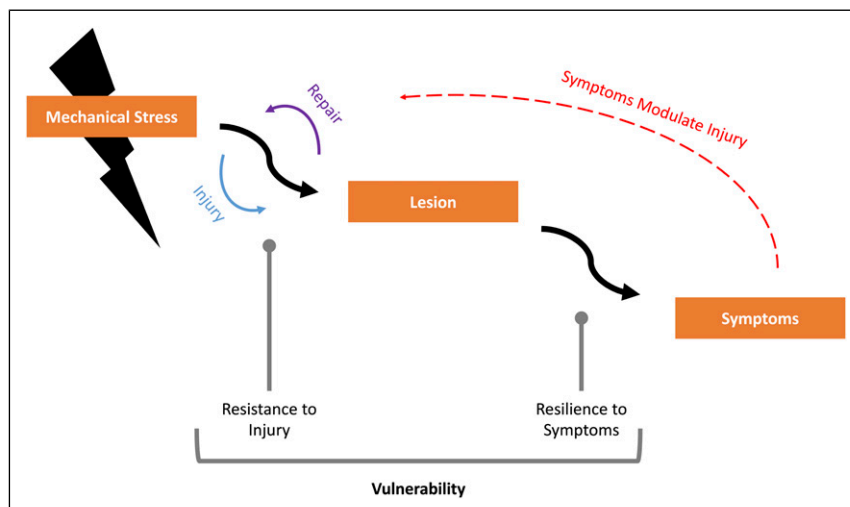
While conceptually, the driver of myelopathic progression has been considered progressively worsening compression, this has not been confirmed by empirical data<sup>30-32,34-36,49</sup> and this view oversimplifies the dynamic situation where several forces will distort not only parenchymal tissue but also blood vessels and nerve roots.<sup>50</sup>

A force is any interaction, that when unopposed, will change the motion of an object. The application of a set of forces to an object give rise to 5 principal mechanisms of loading: compression, tension (i.e., stretch), bending, torsion, and shear (Figure 3).<sup>51</sup> An object subject to a constant force, is referred to as having a static load, whereas a time-varying force(s) a dynamic load.

The local loading in a material element is expressed by the mechanical stress defined as the net force acting on a cross-



**Figure 1. Cord compression does not represent DCM.** Series of T2 weight sagittal cervical spine MRI. Cord compression is commonly incidental [A], even with hyperintensity signal change, and the amount of compression weakly correlates to the disease severity (A vs B vs C).



**Figure 2. DCM is a function of mechanical stress, time, and vulnerability.** Mechanical stress represents the combined effect of loading on the spinal cord as a result of degenerative pathology of the spinal column, and time, its duration. This then drives initially injury to the spinal cord, which will be retarded by repair processes but subsequently lead to symptoms. Vulnerability represents the factors that govern an individual's ability to resist spinal cord lesion and/or be resilient to developing symptoms as a consequence.

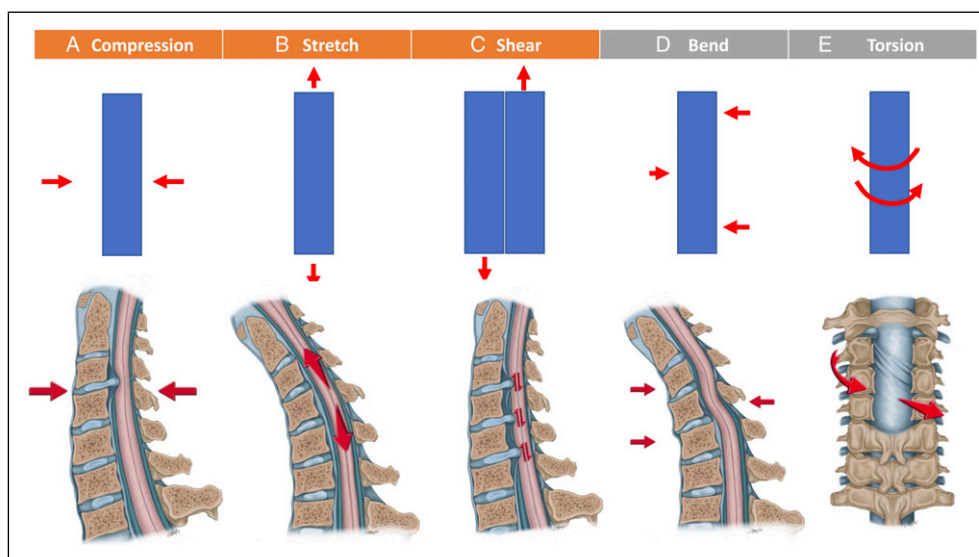
sectional area ( $\sigma = \text{Force } (F) / \text{Cross - Sectional Area } (A_0)$ ). This can be used to represent the internal distribution of forces in response to loading. At this small element level therefore, tension, compression, and shear are the local stresses but at a structural level, these can act in combination, to give rise to bending or torsional loads. Compression and tension forces across the cross section correspond to tensile and compressive stresses, while a shear force transmitted across the section corresponds to a local shear stress in the material element. Deformation of the material at a local level is characterized by the local strain. Like stress, it can occur in tension, compression, or shear in response to the applied stress.<sup>52</sup> Consequently, the deformation of a material due to loading is often described in terms of the stress–strain relationship, and the nature of this curve defines the mechanical properties of a material.<sup>53</sup>

The spinal cord is a viscoelastic material, meaning that it has both viscous (stress and strain are dependent on rate) and elastic (material will return to original form once loading has stopped) properties.<sup>54</sup> Combining these components gives rise to three main characteristics of viscoelastic material behavior: creep, stress relaxation, and hysteresis (Figure 4). Creep refers to the continued deformation of the material after a load has reached a constant state. Stress relaxation refers to the reduction in stress when a material is held at a constant strain or deformation. Hysteresis refers to differences in the loading and unloading response, as represented by a stress–strain graph. The area between the two curves represents the energy dissipated. For this reason, viscoelastic materials are used as shock absorbers. The peak stress in viscoelastic materials is also dependent on the rate of loading, due to a rate-dependent stiffening of the material. Consequently, a faster loading rate leads to a greater peak stress.<sup>55</sup> Any elastic properties have a

threshold beyond which they will exhibit irreversible or “plastic deformation.” (Figure 4) This is best appreciated with an elastic band; stretch up to a limit will enable an elastic band to return to its original shape but stretch beyond this and the band will be permanently elongate, and further increases eventually cause it to snap. A viscoelastic material which acquires plastic properties, becomes a viscoplastic material.<sup>56</sup>

Whilst plastic deformation of the spinal cord occurs in DCM, it is not a determinant of it.<sup>49</sup> Harada et al. (1992) demonstrated a subset of patients recovered normal spinal cord shape following surgical decompression<sup>57</sup> and Martin et al.<sup>40</sup> (2018) observed plastic deformation in a cohort of asymptomatic spinal cord compression. In DCM therefore, as static compression is chronic and the spinal cord remains viscoelastic, stress from compression specifically would be limited.<sup>58</sup>

However, the response of the spinal cord to loading is complicated by its normal mobility. The spinal cord is suspended (therefore under modest tension) within cerebrospinal fluid (CSF) contained by the dural sac, and only partially anchored by the dentate ligaments and to a lesser extent connected vasculature. The spinal cord continuously moves in all three directions, cranial-caudal, anterior-posterior and right-left.<sup>59,60</sup> This movement is now well demonstrated using MRI techniques,<sup>61-63</sup> and thought to be principally related to the cardiac cycle, due to local pulsatile vascular changes and/or similar displacement of the brain from arterial in and venous outflow, but also the respiratory cycle.<sup>64</sup> Contrary to previous belief, the denticulate ligaments limit cranial-caudal movements of the SC, being especially resistant to caudal stress, but have minimal or no significant contribution to limiting anterior-posterior motion.<sup>65,66</sup> This is now used diagnostically, for example, to identify a tethered spinal cord using MRI



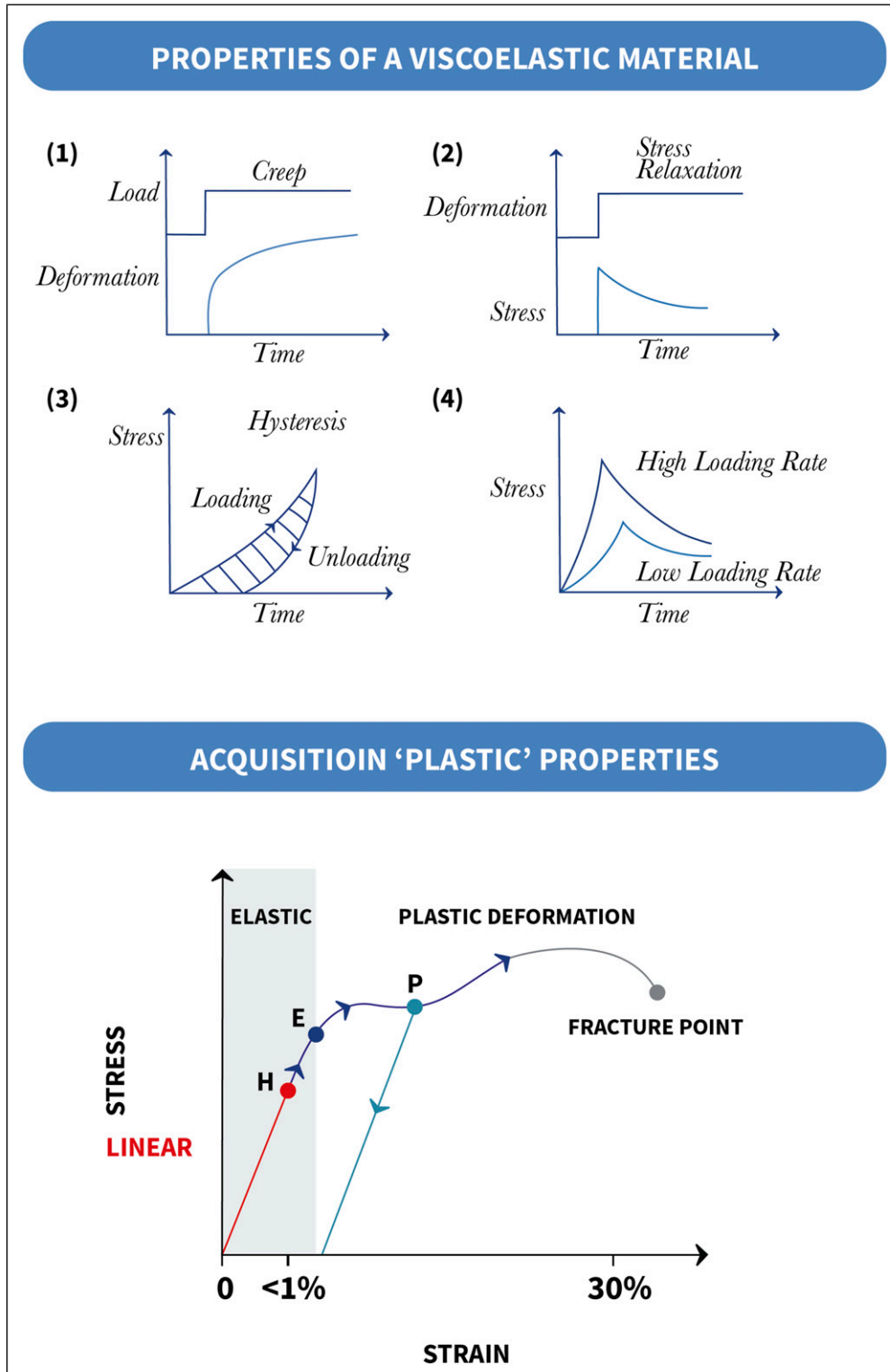
**Figure 3.** There are 5 principal types of mechanical loading: Compression [A], Tension (or Stretch) [B], Shear [C], Bending [D], and Torsion [E]. At a small element level, compression, tension, and shear are the local stresses [Orange] but at a structural level, these can act in combination, to give rise to bending or torsional loads [Gray]. Compression is the application of an inward force. Tension is the application of a force which elongates a material. Shear forces result from sliding contact between two parallel surfaces. Loading methods are figuratively represented in row 1, and how these might apply to DCM in vivo illustrated in row 2.

in the prone position.<sup>67,68</sup> Further, the material properties of the spinal cord change with normal movement of the spine.<sup>69,70</sup> This is largely in flexion, where the spinal cord lengthens,<sup>71,72</sup> and the cross-sectional area of the spinal cord reduces,<sup>73,74</sup> estimated to exhibit a strain of 12% in normal physiological conditions.<sup>75-77</sup> Movement of the spine can be abnormally increased in DCM,<sup>78</sup> with spondylolisthesis radiologically prevalent,<sup>27</sup> and an association with laxity disorders such as Ehlers Danlos Syndrome.<sup>79</sup> Such findings have been associated with differing clinical manifestations of DCM.<sup>78,80,81</sup>

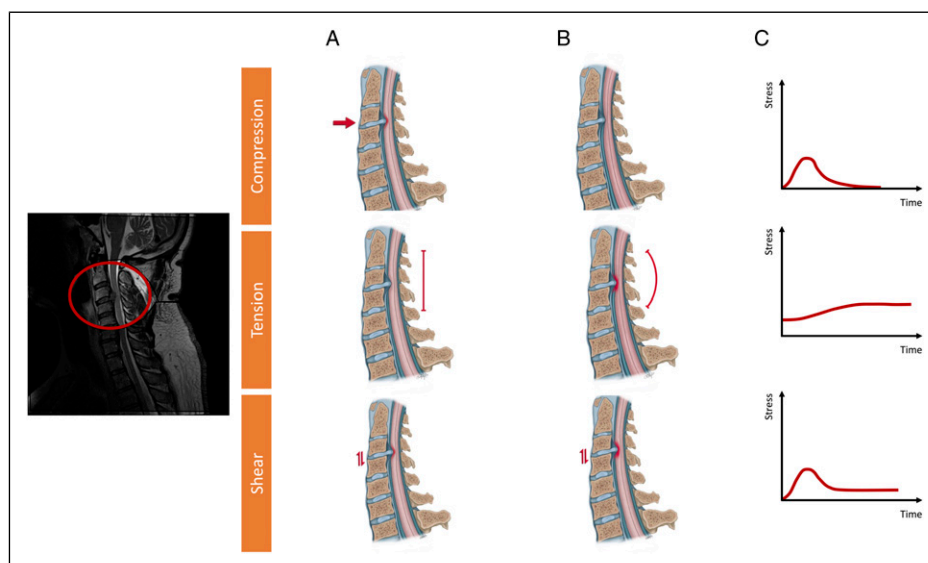
On a biomechanical level then, compression is not the only mechanical force involved, nor likely dominant force in all cases. For example, as illustrated in Figure 5, if one considers a single level disc prolapse (the cause of 10% of DCM cases with in the AO Spine Series<sup>27</sup>), then a variety of different loading mechanisms may occur; compression (due to perpendicular contact), tension (second to displacement and elongation of the spinal cord, and/or the effect of tethering), and shear (due to oscillation of the spinal cord over the surface of the disc prolapse).<sup>82</sup> Compression loading is defined as applying force inwards that is balanced by an at least equal opposing force.<sup>51</sup> As a soft mobile structure therefore, unilateral compression of the spinal cord, for example, may displace and not necessarily compress the spinal cord. Finite-element modeling has replicated this concept, identifying thresholds for ventral compression to exceed before mechanical stress is detected.<sup>83,84</sup> This is also supported by histological studies indicating the spinal cord tolerance of some compression,<sup>85,86</sup> with a re-alignment of spinal pathways, and cadaveric models demonstrating tension-related deformation before compression-related deformation.<sup>82,87,88</sup>

A strong argument for tension (or stretch) as a dominant mechanism of injury in DCM was advanced by Henderson et al. (2005),<sup>76</sup> combining pre-clinical, clinical, and mathematical data sources. This is further supported now by microstructural imaging studies, which are demonstrating structural change throughout the spinal cord,<sup>89-91</sup> well beyond the proposed level of stenosis and poses interesting questions for a significant relationship with tandem stenosis.<sup>92</sup>

The significance of shear forces however is also likely to be more significant than currently understood. Vavasour et al.<sup>93</sup> (2014) used phase-contrast MRI to evaluate the significance of CSF flow in 13 DCM patients and age-matched healthy controls. Based on their results, whilst CSF flow dynamics were associated with the compression ratio, they were not related to clinical function (as measured using somatosensory evoked potentials or the Japanese Orthopaedic Association scale [JOA]). However, their analysis also measured spinal cord oscillation (cranio-caudal), calculating mean velocity and absolute and maximum displacement, based on integrating the velocity time curve. These measures did correlate with clinical function. These results have been subsequently external validated by Wolf et al. (2018), and the subject of a follow-up, and ongoing observational study.<sup>64,94</sup> Wolf et al. (2018) hypothesize that the reduction in CSF volume at levels of stenosis, reduces the ability of CSF to absorb mechanical stress and contributes to increased oscillation. Whilst only case reports, there are clinical indications of the significance of CSF to DCM,<sup>95</sup> for example, where CSF diversion (e.g., a lumbar puncture) has led to a rapidly worsening clinical picture.<sup>96-98</sup> The measurement of CSF pressure in DCM, and its response to dynamic manipulation (e.g., head inclination



**Figure 4. Mechanical properties of a viscoelastic material.** After the load has reached a constant state, the material continues to deform (Creep, 1). This causes a reduction in stress (Stress Relaxation, 2) over time. This reduction is faster than its acquisition, causing a hysteresis loop (3) which represents energy lost. The amount of stress measured is related to the rate of loading (4). [Adapted from<sup>55</sup>] However, elastic properties have a threshold at which further loading will cause permanent deformation (when the load is removed) (5); termed the yield point (E). The shape change can be associated with a temporary reduction in stress (P). A viscoelastic material which acquires plastic properties can be termed viscoplastic [Adapted from].<sup>210</sup>



**Figure 5. Case Example:** A single level disc prolapse without deformity or instability (MRI, T2 Weighted Sagittal Image). The resultant local forces exhibited at onset [A] and as the spinal cord responds to loading [B] are illustrated anatomically and represented with exemplar stress/time curves [not to scale] [C]. DCM is associated with a solitary disc prolapse in 1 in 10 surgical cases. Whilst this contact would cause a compressive load to be applied to the spinal cord [A], this contact induce both compression and shear forces on the spinal cord due to its oscillation. As a unilateral force, the spinal cord would be displaced posteriorly [B], which coupled with the viscoelastic properties of the spinal cord, would cause stress from compression to reduce. Assuming adequate canal capacity this could reduce to zero. However, the displacement would elongate the spinal cord, increasing its baseline physiological tension and shear forces continue due to contact.

or reinclination) is the subject of an ongoing observational study [NCT04345822].<sup>99</sup>

In spinal practice, the pathological significance of non-compressive mechanical loading and spinal cord injury is recognized. For example, tethered cord syndrome arises due to stretch,<sup>100,101</sup> and bending considered the principal loading mechanism in cervical flexion myelopathy (Hiramaya's disease), due to flexion of the spinal cord within a shorter and/or non-elastic dural membrane.<sup>102</sup> At a cellular level, these mechanical forces can change neuronal behavior, for example, neural transmission,<sup>103,104</sup> but also cause cellular injury, with evidence focused in particular on stretch<sup>105,106</sup> and shear<sup>107</sup> forces, as well as compression.<sup>108,109</sup> Of note, much of the more recent evidence evaluating mechanical forces on cell function has originated from within developmental neurobiology, where, for example, axon growth cones have been demonstrated to be modulated by mechanical forces such as stretch.<sup>110</sup> This could have particular relevance to DCM, where due to the chronicity, repair coincides with injury.<sup>15</sup> Russel et al. (2012) using a rat model and Galle et al. (2007) a guinea pig model of spinal cord injury, demonstrated that the location of maximal tissue injury correlated to the area of maximal strain.<sup>111,112</sup>

In DCM, the mechanical stress experienced will be complicated by how these forces interact,<sup>84</sup> for example, in a finite-element model of static compression of the spinal cord, elasticity measured using ultrasound reduced when the spinal cord was compressed.<sup>113</sup> These forces too, will have been exhibited in combination, within the existing pre-clinical models that

underpin our current investigations of DCM.<sup>17,114</sup> Mechanical stress will also be influenced by the different mechanical properties and tolerance of microstructures within the spinal cord, for example, the white vs gray matter, or relative myelin content of spinal cord pathways<sup>115</sup> which are also subject to change, for example, with age and evolution of injury.<sup>50,116</sup>

Consequently, the forces driving spinal cord pathology in DCM are likely to be a combination of loading forces and not simply compression, and we propose would be better represented by an umbrella term of "mechanical stress." They are also likely to be highly individualized and change over "time." Much of the literature exploring the biomechanical properties of the spinal cord has been conducted with a view to application in traumatic spinal cord injury.<sup>117,118</sup> Whilst the clinical significance of mechanical stress in such an acute, and often devastating injury, has so far provided few practical applications,<sup>119</sup> in DCM, the chronicity of the condition may place greater relevance on this, in particular, because removing all mechanical stress is the goal of surgery.<sup>29</sup>

### Vulnerability

Whilst a clearer characterization of mechanical stress and its impact may therefore account for some current inconsistencies, it is unlikely to provide a full explanation for the onset and progression of DCM, and in particular that 1) only a subset of individuals with spinal cord compression develop symptoms related to DCM<sup>1,2</sup> and that 2) symptom severity and

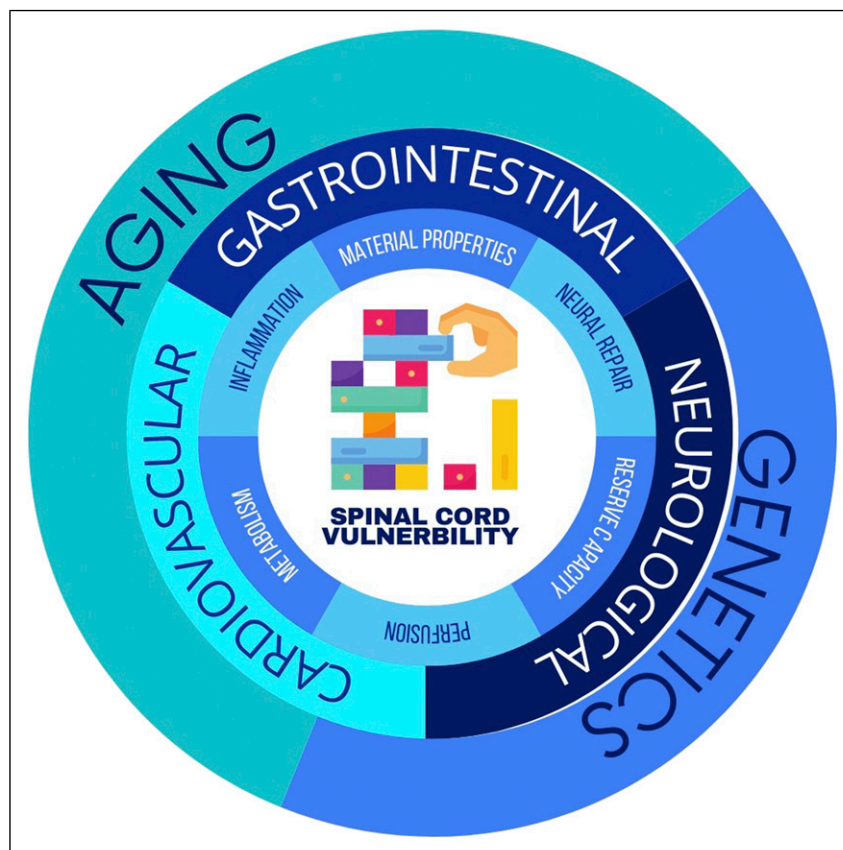

progression does not correlate with spinal cord compression.<sup>28,30</sup>

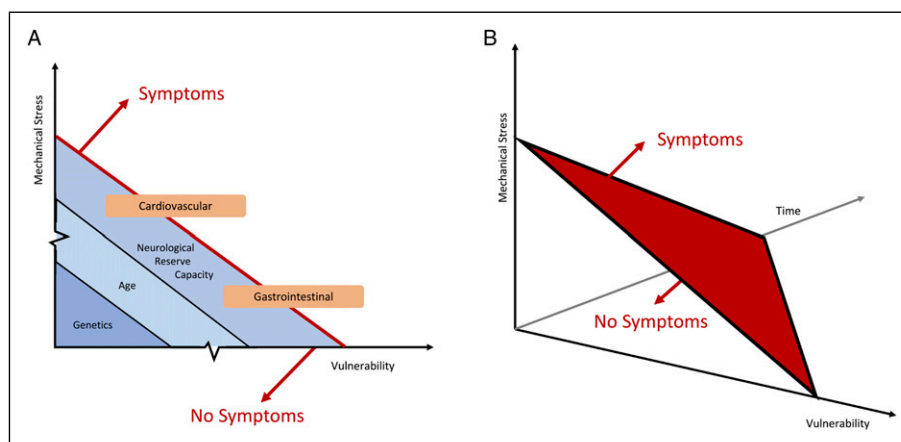
Hence, an additional factor accounting for the development and progression of DCM is required. We propose this is an individual's vulnerability to DCM, a combination of the intrinsic vulnerability of the spinal cord to resist damage from mechanical stress but also the human body to maintain normal homeostatic function; their resilience to symptoms (Figure 6). In other words, mechanical stress in itself is necessary but not sufficient to explain DCM symptoms, and may be seen as a trigger but not the unique cause. A causal concept of DCM requires an additional factor Together, mechanical stress and individual vulnerability, provide a necessary and sufficient framework for a causal understanding of DCM.

**Genetic Effects on the Spinal Cord.** Genetic studies support the concept that intrinsic factors have a role in determining DCM. In a case-controlled study of Utah residents, Patel et al.<sup>120</sup> (2012) demonstrated that first and third degree relatives of individuals with DCM had a 5 (CI = 2.1-13.2,  $P < .001$ ) and 2-fold (CI = 1.04-3.7,  $P < .05$ ) increased relative risk of having

DCM. Mukerji et al. (2007) reported on two identical twins with an early presentation of myelopathy secondary to a cervical disc prolapse.<sup>121</sup> However, more specifically with respect to vulnerability in our recent systematic review of candidate gene studies in DCM, we were able to distinguish between those contributing to spinal column deterioration and those contributing to spinal cord deterioration.<sup>122</sup> We found that 12 genes had an effect on clinical onset of spinal cord disease. Polymorphisms of eight genes were found to have an effect on the radiological severity of DCM, while three genes had an effect on clinical severity. Polymorphisms of six genes had an effect on clinical response to surgery in spinal cord disease. Amongst the genes identified were vulnerability genes, such as *APOE-ε4*,<sup>123,124</sup> and genes such as *BMP4*, in which 6007C > T Single Nuclear Polymorphism (SNP) was found to be protective for the development of clinical signs and symptoms of DCM.<sup>125</sup> Finally, we found that certain genotypes are associated with either increased regenerative capacity (e.g., *HIF1A* 1790G > A polymorphism<sup>126</sup>) or reduced improvements (e.g., *OPN*<sup>127</sup> or the GG genotype of the -66T > G within *RunX2*<sup>128</sup>) following surgical



**Figure 6. Vulnerability.** Many interacting factors are likely to determine an individual's vulnerability. Further research is required to definitively characterize these and their causal mechanisms but for illustrative purposes, those outlined in this article are shown around a 'Jenga' tower, a structure whose preserved stability is defined by the interacting support of many elements but can accommodate some structural changes. Working outwards, potential causal mechanisms, system level and then whole-body factors. This latter distinction is made as genetic and aging processes are likely to mediate influence through systems, as well as the spinal cord directly.



**Figure 7. The 3 dimensions of Mechanical Stress, Vulnerability and Time.** Figure A represents a single time point (time independent), akin perhaps to the onset of injury. The development of symptoms is based on an individual's symptom threshold, related to mechanical stress and their vulnerability. Factors discussed in this review are overlaid: Age, Genetics, and Reserve Capacity specific to vulnerability. Cardiovascular and Gastro-intestinal Factors straddling the symptom threshold, as disability may further modulate vulnerability. Figure B includes time as a third axis, indicating that the symptom threshold is likely to lower with time, as injury persists and vulnerability increases.

decompression. Genes associated with spinal column deterioration were nearly exclusively associated with ossification of the posterior longitudinal ligament, a condition in which the hypertrophy and calcification occurring in the posterior ligament has been associated with an autoimmune-driven cause.<sup>12</sup> Whilst the true epidemiology of DCM has been difficult to characterize, owing to widespread underdiagnosis, current data indicates that DCM or non-traumatic spinal cord injury, is less common amongst Asian populations,<sup>12,129</sup> despite Asian populations having on average smaller canal diameter<sup>130</sup> ordinarily a risk factor of DCM's occurrence<sup>131-133</sup> and a higher prevalence of Ossification of the Posterior Longitudinal Ligament.<sup>134</sup> This further supports a role for individual vulnerability factors in the development of DCM.

### Age Effects on the Spinal Cord

Aging has broad biological implications.<sup>135,136</sup> In clinical practice, older age is associated with increased disease severity (as quantified based on neuromuscular function) at presentation, however, this does not appear a consequence of a greater length of time with symptoms, for example, due to delayed diagnosis.<sup>137</sup> Further, whilst operative treatment on average involves more levels and has an increased occurrence of adverse events,<sup>137</sup> when these factors and baseline severity were controlled for using a propensity matched analysis in the AO Spine observational data, age alone still reduced the extent of recovery.<sup>138,139</sup>

The significance of age is likely to be multifactorial, contributing both to resilience to symptoms but also resistance to injury.<sup>136</sup> Age is recognized to interact with neural repair mechanisms, for example, affecting axonal outgrowth<sup>140,141</sup> and remyelination.<sup>142,143</sup> Imaging<sup>144-147</sup> and autopsy studies<sup>148-150</sup> have also demonstrated that the volume and properties of the

spinal cord alter with age in the absence of disease. This occurs both within the gray and white matter, albeit is markedly less (approximately 1/3) of what is observed within the brain.<sup>144</sup> Exploring this using a mouse model, Piekartz et al.<sup>151</sup> (2020) demonstrated that age was associated with axon loss and demyelination, in particular a loss of and altered morphology of alpha-motor neurons, and an altered extracellular matrix. Further, biological processes changed, with evidence of increased apoptosis, low levels of inflammation and increased vascular permeability, and different genetic expression patterns with a reduction in mitochondrial protein synthesis. Of note, the increased vascular permeability, as measured using contrast MRI specifically, was only altered for the cervical spinal cord. Morales et al.<sup>152</sup> (1987) using electrophysiology in young and aged cats, identified increased resistance and reduced conduction velocity in alpha-motor neurons.

On a biomechanical level, these changes will alter the material properties and the response to loading of the spinal cord. Sparrey et al. (2009) explored this using a finite-element model of thoracic spinal cord compression. They demonstrated that changes to both white and gray matter structures increased measured mechanical stress, with changes to the white matter most significant.<sup>153</sup> Okazaki et al.<sup>116</sup> (2018) comparing young and old bovine spinal cord specimen demonstrated different tensile and compression stress patterns, in particular, during compression modeling within young specimen, stress was largely confined to white matter structures, whereas in older specimen distributed throughout the spinal cord.

Understanding the significance of age is complicated by the emerging distinction between chronological, that is, the passing of time, and what is termed biological age, that is, the presence of specific aging hallmarks within cells.<sup>154</sup> A number of markers of biological age, including epigenetic expression

patterns, have been determined.<sup>155</sup> Whilst their assessment is further complicated by the observation that biological age can differ between tissue or organ systems,<sup>156</sup> accelerated biological aging is now linked to numerous diseases of the central nervous system and a potential therapeutic target.<sup>157</sup> This distinction perhaps aligns with clinical practice, where, for example, frailty is a better indicator of morbidity than age in DCM.<sup>158</sup>

*Cardiovascular System Effects on the Spinal Cord.* Ischemia and/or microvascular changes within the spinal cord are a common feature in pre-clinical models and autopsy specimen of DCM. Ischemia due to a perfusion deficit<sup>74</sup> possibly as a result of microvascular changes<sup>22</sup> has been proposed as a common final pathway of critical compression.<sup>23</sup> Ellingson et al.<sup>159</sup> (2019) using MRI to evaluate spinal cord perfusion in a cohort of cervical spondylosis with and without myelopathy, demonstrated that neurological function using the modified JOA (mJOA) was inversely correlated with oxygen extraction.

The importance of maintaining perfusion is better demonstrated in traumatic spinal cord injury, where it is considered an important neuro-protective strategy.<sup>160,161</sup> Spinal cord perfusion is physiologically maintained through autorregulation; however, spinal cord damage can cause its dysregulation.<sup>162,163</sup> This has been demonstrated in pre- or non-operative<sup>164</sup> and peri-operative DCM patients.<sup>165-167</sup> Hukude et al. (1988) using a canine model of DCM, demonstrated differing features of spinal cord injury in the context of high, normal, and low systemic blood pressure, across a range of compression thresholds.<sup>168</sup> This is supported clinically more recently in studies, which have demonstrated that the presence of cardiovascular disease was negatively associated with functional outcomes following surgery,<sup>33,169</sup> and one study demonstrating different signal intensity patterns within the spinal cord on MRI.<sup>170</sup> A prospective observational study of cord perfusion, in patients undergoing surgery for DCM is currently underway [NCT04345822].<sup>99</sup>

Cardiovascular disease, including atherosclerosis, acute coronary syndromes and hypertension, are common comorbidities amongst patients with DCM.<sup>171</sup> The observed ischemia in the spinal cord however is unlikely a direct consequence of plaque or emboli; the incidence of spinal cord infarction is extremely low,<sup>172</sup> and in an autopsy study of 603 aged spinal cord specimen, Wang et al.<sup>173</sup> (1996) observed that atherosclerotic changes were extremely rare within the spinal cord or its radicular arteries, even in the presence of systemic atherosclerosis. Instead, a recent population study from Taiwan identified DCM as an independent risk factor for the occurrence of acute coronary syndromes, including myocardial infarction<sup>174</sup> suggesting a potentially consequential relationship of DCM on the cardiovascular system. This is supported by a series of observational studies in patients undergoing decompressive surgery, in which surgery led to a reduction in blood pressure, with some able to stop prior anti-hypertensive medication.<sup>175-177</sup> Autonomic dysfunction

is also demonstrated in cervical spondylosis without myelopathy and asymptomatic spinal cord compression,<sup>167,178,179</sup> including a further population study from Taiwan reporting an increased incidence of arrhythmia amongst those with cervical spondylosis.<sup>180</sup> Whilst studies have not conducted longitudinal observation in these cohorts, to explore any relationship to the subsequent onset of DCM, this would align with the idea of compensation and a vulnerability threshold, for which an already impaired and/or medicated cardiovascular system may have implications.

*Gastro-Intestinal System Effects on the Spinal Cord.* Biological processes and pathways are can be influenced by nutrition. In extreme circumstances, these can cause neurological disease directly, such as in the case of B12 or Folate deficiencies. However, this is likely to represent one end of a spectrum, with less significant deficiencies a contributory factor for example with implications for neural repair.<sup>181</sup> In clinical studies, there are increasing indicators for this. Nouri et al.<sup>182</sup> (2020) in a retrospective analysis of 725 patients undergoing surgery for DCM or degenerative cervical radiculopathy, demonstrated macrocytic anemia was more common in DCM, and its presence associated with poorer pre-operative neurological status. Further, Allam et al.<sup>183</sup> (2017) (61) conducted a randomized controlled study (N = 192), in patients declining surgery for DCM of Cerebrolysin, a mixture of amino-acids and peptides given via intramuscular injection, demonstrating neurological benefit for the treatment arm.

Related to nutrition, is the increasing interest within Neuroscience of the gut-brain axis, a system with bidirectional (central nervous system on gut, and gut on central nervous system [CNS]) significance on human function and disease.<sup>184</sup> This includes increasing interest in the role of the microbiota (the organisms that reside within the gut) and the microbiome (the genetic material of the microbiota) in a range of neurological diseases, including Parkinson's Disease, Autism Spectrum Disorder, Multiple Sclerosis, Stroke<sup>185</sup> but also traumatic Spinal Cord Injury.<sup>186</sup> Mechanistically changes in the gut microbiota are principally hypothesized to influence the CNS as consequence of a differential production, expression and turnover of neural transmitters, or via modulation of inflammatory response.<sup>184</sup> Conversely modulation of the brain to gut function is partly a cause of the autonomic system which is frequently disrupted in disease of the spinal cord. Longitudinal studies in traumatic spinal cord injury demonstrate a significant change in the microbiota following injury.<sup>186</sup> This autonomic disruption may also have wider implications for the gastro-intestinal system, including organs that direct metabolism (such as the liver, adrenal glands, and adipose tissue) but also mediate the immune response (such as the spleen).<sup>187</sup> Altered metabolism itself is linked to an altered immune response; with so called meta-inflammation, a pro-inflammatory state.<sup>188</sup> Inflammation is emerging as a key mediator of disease and disability in DCM.<sup>189-192</sup> In a chronic disease such as DCM, one could therefore speculate that there

is a further area of evolving interaction; that gastro-intestinal dysfunction due to DCM could modulate their spinal cord biology. In support of this hypothesis, Nouri et al.<sup>193</sup> (2020) in a secondary analysis of the AO Spine series observed that patients with gastro-intestinal co-morbidities had equivalent disease severity as measured using the mJOA, but different patterns of disease on conventional MRI, including the frequency and nature of signal intensity changes.

**Neurological System—Adaptive Neuroplasticity and Redundancy to Increase Resilience.** Injury to the cervical spinal cord causes structural and functional connectivity changes within the brainstem and cerebrum that may include adaptive neuroplasticity.<sup>90,194,195</sup> Studies in DCM, principally using advanced MRI techniques,<sup>196-202</sup> but also transcranial magnetic stimulation,<sup>203</sup> have demonstrated that the presence and nature of these changes can represent clinical symptoms, including pain and neuromuscular function, and predict response to surgery. Principal regions of interest have been the visual pathways (hypothesized to represent an increase reliance on vision for balance)<sup>201,204</sup> and supplementary motor areas.<sup>195,203,205</sup> For example, Zdunczyk et al.<sup>203</sup> (2017) using transcranial magnetic stimulation of the motor cortex, demonstrated that a greater neuromuscular function (defined using the JOA) was associated with a steeper recruitment curve and activation of supplementary motor areas, and proposed the concept of corticospinal reserve capacity.

This concept has been proposed across a range of neurological diseases to account for disconnects between histological lesion burden and clinical phenotype.<sup>206</sup> Whilst a number of different terms have been used to describe this,<sup>187,203</sup> it is increasingly talked of as the “reserve capacity.”<sup>207</sup>

This mirrors what is observed in DCM; cervical spinal cord tissue injury in DCM is initially asymptomatic<sup>2,40</sup> and the radiological changes affecting the spinal cord, at best offer a partial surrogate for the disease phenotype.<sup>31,208,209</sup>

## Conclusion

There is a clear need to improve understanding of the pathophysiological mechanisms and their clinical correlates for DCM. Resolution of such uncertainty is key to optimizing both management using current therapies and to inform the development of new ones. Based on the current evidence we propose DCM should be considered a function of mechanical stress, vulnerability, and time. Mechanical stress encompasses multiple mechanisms of loading, and not simply compression, whilst vulnerability relates to primary protective mechanisms such as genetic makeup and age, as well as adaptive protective mechanisms, such as autoregulation, functional reserve capacity, and nutritional status [Figure 7]. These concepts remain theoretical at this stage, and areas for further investigation. While our model is an oversimplification of a complex and multifactorial problem,<sup>33</sup> we hope that it will inspire a fresh view on DCM and encourage new avenues of

research to better encapsulate the full spectrum of clinical disease. This is critical to optimizing both current management and informing the development of new therapies.

## Acknowledgments

Further details on this priority, including how it was prioritized, why it was prioritized, and on-going research activity can be found at [www.aospine.org/recode/biological-basis](http://www.aospine.org/recode/biological-basis).

We thank Dr Robert Farr (London Institute, UK) and Prof. Michael Sutcliffe (University of Cambridge) for support with regards to the physical models. We thank Aimee Hutchinson [[www.aimeehutchinson.com](http://www.aimeehutchinson.com)], Medial Illustrator, for the anatomical drawings of the cervical spine, and Iwan Sadler ([Myelopathy.org](http://Myelopathy.org)) for assistance with producing the figures.











## Declaration of Conflicting Interests

The author(s) declared no potential conflicts of interest with respect to the research, authorship, and/or publication of this article.

## Funding

The author(s) disclosed receipt of the following financial support for the research, authorship, and/or publication of this article: The research priorities were organized and funded by AO Spine through the AO Spine Knowledge Forum Spinal Cord Injury, a focused group of international Spinal Cord Injury experts. AO Spine is a clinical division of the AO Foundation, which is an independent medically-guided not-for-profit organization. Study support was provided directly through the AO Spine Research Department. MRNK is supported by a NIHR Clinician Scientist Award and BMD a NIHR Clinical Doctoral Research Fellowship. P.F. is funded by a SNF Eccellenza Professorial Fellowship grant (PCEFP3\_181362/1)VFJN is supported by an Academy of Medical Sciences / The Health Foundation Clinician Scientist Fellowship. This report is independent research arising from a Clinician Scientist Award, CS-2015-15-023, supported by the National Institute for Health Research. The views expressed in this publication are those of the authors and not necessarily those of the NHS, the National Institute for Health Research or the Department of Health and Social Care. JB was supported by the Czech Health Research Council grants NV18-04-00159 and by the Ministry of Health of the Czech Republic project for conceptual development in research organizations, ref. 65269705.

## ORCID iDs

Benjamin M. Davies  <https://orcid.org/0000-0003-0591-5069>  
 Oliver Mowforth  <https://orcid.org/0000-0001-6788-745X>  
 Aref-Ali Gharooni  <https://orcid.org/0000-0002-6705-1115>  
 Aria Nouri  <https://orcid.org/0000-0002-4965-3059>  
 Josef Bednarik  <https://orcid.org/0000-0001-7420-2383>  
 Timothy F. Boerger  <https://orcid.org/0000-0003-1587-3704>  
 Paul Aarne, Koljonen  <https://orcid.org/0000-0002-9250-653X>  
 Ricardo Rodrigues-Pinto  <https://orcid.org/0000-0002-6903-348X>  
 Jefferson R. Wilson  <https://orcid.org/0000-0001-5965-0305>  
 Michael G. Fehlings  <https://orcid.org/0000-0002-5722-6364>

## References

1. Davies BM, Mowforth OD, Smith EK, Kotter MR. Degenerative cervical myelopathy. *BMJ*. 2018;360:k186. doi:10.1136/bmj.k186.
2. Smith SS, Stewart ME, Davies BM, Kotter MRN. The Prevalence of asymptomatic and symptomatic spinal cord compression on magnetic resonance imaging: a systematic review and meta-analysis. *Global Spine Journal*. 2020;11:597-607. doi:10.1177/2192568220934496.
3. Fehlings MG, Ibrahim A, Tetreault L, et al. A global perspective on the outcomes of surgical decompression in patients with cervical spondylotic myelopathy. *Spine*. 2015;40:1322-1328. doi:10.1097/brs.0000000000000988.
4. Pope DH, Mowforth OD, Davies BM, Kotter MRN. Diagnostic delays lead to greater disability in degenerative cervical myelopathy and represent a health inequality. *Spine*. 2020;45:368-377. doi:10.1097/brs.00000000000003305.
5. Davies BM, Munro C, Khan DZ, et al. Outcomes of degenerative cervical myelopathy from the perspective of persons living with the condition: findings of a semistructured interview process with partnered internet survey. *Global Spine Journal*. 2020;6:219256822095381. doi:10.1177/2192568220953811.
6. Mowforth OD, Davies BM, Kotter MR. Quality of life among informal caregivers of patients with degenerative cervical myelopathy: cross-sectional questionnaire study. *Interact J Med Res*. 2019;8(4):e12381. doi: 10.2196/12381.
7. Oh T, Lafage R, Lafage V, et al. Comparing quality of life in cervical spondylotic myelopathy with other chronic debilitating diseases using the Short Form Survey 36-Health Survey. *World Neurosurg*. 106; 2017:699-706. doi:10.1016/j.wneu.2016.12.124.
8. Khan DZ, Fitzpatrick SM, Hilton B, McNair AG, Sarewitz E, Davies BM, et al. Prevailing outcome themes reported by people with degenerative cervical myelopathy: focus group study. *JMIR Formative Research*. 2020;5:e18732. doi:10.2196/18732.
9. Davies BM, Khan DZ, Mowforth OD, et al. RE-CODE DCM (research objectives and common data elements for degenerative cervical myelopathy): a consensus process to improve research efficiency in DCM, through establishment of a standardized dataset for clinical research and the definition of the research priorities. *Global Spine Journal*. 2019;9:65S-76S. doi: 10.1177/2192568219832855.
10. Stookey B. Compression of the spinal cord due to ventral extradural cervical chondromas. *Arch Neurol Psychiatr*. 1928;20:275-291. doi:10.1001/archneurpsyc.1928.02210140043003.
11. Peet MM, Echols DH. Herniation of the nucleus pulposus. *Arch Neurol Psychiatr*. 1934;32:924-932. doi:10.1001/archneurpsyc.1934.02250110012002.
12. Badhiwala JH, Ahuja CS, Akbar MA, et al. Degenerative cervical myelopathy - update and future directions. *Nat Rev Neurol*. 2020;16:108-124. doi:10.1038/s41582-019-0303-0.
13. Nouri A, Tetreault L, Singh A, Karadimas SK, Fehlings MG. Degenerative cervical myelopathy. *Spine*. 2015;40:E675-E693. doi:10.1097/brs.0000000000000913.
14. Brain WR, Northfield D, Wilkinson M. The neurological manifestations of cervical spondylosis. *Brain*. 1952;75:187-225. doi:10.1093/brain/75.2.187.
15. Ito T, Oyanagi K, Takahashi H, Takahashi HE, Ikuta F. Cervical Spondylotic Myelopathy. *Spine*. 1996;21:827-833.
16. Karadimas SK, Gatzounis G, Fehlings MG. Pathobiology of cervical spondylotic myelopathy. *European Spine Journal and the European Section of the Cervical Spine Research Society*. 2015;24(suppl 2):132-138. doi:10.1007/s00586-014-3264-4.
17. Akter F, Yu X, Qin X, Yao S, et al. The pathophysiology of degenerative cervical myelopathy and the physiology of recovery following decompression. *Front Neurosci*. 2020;14:550. doi:10.3389/fnins.2020.00138.
18. Karadimas SK, Moon ES, Yu W-R, et al. A novel experimental model of cervical spondylotic myelopathy (CSM) to facilitate translational research. *Neurobiol Dis*. 2013;54:43-58. doi:10.1016/j.nbd.2013.02.013.
19. Dhillon RS, Parker J, Syed YA, et al. Axonal plasticity underpins the functional recovery following surgical decompression in a rat model of cervical spondylotic myelopathy. *Acta neuropathologica communications*. 2016;4:89. doi:10.1186/s40478-016-0359-7.
20. Yu WR, Liu T, Kiehl T-R, Fehlings MG. Human neuropathological and animal model evidence supporting a role for fas-mediated apoptosis and inflammation in cervical spondylotic myelopathy. *Brain*. 2011;134:1277-1292. doi:10.1093/brain/awr054.
21. Karadimas S, Gialeli C, Klironomos G, et al. The role of oligodendrocytes in the molecular pathobiology and potential molecular treatment of cervical spondylotic myelopathy. *Curr Med Chem*. 2010;17:1048-1058. doi:10.2174/092986710790820598.
22. Shingu H, Kimura I, Nasu Y, et al. Microangiographic study of spinal cord injury and myelopathy. *Spinal Cord*. 1989;27:182-189. doi:10.1038/sc.1989.27.
23. Murakami N, Muroga T, Sobue I. Cervical myelopathy due to ossification of the posterior longitudinal ligament. *Arch Neurol*. 1978;35:33-36. doi:10.1001/archneur.1978.00500250037008.
24. Bohlman HH, Emery SE. The pathophysiology of cervical spondylosis and myelopathy. *Spine*. 1988;13:843-846. doi:10.1097/00007632-198807000-00025.
25. PAYNE EE, Spillane JD. The cervical spine an anatomicopathological study of 70 specimens (using a special technique) with particular reference to the problem of cervical spondylosis. *Brain*. 1957;80:571-596. doi:10.1093/brain/80.4.571.
26. Hirai T, Uchida K, Nakajima H, et al. The prevalence and phenotype of activated microglia/macrophages within the spinal cord of the hyperostotic mouse (twy/twy) changes in response to chronic progressive spinal cord compression: implications for human cervical compressive myelopathy. *PLoS One*. 2013;8:e64528. doi:10.1371/journal.pone.0064528.
27. Nouri A, Martin AR, Tetreault L, et al. MRI analysis of the combined prospectively collected aospine north America and international data. *Spine*. 2017;42:1058-1067. doi:10.1097/brs.0000000000001981.

28. Hilton B, Tempest-Mitchell J, Davies BM, et al. Cord compression defined by MRI is the driving factor behind the decision to operate in degenerative cervical myelopathy despite poor correlation with disease severity. *PLoS One*. 2019;14:e0226020. doi:10.1371/journal.pone.0226020.
29. Fehlings MG, Tetreault LA, Riew KD, et al. A clinical practice guideline for the management of patients with degenerative cervical myelopathy: recommendations for patients with mild, moderate, and severe disease and nonmyelopathic patients with evidence of cord compression. *Global Spine Journal*. 2017;7:70S-83S. doi:10.1177/2192568217701914.
30. Tempest-Mitchell J, Hilton B, Davies BM, Nouri A, Hutchinson PJ, Scoffings DJ, et al. A comparison of radiological descriptions of spinal cord compression with quantitative measures, and their role in non-specialist clinical management. *PLoS One*. 2019;14:e0219380. doi:10.1371/journal.pone.0219380.
31. Nouri A, Tetreault L, Côté P, Zamorano JJ, Dalzell K, Fehlings MG. Does magnetic resonance imaging improve the predictive performance of a validated clinical prediction rule developed to evaluate surgical outcome in patients with degenerative cervical myelopathy? *Spine*. 2015;40:1092-1100. doi:10.1097/brs.0000000000000919.
32. Wilson JR, Barry S, Fischer DJ, et al. Frequency, timing, and predictors of neurological dysfunction in the nonmyelopathic patient with cervical spinal cord compression, canal stenosis, and/or ossification of the posterior longitudinal ligament. *Spine*. 2013;38:S37-S54. doi:10.1097/brs.0b013e3182a7f2e7.
33. Badhiwala JH, Witiw CD, Nassiri F, et al. Patient phenotypes associated with outcome following surgery for mild degenerative cervical myelopathy: a principal component regression analysis. *Spine J*. 2018;18:2220-2231. doi:10.1016/j.spinee.2018.05.009.
34. Kadanka Z, Adamova B, Kerkovsky M, et al. Predictors of symptomatic myelopathy in degenerative cervical spinal cord compression. *Brain and behavior*. 2017;7:e00797. doi:10.1002/brb3.797.
35. Martin AR, De Leener B, Cohen-Adad J, et al. Clinically feasible microstructural mri to quantify cervical spinal cord tissue injury using dti, mt, and T2\*-weighted imaging: assessment of normative data and reliability. *Am J Neuroradiol*. 2017;38:1257-1265. doi:10.3174/ajnr.a5163.
36. Kovalova I, Kerkovsky M, Kadanka Z, et al. Prevalence and imaging characteristics of nonmyelopathic and myelopathic spondylotic cervical cord compression. *Spine*. 2016;41:1908-1916. doi:10.1097/brs.0000000000001842.
37. Rhee J, Tetreault LA, Chapman JR, et al. Nonoperative versus operative management for the treatment degenerative cervical myelopathy: an updated systematic review. *Global Spine Journal*. 2017;7:35S-41S. doi:10.1177/2192568217703083.
38. Badhiwala JH, Wilson JR. The natural history of degenerative cervical myelopathy. *Neurosurg Clin*. 2018;29:21-32. doi:10.1016/j.nec.2017.09.002.
39. Tetreault LA, Karadimas S, Wilson JR, et al. The natural history of degenerative cervical myelopathy and the rate of hospitalization following spinal cord injury: an updated systematic review. *Global Spine Journal*. 2017;7:28S-34S. doi:10.1177/2192568217700396.
40. Martin AR, De Leener B, Cohen-Adad J, et al. Can microstructural MRI detect subclinical tissue injury in subjects with asymptomatic cervical spinal cord compression? A prospective cohort study. *BMJ open*. 2018;8:e019809. doi:10.1136/bmjopen-2017-019809.
41. Cui L, Kong C, Chen X, Liu Y, Zhang Y, Guan Y. Changes in diffusion tensor imaging indices of the lumbosacral enlargement correlate with cervical spinal cord changes and clinical assessment in patients with cervical spondylotic myelopathy. *Clin Neurol Neurosurg*. 2019;186:105282. doi:10.1016/j.clineuro.2019.02.014.
42. Chen X, Kong C, Feng S, et al. Magnetic resonance diffusion tensor imaging of cervical spinal cord and lumbosacral enlargement in patients with cervical spondylotic myelopathy. *J Magn Reson Imag*. 2016;43:1484-1491. doi:10.1002/jmri.25109.
43. Shabani S, Kaushal M, Budde MD, Wang MC, Kurpad SN. Diffusion tensor imaging in cervical spondylotic myelopathy: a review. *J Neurosurg Spine*. 2020;33(1):65-72. doi:10.3171/2019.12.spine191158.
44. Grabher P, Mohammadi S, David G, Freund P. Neurodegeneration in the spinal ventral horn prior to motor impairment in cervical spondylotic myelopathy. *J Neurotrauma*. 2017;34:2329-2334. doi:10.1089/neu.2017.4980.
45. Grabher P, Mohammadi S, Trachsler A, et al. Voxel-based analysis of grey and white matter degeneration in cervical spondylotic myelopathy. *Sci Rep*. 2016;6:24636. EP-. doi:10.1038/srep24636.
46. David G, Mohammadi S, Martin AR, et al. Traumatic and nontraumatic spinal cord injury: pathological insights from neuroimaging. *Nat Rev Neurol*. 2019;15:718-731. doi:10.1038/s41582-019-0270-5.
47. Lindberg PG, Sanchez K, Ozcan F, et al. Correlation of force control with regional spinal DTI in patients with cervical spondylosis without signs of spinal cord injury on conventional MRI. *Eur Radiol*. 2016;26:733-742. doi:10.1007/s00330-015-3876-z.
48. Xu N, Wang S, Yuan H, Liu X, Liu Z. Does dynamic supine magnetic resonance imaging improve the diagnostic accuracy of cervical spondylotic myelopathy? A review of the current evidence. *World Neurosurgery*. 2017;100:474-479. doi:10.1016/j.wneu.2017.01.047.
49. Ost K, Jacobs WB, Evaniew N, Cohen-Adad J, Anderson D, Cadotte DW. Spinal cord morphology in degenerative cervical myelopathy patients; assessing key morphological characteristics using machine vision tools. *J Clin Med*. 2021;10:892. doi:10.3390/jcm10040892.
50. Bartlett RD, Choi D, Phillips JB. Biomechanical properties of the spinal cord: implications for tissue engineering and clinical translation. *Regenerative medicine*. 2016;11:659-673. doi:10.2217/rme-2016-0065.

51. Mercier JP, Zambelli G, Kurz W. Tensile behaviour of materials. In: Mercier JP, Zambelli G, Kurz W, eds. *Introduction to Materials Science*. Paris; New York: Elsevier; 2002:261-277. doi:10.1016/b978-2-84299-286-6.50017-2.
52. Hučko B, Jančo R. *Introduction to Mechanics of Materials: Part I*. Bookboon; 2013. <https://www.arma.org.au/wp-content/uploads/2017/03/introduction-to-mechanics-of-materials-part-i.pdf>. accessed Mar 18, 2021
53. Iowa State University. *Nondestructive Evaluation Physics: Materials*. Ames, IA: Iowa State University. <https://www.nde-ed.org/Physics/Materials/index.xhtml>. accessed Mar 18, 2021.
54. Bilston LE, Meaney DF. *The Development of a Physical Model to Measure Strain in a Surrogate Spinal Cord during Hyperflexion and Hyperextension*. Switzerland International Research Council on the Biomechanics of Injury; 1993.
55. Yang KH. *Chapter 5 - Material Laws and Properties*. Academic Press; 2018:231-256. doi:10.1016/b978-0-12-809831-8.00005-2.
56. Molnar K, Labouesse M. The plastic cell: mechanical deformation of cells and tissues. *Open Biology*. 2021;11:210006. doi:10.1098/rsob.210006.
57. Harada A, Mimatsu K. Postoperative changes in the spinal cord in cervical myelopathy demonstrated by magnetic resonance imaging. *Spine*. 1992;17:1275-1280. doi:10.1097/00007632-199211000-00003.
58. Wolf K, Reiser M, Beltrán SF, et al. Focal cervical spinal stenosis causes mechanical strain on the entire cervical spinal cord tissue - A prospective controlled, matched-pair analysis based on phase-contrast MRI. *Neuroimage: Clinical*. 2021;30:102580. doi:10.1016/j.nicl.2021.102580.
59. Hupp M, Vallotton K, Brockmann C, et al. Segmental differences of cervical spinal cord motion: advancing from confounders to a diagnostic tool. *Sci Rep*. 2019;9:7415. doi:10.1038/s41598-019-43908-x.
60. Hupp M, Pfender N, Vallotton K, Rosner J, Friedl S, Zipser CM, et al. The restless spinal cord in degenerative cervical myelopathy. *Am J Neuroradiol*. 2021;42:597-609. doi:10.3174/ajnr.a6958.
61. Winkhofer S, Schoth F, Stolzmann P, Krings T, Mull M, Wiesmann M, et al. Spinal cord motion: influence of respiration and cardiac cycle. *Rofö*. 2014;186:1016-1021. doi:10.1055/s-0034-1366429.
62. Mikulis DJ, Wood ML, Zerdoner OA, Poncelet BP Oscillatory motion of the normal cervical spinal cord. *Radiology*. 1994;192:117-121. doi:10.1148/radiology.192.1.8208922.
63. Kharbada HS, Alsop DC, Anderson AW, Filardo G, Hackney DB. Effects of cord motion on diffusion imaging of the spinal cord. *Magn Reson Med*. 2006;56:334-339. doi:10.1002/mrm.20959.
64. Wolf K, Krafft AJ, Egger K, et al. Assessment of spinal cord motion as a new diagnostic MRI-parameter in cervical spinal canal stenosis: study protocol on a prospective longitudinal trial. *J Orthop Surg Res*. 2019;14:321-327. doi:10.1186/s13018-019-1381-9.
65. Stoltmann HF, Blackwood W. An anatomical study of the role of the dentate ligaments in the cervical spinal canal. *J Neurosurg*. 1966;24:43-46. doi:10.3171/jns.1966.24.1.0043.
66. Ranger MRB, Irwin GJ, Bunbury KM, Peutrell JM. Changing body position alters the location of the spinal cord within the vertebral canal: a magnetic resonance imaging study. *Br J Anaesth*. 2008;101:804-809. doi:10.1093/bja/aen295.
67. Witkamp TD, Vandertop WP, Beek FJA, Notermans NC, Gooskens RHJM, van Waes PFGM. Medullary cone movement in subjects with a normal spinal cord and in patients with a tethered spinal cord. *Radiology*. 2001;220:208-212. doi:10.1148/radiology.220.1.r01j106208.
68. Stamates MM, Frim DM, Yang CW, Katzman GL, Ali S. Magnetic resonance imaging in the prone position and the diagnosis of tethered spinal cord. *J Neurosurg Pediatr*. 2018;21:4-10. doi:10.3171/2017.3.peds16596.
69. Endo K, Suzuki H, Nishimura H, Tanaka H, Shishido T, Yamamoto K. Kinematic analysis of the cervical cord and cervical canal by dynamic neck motion. *Asian Spine Journal*. 2014;8:747-752. doi:10.4184/asj.2014.8.6.747.
70. Harrison DE, Cailliet R, Harrison DD, Troyanovich SJ, Harrison SO. A review of biomechanics of the central nervous system-Part I: spinal canal deformations resulting from changes in posture. *J Manipulative Physiol Therapeut*. 1999;22:227-234. doi:10.1016/s0161-4754(99)70049-7.
71. Kuwazawa Y, Pope MH, Bashir W, Takahashi K, Smith FW. The length of the cervical cord: effects of postural changes in healthy volunteers using positional magnetic resonance imaging. *Spine*. 2006;31:E579-E583. doi:10.1097/01.brs.0000229228.62627.75.
72. Smith CG. Changes in length and position of the segments of the spinal cord with changes in posture in the monkey. *Radiology*. 1956;66:259-266. doi:10.1148/66.2.259.
73. Tykocki T, du Plessis J, Wynne-Jones G. Analysis of morphometric parameters in cervical canal stenosis on neutral and dynamic magnetic resonance imaging. *World neurosurgery*. 2018;114:e317-e322. doi:10.1016/j.wneu.2018.02.179.
74. Breig A, Turnbull I, Hassler O. Effects of mechanical stresses on the spinal cord in cervical spondylosis. *J Neurosurg*. 1966;25:45-56. doi:10.3171/jns.1966.25.1.0045.
75. Kroeker SG, Morley PL, Jones CF, Bilston LE, Cripton PA. The development of an improved physical surrogate model of the human spinal cord-Tension and transverse compression. *J Biomech*. 2009;42:878-883. doi:10.1016/j.jbiomech.2009.01.036.
76. Henderson FC, Geddes JF, Vaccaro AR, Woodard E, Berry KJ, Benzel EC. Stretch-associated injury in cervical spondylotic myelopathy: new concept and review. *Neurosurgery*. 2005;56:1101-1113. -discussion 1101-113.
77. Stoner KE, Abode-Iyamah KO, Magnotta VA, Howard MA, Grosland NM. Measurement of in vivo spinal cord displacement and strain fields of healthy and myelopathic cervical spinal cord. *J Neurosurg Spine*. 2019;31:53-59. doi:10.3171/2018.12.spine18989.

78. Liu S, Lafage R, Smith JS, et al. Impact of dynamic alignment, motion, and center of rotation on myelopathy grade and regional disability in cervical spondylotic myelopathy. *J Neurosurg Spine*. 2015;23:690-700. doi:10.3171/2015.2.spine14414.
79. Henderson FC, Austin C, Benzel E, et al. Neurological and spinal manifestations of the Ehlers-Danlos syndromes. *Am J Med Genet Part C: Seminars in Medical Genetics*. 2017;175:195-211. doi:10.1002/ajmg.c.31549.
80. Nouri A, Kato S, Badhiwala JH, et al. The influence of cervical spondylolisthesis on clinical presentation and surgical outcome in patients with DCM: analysis of a multicenter global cohort of 458 patients. *Global Spine J*. 2020;10:448-455. doi:10.1177/2192568219860827.
81. Gondar R, Nouri A, Jannelli G, Schaller K, Tessitore E. Does spondylolisthesis affect severity and outcome of degenerative cervical myelopathy? A systematic review and meta-analysis. *Global Spine J*. 2020;11:1134-1141. doi:10.1177/2192568220960452.
82. Butler DS. Adverse mechanical tension in the nervous system: a model for assessment and treatment. *Aust J Physiother*. 1989;35:227-238. doi:10.1016/s0004-9514(14)60511-0.
83. Kim YH, Khuyagbaatar B, Kim K. Biomechanical effects of spinal cord compression due to ossification of posterior longitudinal ligament and ligamentum flavum: a finite element analysis. *Med Eng Phys*. 2013;35:1266-1271. doi:10.1016/j.medengphys.2013.01.006.
84. Nishida N, Kanchiku T, Imajo Y, Suzuki H, Yoshida Y, Kato Y, et al. Stress analysis of the cervical spinal cord: Impact of the morphology of spinal cord segments on stress. *The Journal of Spinal Cord Medicine*. 2016;39:327-334. doi:10.1179/2045772315y.0000000012.
85. Hung T-K, Lin H-S, Bunegin L, Albin MS. Mechanical and neurological response of cat spinal cord under static loading. *Surg Neurol*. 1982;17:213-217. doi:10.1016/0090-3019(82)90284-1.
86. Olsson S-E, Stavenborn M, Hoppe F. Dynamic compression of the cervical spinal cord. *Acta Vet Scand*. 1982;23:65-78. doi:10.1186/bf03546823.
87. Ouyang H, Galle B, Li J, Nauman E, Shi R. Biomechanics of spinal cord injury: a multimodal investigation using ex vivo guinea pig spinal cord white matter. *J Neurotrauma*. 2008;25:19-29. doi:10.1089/neu.2007.0340.
88. Karimi A, Shojaei A, Tehrani P. Mechanical properties of the human spinal cord under the compressive loading. *J Chem Neuroanat*. 2017;86:15-18. doi:10.1016/j.jchemneu.2017.07.004.
89. Zhao P, Kong C, Chen X, et al. In vivo diffusion tensor imaging of chronic spinal cord compression: a rat model with special attention to the conus medullaris. *Acta Radiologica*. 2016;57:1531-1539. doi:10.1177/0284185116631185.
90. Freund P, Seif M, Weiskopf N, et al. MRI in traumatic spinal cord injury: from clinical assessment to neuroimaging biomarkers. *Lancet Neurol*. 2019;18:1123-1135. doi:10.1016/s1474-4422(19)30138-3.
91. Konomi T, Fujiyoshi K, Hikishima K, et al. Conditions for quantitative evaluation of injured spinal cord by in vivo diffusion tensor imaging and tractography: Preclinical longitudinal study in common marmosets. *Neuroimage*. 2012;63:1841-1853. doi:10.1016/j.neuroimage.2012.08.040.
92. Overley SC, Kim JS, Gogel BA, Merrill RK, Hecht AC. Tandem spinal stenosis. *JBJS Reviews*. 2017;5:e2. doi:10.2106/jbjs.rvw.17.00007.
93. Vavasour IM, Meyers SM, MacMillan EL, et al. Increased spinal cord movements in cervical spondylotic myelopathy. *Spine J*. 2014;14:2344-2354. doi:10.1016/j.spinee.2014.01.036.
94. Wolf K, Hupp M, Friedl S, et al. In cervical spondylotic myelopathy spinal cord motion is focally increased at the level of stenosis: a controlled cross-sectional study. *Spinal Cord*. 2018;56:769-776. doi:10.1038/s41393-018-0075-1.
95. Jones CF, Kroeker SG, Cripton PA, Hall RM. The effect of cerebrospinal fluid on the biomechanics of spinal cord. *Spine*. 2008;33:E580-E588. doi:10.1097/brs.0b013e31817ecc57.
96. Doh JW, Hwang SC, Yun SM, et al. Acute paraplegia following lumbar puncture in a patient with cervical disc herniation. *Journal of Korean Neurosurgical Society*. 2001.
97. Sebugwawo S, Hoddinott C. Danger of lumbar puncture in spinal cord compression. *Br J Neurosurg*. 1987;1:375-376. doi:10.3109/02688698709023781.
98. Lee J, Paeng SH, Shim YW, Lee WH, Kim ST, Pyo SY. Acute quadriplegia after lumbar puncture in a patient with misdiagnosed cervical myelopathy. *Korean Journal of Neurotrauma*. 2020;16:299-304. doi:10.13004/kjnt.2020.16.e39.
99. Zipser CM, Pfender N, Spirig JM, et al. Study protocol for an observational study of cerebrospinal fluid pressure in patients with degenerative cervical myelopathy undergoing surgical decompression of the spinal cord: the COMP-CORD study. *Bmj Open*. 2020;10:e037332. doi:10.1136/bmjopen-2020-037332.
100. Yamada S, Won DJ, Pezeshkpour G, et al. Pathophysiology of tethered cord syndrome and similar complex disorders. *Neurosurg Focus*. 2007;23(2):E6. doi:10.3171/foc-07/08/e6.
101. Stetler WR, Park P, Sullivan S. Pathophysiology of adult tethered cord syndrome: review of the literature. *Neurosurg Focus*. 2010;29:E2. doi:10.3171/2010.3.focus1080.
102. Fujimoto Y, Oka S, Tanaka N, Nishikawa K, Kawagoe H, Baba I. Pathophysiology and treatment for cervical flexion myelopathy. *Eur Spine J*. 2002;11:276-285. doi:10.1007/s005860100344.
103. Chen CS. Mechanotransduction - a field pulling together? *J Cell Sci*. 2008;121:3285-3292. doi:10.1242/jcs.023507.
104. LaPlaca MC, Prado GR. Neural mechanobiology and neuronal vulnerability to traumatic loading. *J Biomech*. 2010;43:71-78. doi:10.1016/j.jbiomech.2009.09.011.
105. Galbraith JA, Thibault LE, Matteson DR. Mechanical and electrical responses of the squid giant axon to simple elongation. *J Biomech Eng*. 1993;115:13-22. doi:10.1115/1.2895464.
106. Arundine M, Aarts M, Lau A, et al. Vulnerability of central neurons to secondary insults after in vitro mechanical stretch. *J Neurosci*. 2004;24:8106-8123. doi:10.1523/jneurosci.1362-04.2004.
107. LaPlaca MC, Cullen DK, McLoughlin JJ, Cargill RS. High rate shear strain of three-dimensional neural cell cultures: a new



- in vitro traumatic brain injury model. *J Biomech.* 2005;38:1093-1105. doi:10.1016/j.jbiomech.2004.05.032.
108. Gaub BM, Kasuba KC, Mace E, et al. Neurons differentiate magnitude and location of mechanical stimuli. *Proc Natl Acad Sci Unit States Am.* 2020;117:848-856. doi:10.1073/pnas.1909933117.
109. Ahmed WW, Li TC, Rubakhin SS, Chiba A, Sweedler JV, Saif TA. Mechanical tension modulates local and global vesicle dynamics in neurons. *Cell Mol Bioeng.* 2012;5:155-164. doi:10.1007/s12195-012-0223-1.
110. Ayali A. The function of mechanical tension in neuronal and network development. *Integrative Biology.* 2010;2:178-182. doi:10.1039/b927402b.
111. Galle B, Ouyang H, Shi R, Nauman E. Correlations between tissue-level stresses and strains and cellular damage within the guinea pig spinal cord white matter. *J Biomech.* 2007;40:3029-3033. doi:10.1016/j.jbiomech.2007.03.014.
112. Russell CM, Choo AM, Tetzlaff W, Chung T-E, Oxland TR. Maximum principal strain correlates with spinal cord tissue damage in contusion and dislocation injuries in the rat cervical spine. *J Neurotrauma.* 2012;29:1574-1585. doi:10.1089/neu.2011.2225.
113. Al-Habib A, Albakr A, Al Towim A, et al. In vivo assessment of spinal cord elasticity using shear wave ultrasound in dogs. *J Neurosurg Spine.* 2018;29:461-469. doi:10.3171/2018.2.spine171195.
114. Kozai TDY, Jaquins-Gerstl AS, Vazquez AL, Michael AC, Cui XT. Brain tissue responses to neural implants impact signal sensitivity and intervention strategies. *ACS Chem Neurosci.* 2015;6:48-67. doi:10.1021/cn500256e.
115. Ichihara K, Taguchi T, Shimada Y, Sakuramoto I, Kawano S, Kawai S. Gray matter of the bovine cervical spinal cord is mechanically more rigid and fragile than the white matter. *J Neurotrauma.* 2001;18:361-367. doi:10.1089/08977150151071053.
116. Okazaki T, Kanchiku T, Nishida N, et al. Age-related changes of the spinal cord: a biomechanical study. *Experimental and therapeutic medicine.* 2018;15:2824-2829. doi:10.3892/etm.2018.5796.
117. Mattucci S, Speidel J, Liu J, Kwon BK, Tetzlaff W, Oxland TR. Basic biomechanics of spinal cord injury - how injuries happen in people and how animal models have informed our understanding. *Clin BioMech.* 2019;64:58-68. doi:10.1016/j.clinbiomech.2018.03.020.
118. Sharif-Alhoseini M, Khormali M, Rezaei M, et al. Animal models of spinal cord injury: a systematic review. *Spinal Cord.* 2017;55:714-721. doi:10.1038/sc.2016.187.
119. Oakland RJ, Hall RM, Wilcox RK, Barton DC. The biomechanical response of spinal cord tissue to uniaxial loading. *Proc IME H J Eng Med.* 2006;220:489-492. doi:10.1243/09544119jeim135.
120. Patel AA, Spiker WR, Daubs M, Brodke DS, Cannon-Albright LA. Evidence of an inherited predisposition for cervical spondylotic myelopathy. *Spine.* 2012;37:26-29. doi:10.1097/brs.0b013e3182102ede.
121. Mukerji N, Sinar EJ. Identical twins with cervical myelopathy: a case for hereditary cervical spondylosis? *J Neurosurg Spine.* 2007;6:344-349. doi:10.3171/spi.2007.6.4.10.
122. Pope DH, Davies BM, Mowforth OD, Bowden AR, Kotter MRN. Genetics of degenerative cervical myelopathy: a systematic review and meta-analysis of candidate gene studies. *J Clin Med.* 2020;9:282. doi:10.3390/jcm9010282.
123. Setzer M, Hermann E, Seifert V, Marquardt G. Apolipoprotein E gene polymorphism and the risk of cervical myelopathy in patients with chronic spinal cord compression. *Spine.* 2008;33:497-502. doi:10.1097/brs.0b013e3181657cf7.
124. Setzer M, Vrionis FD, Hermann EJ, Seifert V, Marquardt G. Effect of apolipoprotein E genotype on the outcome after anterior cervical decompression and fusion in patients with cervical spondylotic myelopathy. *J Neurosurg Spine.* 2009;11:659-666. doi:10.3171/2009.7.spine08667.
125. Wang D, Liu W, Cao Y, et al. BMP-4 polymorphisms in the susceptibility of cervical spondylotic myelopathy and its outcome after anterior cervical corpectomy and fusion. *Cell Physiol Biochem.* 2013;32:210-217. doi:10.1159/000350137.
126. Wang Z-C, Hou X-W, Shao J, et al. HIF-1 $\alpha$  polymorphism in the susceptibility of cervical spondylotic myelopathy and its outcome after anterior cervical corpectomy and fusion treatment. *PLoS One.* 2014;9:e110862. doi:10.1371/journal.pone.0110862.
127. Wu J, Wu D, Guo K, Yuan F, Ran B. OPN polymorphism is associated with the susceptibility to cervical spondylotic myelopathy and its outcome after anterior cervical corpectomy and fusion. *Cell Physiol Biochem.* 2014;34:565-574. doi:10.1159/000363023.
128. Chang F, Li L, Gao G, et al. Role of Runx2 polymorphisms in risk and prognosis of ossification of posterior longitudinal ligament. *J Clin Lab Anal.* 2017;31:e22068. doi:10.1002/jcla.22068.
129. New PW, Cripps RA, Bonne Lee B. Global maps of non-traumatic spinal cord injury epidemiology: towards a living data repository. *Spinal Cord.* 2014;52:97-109. doi:10.1038/sc.2012.165.
130. Chazono M, Tanaka T, Kumagai Y, Sai T, Marumo K. Ethnic differences in pedicle and bony spinal canal dimensions calculated from computed tomography of the cervical spine: a review of the english-language literature. *Eur Spine J.* 2012;21:1451-1458. doi:10.1007/s00586-012-2295-y.
131. Toki S, Higashino K, Manabe H, et al. Morphometric analysis of subaxial cervical spine with myelopathy: a comparison with the normal population. *Spine Surgery and Related Research.* 2021;5:34-40. doi:10.22603/ssrr.2020-0061.
132. Nouri A, Tetreault L, Nori S, Martin AR, Nater A, Fehlings MG. Congenital cervical spine stenosis in a multicenter global cohort of patients with degenerative cervical myelopathy: an ambispective report based on a magnetic resonance imaging diagnostic criterion. *Neurosurgery.* 2018;83:521-528. doi:10.1093/neuros/nyx521.
133. Lee SE, Chung CK. Risk prediction for development of traumatic cervical spinal cord injury without spinal instability. *Global Spine J.* 2015;5:315-321. doi:10.1055/s-0035-1547526.

134. Fujimori T, Le H, Hu SS, et al. Ossification of the posterior longitudinal ligament of the cervical spine in 3161 patients. *Spine*. 2015;40:E394-E403. doi:10.1097/brs.0000000000000791.
135. Tchkonina T, Kirkland JL. Aging, cell senescence, and chronic disease. *Jama*. 2018;320:1319. doi:10.1001/jama.2018.12440.
136. López-Otín C, Blasco MA, Partridge L, Serrano M, Kroemer G. The hallmarks of aging. *Cell*. 2013;153:1194-1217. doi:10.1016/j.cell.2013.05.039.
137. Grodzinski B, Durham R, Mowforth O, Stubbs D, Kotter MRN, Davies BM. The effect of ageing on presentation, management and outcomes in degenerative cervical myelopathy: a systematic review. *Age Ageing*. 2020;50:705-715. doi:10.1093/ageing/afaa236.
138. Gembruch O, Jabbarli R, Rashidi A, et al. Degenerative cervical myelopathy in higher-aged patients: how do they benefit from surgery? *J Clin Med*. 2019;9:62. doi:10.3390/jcm9010062.
139. Wilson JRF, Badhiwala JH, Jiang F, et al. The impact of older age on functional recovery and quality of life outcomes after surgical decompression for degenerative cervical myelopathy: results from an ambispective, propensity-matched analysis from the CSM-NA and CSM-I international, multi-center studies. *J Clin Med*. 2019;8:1708. doi:10.3390/jcm8101708.
140. Oishi Y, Baratta J, Robertson RT, Steward O. Assessment of factors regulating axon growth between the cortex and spinal cord in organotypic co-cultures: effects of age and neurotrophic factors. *J Neurotrauma*. 2004;21:339-356. doi:10.1089/089771504322972121.
141. Byrne AB, Walradt T, Gardner KE, Hubbert A, Reinke V, Hammarlund M. Insulin/IGF1 signaling inhibits age-dependent axon regeneration. *Neuron*. 2014;81:561-573. doi:10.1016/j.neuron.2013.11.019.
142. Sim FJ, Zhao C, Penderis J, Franklin RJM. The age-related decrease in CNS remyelination efficiency is attributable to an impairment of both oligodendrocyte progenitor recruitment and differentiation. *J Neurosci*. 2002;22:2451-2459. doi:10.1523/jneurosci.22-07-02451.2002.
143. Ito M, Muramatsu R, Kato Y, et al. Age-dependent decline in remyelination capacity is mediated by apelin-APJ signaling. *Nature Aging*. 2021;1:284-294. doi:10.1038/s43587-021-00041-7.
144. Papinutto N, Asteggiano C, Bischof A, et al. Intersubject variability and normalization strategies for spinal cord total cross-sectional and gray matter areas. *J Neuroimaging*. 2020;30:110-118. doi:10.1111/jon.12666.
145. Papinutto N, Schlaeger R, Panara V, et al. Age, gender and normalization covariates for spinal cord gray matter and total cross-sectional areas at cervical and thoracic levels: a 2D phase sensitive inversion recovery imaging study. *PLoS One*. 2015;10:e0118576. doi:10.1371/journal.pone.0118576.
146. Ishikawa M, Matsumoto M, Fujimura Y, Chiba K, Toyama Y. Changes of cervical spinal cord and cervical spinal canal with age in asymptomatic subjects. *Spinal Cord*. 2003;41:159-163. doi:10.1038/sj.sc.3101375.
147. Callaghan MF, Freund P, Draganski B, et al. Widespread age-related differences in the human brain microstructure revealed by quantitative magnetic resonance imaging. *Neurobiol Aging*. 2014;35:1862-1872. doi:10.1016/j.neurobiolaging.2014.02.008.
148. Tanaka Y. Morphological changes of the cervical spinal canal and cord due to aging. *Nihon Seikeigeka Gakkai Zasshi*. 1984;58:873-886.
149. Yasui K, Hashizume Y, Yoshida M, Kameyama T, Sobue G. Age-related morphologic changes of the central canal of the human spinal cord. *Acta Neuropathol*. 1999;97:253-259. doi:10.1007/s004010050982.
150. Sasaki A, Mizutani T, Takasaki M, Yamada S, Mukai M, Ezaki Y. Morphometric study of age-related changes of the spinal cord. *Nippon Ronen Igakkai Zasshi. Japanese Journal of Geriatrics*. 1994;31:462-467. doi:10.3143/geriatrics.31.462.
151. Piekarczyk KM, Bhaskaran S, Sataranatarajan K, et al. Molecular changes associated with spinal cord aging. *GeroScience*. 2020;42:765-784. doi:10.1007/s11357-020-00172-6.
152. Morales FR, Boxer PA, Fung SJ, Chase MH. Basic electrophysiological properties of spinal cord motoneurons during old age in the cat. *Journal of neurophysiology*. 1987;58:180-194. doi:10.1152/jn.1987.58.1.180.
153. Sparrey CJ, Manley GT, Keaveny TM. Effects of white, grey, and pia mater properties on tissue level stresses and strains in the compressed spinal cord. *J Neurotrauma*. 2009;26:585-595. doi:10.1089/neu.2008.0654.
154. Jazwinski SM, Kim S. Examination of the dimensions of biological age. *Front Genet*. 2019;10:263. doi:10.3389/fgene.2019.00263.
155. Bell CG, Lowe R, Adams PD, et al. DNA methylation aging clocks: challenges and recommendations. *Genome Biol*. 2019;20:249. doi:10.1186/s13059-019-1824-y.
156. Tuttle CSL, Waaijer MEC, Slee-Valentijn MS, Stijnen T, Westendorp R, Maier AB. Cellular senescence and chronological age in various human tissues: a systematic review and meta-analysis. *Aging Cell*. 2020;19:e13083. doi:10.1111/acel.13083.
157. Neumann B, Segel M, Chalut KJ, Franklin RJ. Remyelination and ageing: reversing the ravages of time. *Multiple Sclerosis Journal*. 2019;25:1835-1841. doi:10.1177/1352458519884006.
158. Wilson JRF, Badhiwala JH, Moghaddamjou A, Yee A, Wilson JR, Fehlings MG. Frailty is a better predictor than age of mortality and perioperative complications after surgery for degenerative cervical myelopathy: an analysis of 41,369 patients from the NSQIP database 2010-2018. *J Clin Med*. 2020;9:3491. doi:10.3390/jcm9113491.
159. Ellingson BM, Woodworth DC, Leu K, Salamon N, Holly LT. Spinal cord perfusion MR imaging implicates both ischemia and hypoxia in the pathogenesis of cervical spondylosis. *World neurosurgery*. 2019;128:e773-e781. doi:10.1016/j.wneu.2019.04.253.
160. Lee Y-S, Kim K-T, Kwon BK. Hemodynamic management of acute spinal cord injury: a literature review. *Neurospine*. 2021;18(1):7-14. doi:10.14245/ns.2040144.072.

161. Squair JW, Bélanger LM, Tsang A, et al. Spinal cord perfusion pressure predicts neurologic recovery in acute spinal cord injury. *Neurology*. 2017;89:1660-1667. doi:10.1212/wnl.00000000000004519.
162. Senter HJ, Venes JL. Loss of autoregulation and posttraumatic ischemia following experimental spinal cord trauma. *J Neurosurg*. 1979;50:198-206. doi:10.3171/jns.1979.50.2.0198.
163. Saadoun S, Papadopoulos MC. Targeted perfusion therapy in spinal cord trauma. *Neurotherapeutics*. 2020;17:511-521. doi:10.1007/s13311-019-00820-6.
164. Srihari G, Shukla D, Indira Devi B, Sathyaprabha TN. Sub-clinical autonomic nervous system dysfunction in compressive cervical myelopathy. *Spine*. 2011;36:654-659. doi:10.1097/brs.0b013e3181dc9eb2.
165. Radhakrishnan M, Manohar N, Ramesh V, Chakraborti D. Haemodynamic changes during prone positioning in anaesthetised chronic cervical myelopathy patients. *Indian J Anaesth*. 2019;63:212. doi:10.4103/ija.ija\_810\_18.
166. Ong ET-E, Yeo LK-P, Kaliya-Perumal A-K, Oh JY-L. Orthostatic hypotension following cervical spine surgery: prevalence and risk factors. *Global Spine J*. 2020;10:578-582. doi:10.1177/2192568219863805.
167. Kalb S, Zaidi HA, Ribas-Nijkerk JC, et al. Persistent outpatient hypertension is independently associated with spinal cord dysfunction and imaging characteristics of spinal cord damage among patients with cervical spondylosis. *World Neurosurgery*. 2015;84:351-357. doi:10.1016/j.wneu.2015.03.030.
168. Hukuda S, Ogata M, Katsuura A. Experimental study on acute aggravating factors of cervical spondylotic myelopathy. *Spine*. 1988;13:15-20. doi:10.1097/00007632-198801000-00005.
169. Machino M, Ando K, Kobayashi K, et al. Prediction of outcome following laminoplasty of cervical spondylotic myelopathy: focus on the minimum clinically important difference. *J Clin Neurosci*. 2020;81:321-327. doi:10.1016/j.jocn.2020.09.065.
170. Perdomo-Pantoja A, Chara A, Casaos J, et al. 12. Angiotensin-II type-1 receptor blockade decreased T2 signal intensity in spinal cord compression in symptomatic cervical spondylotic myelopathy. *Spine J*. 2020;19:S6. doi:10.1016/j.spinee.2019.05.025.
171. Tetreault LA, Côté P, Kopjar B, Arnold P, Fehlings MG. A clinical prediction model to assess surgical outcome in patients with cervical spondylotic myelopathy: internal and external validations using the prospective multicenter AOSpine North American and international datasets of 743 patients. *Spine J*. 2015;15:388-397. doi:10.1016/j.spinee.2014.12.145.
172. Zalewski NL, Rabinstein AA, Krecke KN, et al. Characteristics of spontaneous spinal cord infarction and proposed diagnostic criteria. *JAMA Neurology*. 2019;76:56. doi:10.1001/jamaneurol.2018.2734.
173. Wang Y, Hashizume Y, Inagaki T. Autopsy findings of atheromatous embolism to the spinal cord. *Nippon Ronen Igakkai Zasshi. Japanese Journal of Geriatrics*. 1996;33:935-939. doi:10.3143/geriatrics.33.935.
174. Lin S-Y, Chen D-C, Lin C-L, et al. Risk of acute coronary syndrome in patients with cervical spondylosis. *Atherosclerosis*. 2018;271:136-141. doi:10.1016/j.atherosclerosis.2018.02.029.
175. Itoki K, Kurokawa R, Shingo T, Kim P. Effect of myoarchitectonic spinolaminoplasty on concurrent hypertension in patients with cervical spondylotic myelopathy. *Neurospine*. 2018;15:77-85. doi:10.14245/ns.1836020.010.
176. Yang L, Yang C, Pang X, et al. Cervical decompression surgery for cervical spondylotic myelopathy and concomitant hypertension. *Spine*. 2017;42:903-908. doi:10.1097/brs.0000000000001941.
177. Li Z-Q, Zhao Y-P, Jia W-Y, et al. Surgical treatment of cervical spondylotic myelopathy associated hypertension—a retrospective study of 309 patients. *PLoS One*. 2015;10:e0133828. doi:10.1371/journal.pone.0133828.
178. Stręk P, Reroń E, Maga P, Modrzejewski M, Szybist N. A possible correlation between vertebral artery insufficiency and degenerative changes in the cervical spine. *Eur Arch Oto-Rhino-Laryngol*. 1998;255:437-440. doi:10.1007/s004050050094.
179. Liu H, Wang H-B, Wu L, et al. Effects of decompressive cervical surgery on blood pressure in cervical spondylosis patients with hypertension: a time series cohort study. *BMC Surg*. 2016;16:2. doi:10.1186/s12893-015-0117-y.
180. Lin S-Y, Hsu W-H, Lin C-C, et al. Association of arrhythmia in patients with cervical spondylosis: a nationwide population-based cohort study. *J Clin Med*. 2018;7:236. doi:10.3390/jcm7090236.
181. Nouri A, Patel K, Montejo J, et al. The role of vitamin B12 in the management and optimization of treatment in patients with degenerative cervical myelopathy. *Global Spine J*. 2019;9:331-337. doi:10.1177/2192568218758633.
182. Nouri A, Matur A, Pennington Z, et al. Prevalence of anemia and its relationship with neurological status in patients undergoing surgery for degenerative cervical myelopathy and radiculopathy: a retrospective study of 2 spine centers. *J Clin Neurosci*. 2020;72:252-257. doi:10.1016/j.jocn.2019.11.027.
183. Allam AFA, Abotakia TAA, Koptan W. Role of cerebrolysin in cervical spondylotic myelopathy patients: a prospective randomized study. *Spine J*. 2018;18:1136-1142. doi:10.1016/j.spinee.2017.11.002.
184. Carabotti M, Scirocco A, Maselli MA, Severi C. The gut-brain axis: interactions between enteric microbiota, central and enteric nervous systems. *Ann Gastroenterol*. 2015;28:203-209.
185. Cryan JF, O'Riordan KJ, Sandhu K, Peterson V, Dinan TG. The gut microbiome in neurological disorders. *Lancet Neurol*. 2020;19:179-194. doi:10.1016/s1474-4422(19)30356-4.
186. Jogia T, Ruitenberg MJ. Traumatic spinal cord injury and the gut microbiota: current insights and future challenges. *Front Immunol*. 2020;11:704. doi:10.3389/fimmu.2020.00704.
187. Fouad K, Popovich PG, Kopp MA, Schwab JM. The neuroanatomical-functional paradox in spinal cord injury. *Nat Rev Neurol*. 2021;17:53-62. doi:10.1038/s41582-020-00436-x.
188. Li C, Xu MM, Wang K, Adler AJ, Vella AT, Zhou B. Macrophage polarization and meta-inflammation. *Transl Res*. 2018;191:29-44. doi:10.1016/j.trsl.2017.10.004.

189. Ito K, Matsuyama Y, Yukawa Y, Kato F, Ishiguro N. Analysis of Interleukin-8, Interleukin-10, and tumor necrosis factor- $\alpha$  in the cerebrospinal fluid of patients with cervical spondylotic myelopathy. *J Spinal Disord Tech*. 2008;21:145-147. doi:10.1097/bsd.0b013e31806458b3.
190. Nagashima H, Morio Y, Yamane K, Nanjo Y, Teshima R. Tumor necrosis factor- $\alpha$ , interleukin-1 $\beta$ , and interleukin-6 in the cerebrospinal fluid of patients with cervical myelopathy and lumbar radiculopathy. *Eur Spine J*. 2009;18:1946-1950. doi:10.1007/s00586-009-1069-7.
191. Du S, Sun Y, Zhao B. Interleukin-6 serum levels are elevated in individuals with degenerative cervical myelopathy and are correlated with symptom severity. *Med Sci Mon Int Med J Exp Clin Res*. 2018;24:7405-7413. doi:10.12659/msm.912868.
192. Laliberte AM, Karadimas SK, Vidal PM, Satkunendrarajah K, Fehlings MG. Mir21 modulates inflammation and sensorimotor deficits in cervical myelopathy: data from humans and animal models. *Brain Communications*. 2021;3:fcaa234. doi:10.1093/braincomms/fcaa234.
193. Nouri A, Badhiwala JH, Kato S, et al. The relationship between gastrointestinal comorbidities, clinical presentation and surgical outcome in patients with DCM: analysis of a global cohort. *J Clin Med*. 2020;9:624. doi:10.3390/jcm9030624.
194. Wylie GR, Chiaravalloti ND, Weber E, Genova HM, Dyson-Hudson TA, Wecht JM. The neural mechanisms underlying processing speed deficits in individuals who have sustained a spinal cord injury: a pilot study. *Brain Topogr*. 2020;33:776-784. doi:10.1007/s10548-020-00798-x.
195. Holly LT, Dong Y, Albistegui-DuBois R, Marehbian J, Dobkin B. Cortical reorganization in patients with cervical spondylotic myelopathy. *J Neurosurg Spine*. 2007;6:544-551. doi:10.3171/spi.2007.6.6.5.
196. Kuang C, Zha Y, Liu C, Chen J. Altered topological properties of brain structural covariance networks in patients with cervical spondylotic myelopathy. *Front Hum Neurosci*. 2020;14:364. doi:10.3389/fnhum.2020.00364.
197. Wang C, Laiwalla A, Salamon N, Ellingson BM, Holly LT. Compensatory brainstem functional and structural connectivity in patients with degenerative cervical myelopathy by probabilistic tractography and functional MRI. *Brain Research*. 2020;1749:147129. doi:10.1016/j.brainres.2020.147129.
198. Takenaka S, Kan S, Seymour B, et al. Towards prognostic functional brain biomarkers for cervical myelopathy: a resting-state fMRI study. *Sci Rep*. 2019;9:10456. doi:10.1038/s41598-019-46859-5.
199. Liu X, Qian W, Jin R, et al. Amplitude of low frequency fluctuation (ALFF) in the cervical spinal cord with stenosis: a resting state fmri study. *PLoS One*. 2016;11:e0167279. doi:10.1371/journal.pone.0167279.
200. Tan Y, Zhou F, Wu L, et al. Alteration of regional homogeneity within the sensorimotor network after spinal cord decompression in cervical spondylotic myelopathy: a resting-state fMRI study. *BioMed Research International*. 2015;2015:1-6. doi:10.1155/2015/647958.
201. Chen Z, Zhao R, Wang Q, et al. Functional connectivity changes of the visual cortex in the cervical spondylotic myelopathy patients. *Spine*. 2020;45:E272-E279. doi:10.1097/brs.0000000000003245.
202. Woodworth DC, Holly LT, Mayer EA, Salamon N, Ellingson BM. Alterations in cortical thickness and subcortical volume are associated with neurological symptoms and neck pain in patients with cervical spondylosis. *Neurosurgery*. 2019;84:588-598. doi:10.1093/neuros/nyy066.
203. Zdunczyk A, Schwarzer V, Mikhailov M, et al. The corticospinal reserve capacity: reorganization of motor area and excitability as a novel pathophysiological concept in cervical myelopathy. *Neurosurgery*. 2017;83:810-818. doi:10.1093/neuros/nyx437.
204. Chen Z, Wang Q, Liang M, et al. Visual cortex neural activity alteration in cervical spondylotic myelopathy patients: a resting-state fMRI study. *Neuroradiology*. 2018;60:921-932. doi:10.1007/s00234-018-2061-x.
205. Peng X, Tan Y, He L, Ou Y. Alterations of functional connectivity between thalamus and cortex before and after decompression in cervical spondylotic myelopathy patients: a resting-state functional MRI study. *Neuroreport*. 2020;31:365-371. doi:10.1097/wnr.0000000000001346.
206. Mitoma H, Buffo A, Gelfo F, Guell X, Fucà E, Kakei S, et al. Consensus paper. Cerebellar reserve: from cerebellar physiology to cerebellar disorders. *Cerebellum*. 2020;19:131-153. doi:10.1007/s12311-019-01091-9.
207. Montine TJ, Cholerton BA, Corrada MM, et al. Concepts for brain aging: resistance, resilience, reserve, and compensation. *Alzheimer's Res Ther*. 2019;11:22-23. doi:10.1186/s13195-019-0479-y.
208. Witiw CD, Mathieu F, Nouri A, Fehlings MG. Clinicoradiographic discordance: an evidence-based commentary on the management of degenerative cervical spinal cord compression in the absence of symptoms or with only mild symptoms of myelopathy. *Global Spine Journal*. 2017;8:527-534. doi:10.1177/2192568217745519.
209. Nouri A, Cheng JS, Davies B, Kotter M, Schaller K, Tessitore E. Degenerative cervical myelopathy: a brief review of past perspectives, present developments, and future directions. *J Clin Med*. 2020;9:535. doi:10.3390/jcm9020535.
210. Davis L. *Body Physics: Motion to Metabolism (Deformation of Tissues)*. Chapter 52. Portland, OR: Open Oregon Educational Resources. <https://openoregon.pressbooks.pub/bodyphysics/chapter/elasticity-and-hookes-law/> accessed May 4, 2021.