

# UC Davis

## Dermatology Online Journal

### Title

Neutrophilic dermatosis of the dorsal hands in an elderly man

### Permalink

<https://escholarship.org/uc/item/786522rg>

### Journal

Dermatology Online Journal, 22(2)

### Authors

Gonzalez, Andres  
Vaziri, Sasha  
Brandt, John C  
[et al.](#)

### Publication Date

2016

### DOI

10.5070/D3222030096

### Copyright Information

Copyright 2016 by the author(s). This work is made available under the terms of a Creative Commons Attribution-NonCommercial-NoDerivatives License, available at <https://creativecommons.org/licenses/by-nc-nd/4.0/>

Peer reviewed

**Case presentation**

**Neutrophilic dermatosis of the dorsal hands in an elderly man**

**Andres Gonzalez MD<sup>1</sup>, Sasha Vaziri MD<sup>1</sup>, John C Brandt MD<sup>2</sup>, William Steffes MD<sup>3</sup>, Yaseen Perbtani DO<sup>2</sup>**

**Dermatology Online Journal 22 (2): 11**

<sup>1</sup>University of Florida College of Medicine

<sup>2</sup>University of Florida College of Medicine, Department of Medicine

<sup>3</sup>University of Florida College of Medicine, Department of Dermatology

**Correspondence:**

Andres Gonzalez  
College of Medicine, University of Florida  
1600 SW Archer Road  
Gainesville, FL 32610-0284  
Phone: 786.970.1511  
andresgo@ufl.edu

---

**Abstract**

Neutrophilic dermatosis of the dorsal hands is an uncommon variant of Sweet syndrome. We report a case of a 72-year-old man, recently diagnosed with stage II lung adenocarcinoma, who presented to the clinic with a 14-day history of painful macules that progressed to bullae on the dorsal surface of his hands; decreased range of motion was noted. Examination revealed bilateral small, tender violaceous vesicopustules admixed with larger tense hemorrhagic pus-filled bullae on the dorsal aspect of his hands. Biopsy demonstrated changes consistent with neutrophilic dermatosis of the dorsal hands. The patient had been diagnosed with ulcerative colitis in the 1970s, although the condition was asymptomatic at the time of presentation. Treatment with prednisone 60 mg daily resulted in significant improvement by the next day. This regimen was continued for two weeks and was followed by a 6-week steroid taper. After a review of the approximate 75 cases currently reported, we also discuss the recurrence rate of NDDH of approximately 10%.

**Keywords:** neutrophilic dermatosis, Sweet's syndrome, clinical dermatology

**Introduction**

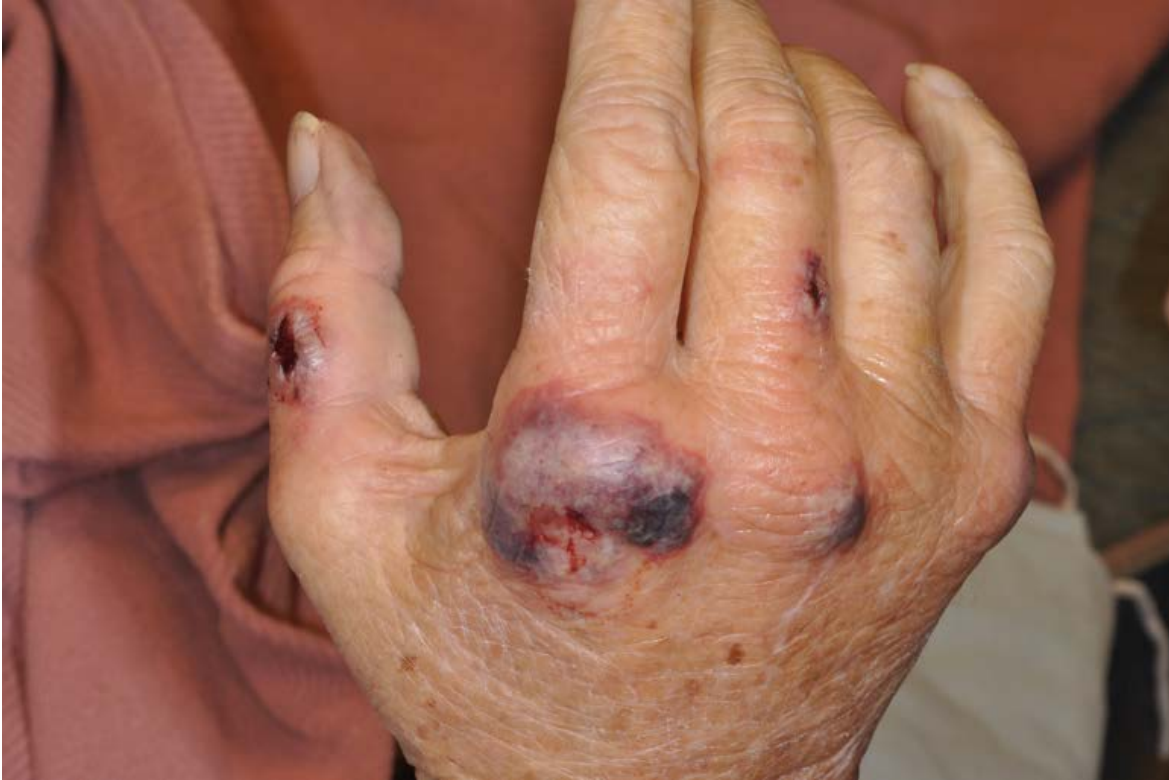Neutrophilic dermatosis of the dorsal hands (NDDH) is considered an uncommon variant of Sweet syndrome and was first described in 1995 in a case series of six patients [1]. We report the case of a 72-year-old male with a history of lung neoplasia and ulcerative colitis who presented with a likely multifactorial cause of NDDH.

**Case synopsis**

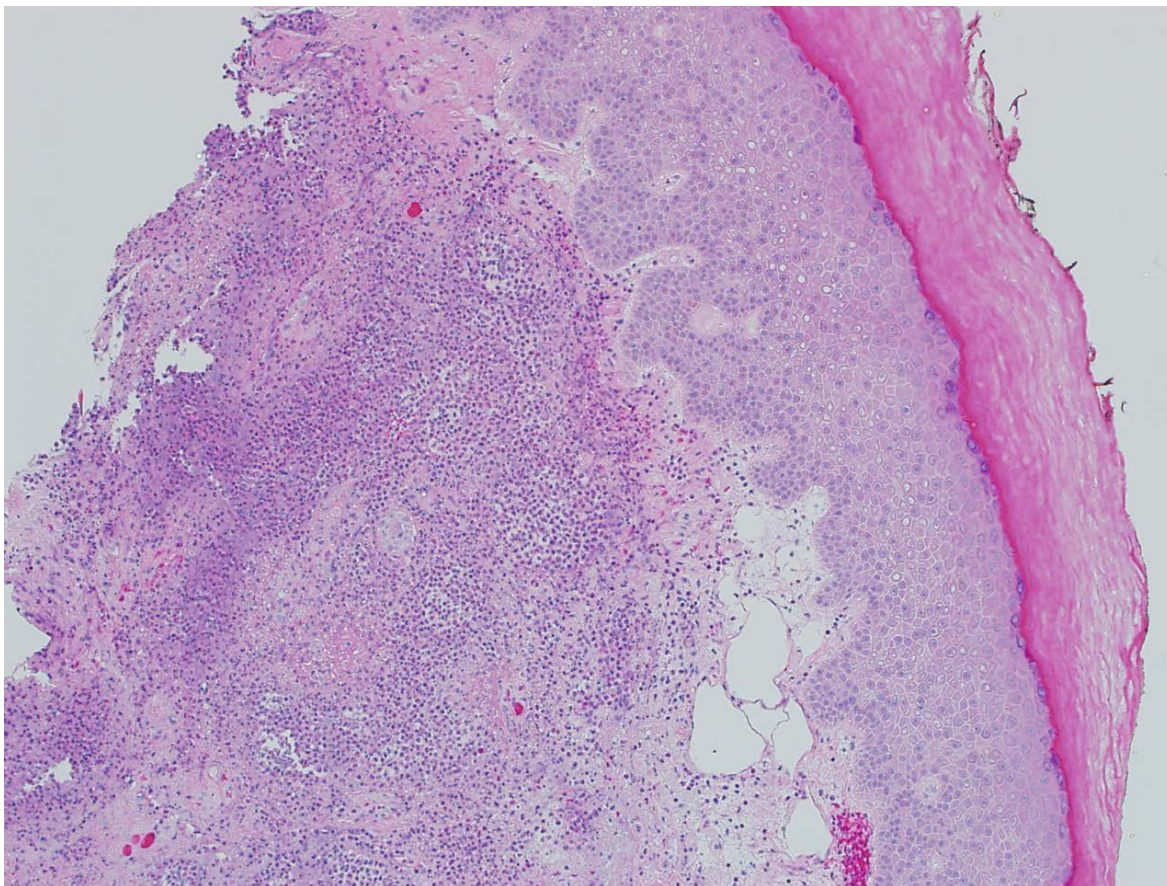
A 72-year old man with a history of chronic obstructive pulmonary disease (COPD), recently diagnosed stage II lung adenocarcinoma, and ulcerative colitis presented to the emergency department with a 14-day history of painful erythematous macules that progressed to well demarcated hemorrhagic and pustular bullae on the dorsal surface of his hands over the 5 days prior to admis-

sion. The patient underwent a lobectomy for his lung adenocarcinoma 34 days prior to this admission. His recovery was complicated by the presence of a clinically stable left pleural effusion, which was being treated with oral levofloxacin at the time of presentation. Of note, his ulcerative colitis was currently asymptomatic. He had never been on immunomodulator therapy nor had he been treated surgically for the condition.

Examination revealed bilateral small tender violaceous vesicopustules admixed with larger tense hemorrhagic and pus-filled bullae located primarily on the dorsal surface of his hands and extending to the forearm and palm (Figure 1). His hands were edematous with diminished range of motion. Labs revealed a neutrophilic leukocytosis (white blood cell count  $16.6 \text{ k/mm}^3$ ). Culture and gram stain of the hand lesions returned negative. Punch biopsies of the lesions were performed and revealed papillary dermal edema with a heavy neutrophilic dermal infiltrate; mild leukocytoclasia was also present (Figure 2). The histopathological findings along with negative culture and gram stain led to a diagnosis of neutrophilic dermatosis of the dorsal hands (NDDH).



**Figure 1.** Violaceous vesicopustules with larger tense hemorrhagic and pus-filled bullae



**Figure 2.** Papillary dermal edema with a heavy neutrophilic dermal infiltrate (H&E, x40)

The patient was started on prednisone 60 mg daily by mouth owing to high suspicion of an inflammatory process. Intravenous vancomycin and piperacillin/tazobactam was started as well to cover for possible superinfection. The patient noted dramatic improvement in the range of motion, swelling, and pain in his hands by the next morning. Antibiotics were discontinued and he was discharged home with daily prednisone. At follow-up 14 days later, there was continued improvement. His steroid regimen was continued with a 6-week taper. At his most recent follow-up 1 year later, there had been no relapses of his NDDH. A new single 4 mm lingular nodule was found and planned to be reassessed via computed tomography (CT) in three months.

## Discussion

In 1964, Robert Sweet first described a syndrome known as acute febrile neutrophilic dermatosis based on a series of 8 cases. This syndrome later became eponymous with Dr. Sweet and has since been commonly referred to as Sweet Syndrome [1]. NDDH, now believed to be an uncommon variant of Sweet syndrome, was first described in 1995 by Strutton and colleagues based on a case series of 6 patients dating back to 1977 [1,2,3,4]. The cases he described included patients with hemorrhagic papules and plaques along with bullous lesions limited to the dorsal surface of the hands. All had evidence of leukocytoclastic vasculitis on biopsy leading to the term “pustular vasculitis of the hands” [5]. However, several cases have been reported since, lacking evidence of vasculitis. [6]

NDDH presents with the abrupt onset of aseptic neutrophilic dermal infiltrates that manifest as painful violaceous papules, plaques, and pustules limited to the dorsal hands with occasional involvement of the distal forearm. They also often appear with abscess-like nodules not typical of classic Sweet syndrome. The histopathological differential diagnosis includes classic Sweet syndrome, pustular drug reactions, pyoderma gangrenosum, rheumatoid neutrophilic dermatosis, bowel associated dermatosis arthritis syndrome, and early erythema elevatum diutinum [7].

Classic Sweet syndrome occurs more frequently in middle-aged women, whereas NDDH may occur later in life [3,4,8]. NDDH has been associated with pulmonary infections, hematologic diseases, and lung malignancies [9,10-13]. Our patient also had a history of mild, well-controlled ulcerative colitis, which has been associated with 16% of classic Sweet syndrome [3]. Our patient is unique in that the cause of his NDDH may be multifactorial.

The recurrence rate of NDDH is sparsely reported in the literature and has been noted to be both frequent and rare [2,6]. We thus reviewed the approximately 75 cases of NDDH that have thus been published and found that there were 7 recurrences (approximately 10%). The relapses occurred in patients without any of the known associations with NDDH, whereas one patient had a relapse after thalidomide re-administration [6,14-17]. There were no relapses that occurred with tumor recurrence. This temporal relationship was of interest to us because of the concern that a recurrence of our patient's cancer could be signaled by NDDH recurrence.

To conclude, we report on a patient with NDDH related to lung malignancy and possibly ulcerative colitis. We also discuss the approximate 10% recurrence rate of NDDH based on reported cases. We feel this information will be important when counseling patients on the prognosis of this uncommon variant of Sweet syndrome.

## References

1. Brajon D, Cuny JF, Barbaud A, Schmutz JL. Neutrophilic dermatosis of the hands. *Ann Dermatol Venereol*. 2011 Oct; 138(10):673-6. [PMID: 21978504]
2. Galaria NA, Junkins-Hopkins JM, Kligman D, James WD. Neutrophilic dermatosis of the dorsal hands: pustular vasculitis revisited. *J Am Acad Dermatol*. 2000 Nov;43(5 Pt 1):870-4. [PMID:11050599]
3. Marzano AV, Menicanti C, Crosti C, Trevisan V. Neutrophilic dermatosis and inflammatory bowel diseases. *G Ital Dermatol Venereol*. 2013 Apr;148(2):185-96. [PMID:23588144]
4. Sweet RD. An Acute Febrile Neutrophilic Dermatitis. *Br J Dermatol*. 1964;76:349. [PMID:14201182]
5. Strutton G, Weedon D, Robertson I. Pustular vasculitis of the hands. *J Am Acad Dermatol*. 1995 Feb; 32(2 Pt 1): 192-8. [PMID:7829702]
6. Del Pozo J, Sacristan F, Martinez W, et al. Neutrophilic dermatosis of the hands: Presentation of eight cases and review of the literature. *Journal of Dermatology*. 2007; 34: 243-7. [PMID:17352721]
7. Cohen PR, Hongsmann H, Kurzrock R. Acute febrile neutrophilic dermatosis (Sweet syndrome). In: Fitzpatrick's Dermatology in General Medicine, 8th ed, Goldsmith LA, Katz SI, Gilchrest BA, et al. (Eds), McGraw Hill, 2012. Vol 1, p.362.
8. Cohen PR. Sweet's syndrome--a comprehensive review of an acute febrile neutrophilic dermatosis. *Orphanet J Rare Dis*. 2007;2:34. [PMID:17655751]
9. Walling HW, Snipes CJ, Gerami P, Piette WW. The relationship between neutrophilic dermatosis of the dorsal hands and sweet syndrome: a report of 9 cases and comparison to atypical pyoderma gangrenosum. *Arch Dermatol*. 2006 Jan;142(1):57-63. [PMID:16415387]
10. Shugarman IL, Schmit JM, Sbicca JA, Wirk B. Easily missed extracutaneous manifestation of malignancy-associated Sweet's syndrome: systemic inflammatory response syndrome. *J Clin Oncol*. 2011 Aug;29(24):e702-5. [PMID:21747081]
11. Weedon D. *Weedon's Skin Pathology*. 3rd ed. Philadelphia: Churchill Livingstone, 2010; Chapter 8, The vacuopathic reaction pattern. 195-244.
12. Wawrzycki B, Chodorowska G, Pietrzak A, Krasowska DW, Wąsik S, Dybiec E, Lotti T, Hercegova J. Recurrent skin eruption in patient with chronic lymphocytic leukemia and lymphocytic infiltrates of the dermis resembling Sweet's syndrome. *G Ital Dermatol Venereol*. 2011 Dec;146(6):487-92. [PMID:22095180]
13. Ravaglia C, Poletti G, Gurioli C, Casoni GL, Dubini A, Re G, Poletti V. Sweet's syndrome associated with myelogenous leukemia and pulmonary involvement. *Monaldi Arch Chest Dis*. 2011 Jun;75(2):149-5. [PMID:21932704]
14. DiCaudo DJ, Connolly SM. Neutrophilic dermatosis (pustular vasculitis) of the dorsal hands: a report of 7 cases and review of the literature. *Arch Dermatol*. 2002 Mar;138(3):361-5. [PMID: 11902987]
15. Larsen HK, Danielsen AG, Krustup D, Weismann K. Neutrophil dermatosis of the dorsal hands. *J Eur Acad Dermatol Venereol*. 2005 Sep;19(5):634-7. [PMID: 16164726]
16. Mathieu S, Soubrier M, Tournadre A, Dubost JJ. Neutrophilic dermatosis of the dorsal hands during thalidomide treatment. *Int J Dermatol*. 2014 Sep;53(9):1133-5. [PMID: 23621549]
17. Stransky L, Broshtilova V. Neutrophilic dermatosis of the dorsal hands elicited by thermal injury. *Contact Dermatitis*. 2003 Jul;49(1):42. [PMID: 14641120]