

UC Davis

Dermatology Online Journal

Title

Combined closures in reconstructive surgery

Permalink

<https://escholarship.org/uc/item/6dx2m7cf>

Journal

Dermatology Online Journal, 23(5)

Authors

Kohli, Nita
Kwedat, Kathleen
Golda, Nicholas

Publication Date

2017

DOI

10.5070/D3235034924

Copyright Information

Copyright 2017 by the author(s). This work is made available under the terms of a Creative Commons Attribution-NonCommercial-NoDerivatives License, available at <https://creativecommons.org/licenses/by-nc-nd/4.0/>

Combined closures in reconstructive surgery

Nita Kohli¹ MD MPH, Kathleen Kwedar² BS, Nicholas Golda¹ MD

Affiliations: ¹University of Missouri-Columbia, Department of Dermatology, Columbia, Missouri, ²University of Missouri-Columbia School of Medicine, Columbia, Missouri

Corresponding Author: Nicholas Golda, MD, University of Missouri Department of Dermatology, One Hospital Drive Room MA111, Columbia, MO 65212, Tel. 573-268-4969, Email: goldan@health.missouri.edu

Abstract

It is common for dermatology surgery patients to present on the day of surgery with more than one skin cancer needing Mohs micrographic surgery. When these carcinomas are located near one another, it may be more practical to treat both at the same time as the reconstruction for one defect may involve or otherwise affect the treatment or reconstruction for the other carcinoma. Treating both cancers on the same day creates an opportunity for efficient repairs where a creative single reconstruction may minimize the amount of tissue wasted during reconstruction, and minimize morbidity for the patient. Further, combining multiple defects into one closure may reduce cost as it has been shown that reconstructive choice affects the cost-effectiveness of Mohs surgery relative to a traditional excision and Mohs surgeons more commonly select less costly options for wound management. We present a case series of two-in-one closures - repairing two defects with one closure.

Keywords: Mohs surgery, combined reconstruction, multiple defects, tissue conservation

Introduction

It is common for dermatology surgery patients to present on the day of surgery with more than one skin cancer needing Mohs micrographic surgery^{1,2}. When these carcinomas are located near one another, it may be more practical to treat both at the same time as the reconstruction for one defect may involve or otherwise affect the treatment or reconstruction for the other carcinoma. Treating both cancers on the same day creates an opportunity for efficient repairs where a creative single reconstruction may minimize

the amount of tissue wasted during reconstruction and minimize morbidity for the patient. Further, combining multiple defects into one closure may reduce cost as it has been shown that reconstructive choice affects the cost-effectiveness of Mohs surgery relative to a traditional excision and Mohs surgeons more commonly select less costly options for wound management³. We present a case series of two-in-one closures - repairing two defects with one closure.

Case 1: Patient presented with defects of the left preauricular cheek and the left mandible after Mohs surgery (**Figure 1a**). Options for repair included healing by second intent, skin grafts, separate flap repairs, or linear closure for the inferior defect in combination with any of the aforementioned for the superior defect, as the superior defect could not be closed primarily. We closed both defects with a single transposition flap by utilizing the intervening skin (**Figure 1a**, marked with star) between the two defects to transpose into the superior defect. The inferior defect was closed by secondary motion of the tissue trailing the transposition from the neck (**Figures 1 b, c**).

Case 2: Patient presented with defects of the right upper forehead and right temporal hairline after Mohs surgery (**Figure 1d**). Options for repair were limited due to the nonviability of the isthmus of skin remaining between the defects and the upward pull on the brow that would result from primary closure. Instead we opted for an "East-West style" advancement flap closure to close both defects (**Figures 1 e, f**).

Case 3: Patient presented with defects of the right lateral cheek and the right temple after Mohs surgery (**Figure 1g**). Options for repair included an

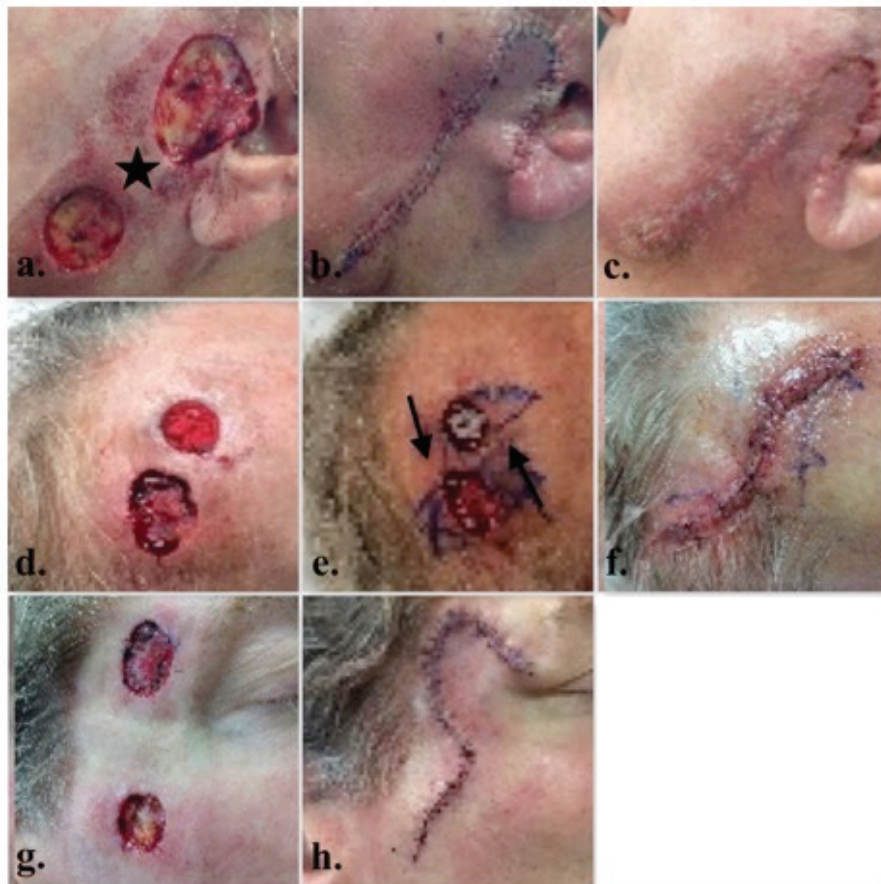

Figure 1. a) Case 1: Immediate post-Mohs; b) Case 1: Immediate post-reconstruction; c) Case 1: One week follow-up; d) Case 2: Immediate post-Mohs; e) Case 2: surgical planning; f) Case 2: immediate post-reconstruction; g) Case 3: Immediate post-Mohs; h) Case 3: Immediate post-reconstruction.

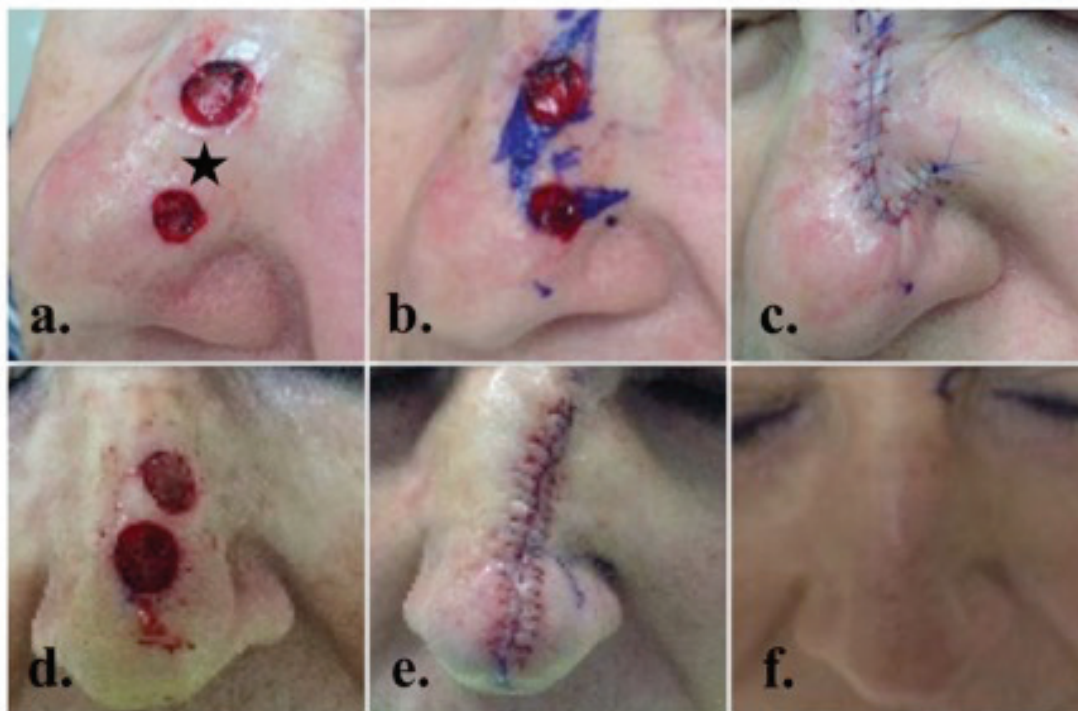

Figure 2. a) Case 4: Immediate post-Mohs; b) Case 4: Planned incision for a combination rotation flap closure; c) Case 4: Immediate post-reconstruction; d) Case 5: Immediate post-Mohs; e) Case 5: Immediate post-reconstruction; f) Case 5: One week follow-up.

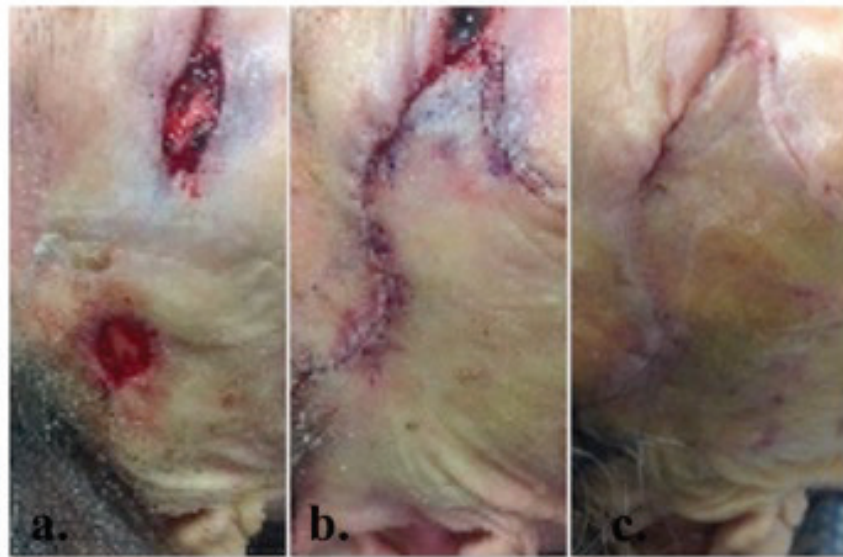


Figure 3. a) Case 6: Immediate post-Mohs; b) Case 6: Immediate post-reconstruction; c) Case 6: One week follow-up.

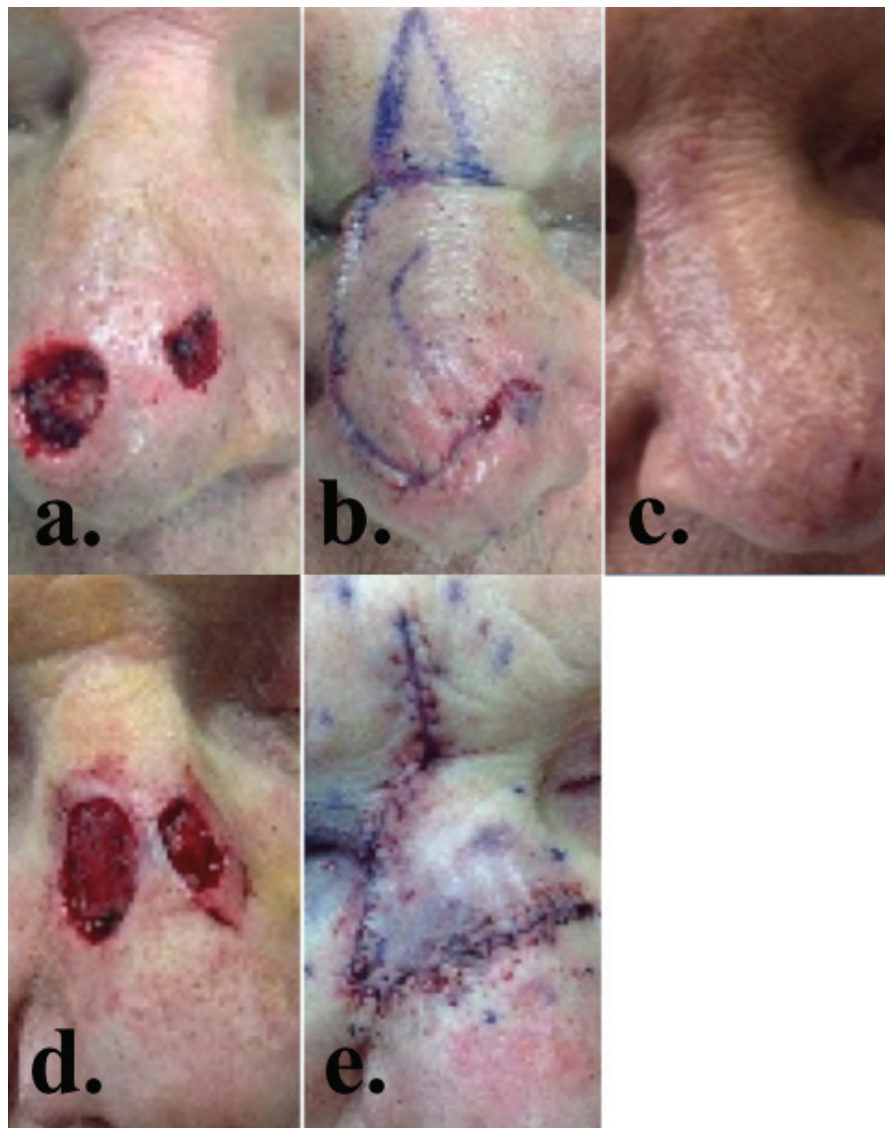


Figure 4. a) Case 7: Immediate post-Mohs; b) Case 7: Immediate post-reconstruction; c) Case 7: One week follow-up; d) Case 8: Immediate post-Mohs; e) Case 8: Immediate post-reconstruction.

advancement flap for the temple defect and primary closure of the cheek defect. We opted for a single rotation flap closure to close both defects (**Figure 1h**). The temple defect was closed with the primary movement of a rotation flap, and the cheek defect was incorporated into the standing cone deformity normally excised at the tail of a conventionally executed rotation flap.

Case 4: Patient presented with defects of the left nasal dorsum and the left nasal tip after Mohs surgery (**Figure 2a**). Secondary intention healing and skin grafting were options for closure. Primary closure could also be considered for the superior defect in a superior to inferior direction along the nasal dorsum, but the inferior defect would require a separate flap or graft closure. These defects were ultimately closed with a single rotation flap. This was done by rotating the intervening skin (**Figure 2a**, marked with star) between the defects into the inferior defect, thus incorporating the superior defect into the normally-occurring secondary defect created by any rotation flap (**Figure 2b**). This secondary defect/superior defect combination was closed utilizing the normal tissue reservoir found on the nasal dorsum (**Figure 2c**).

Case 5: Patient presented with defects of the superior and inferior nasal dorsum after Mohs surgery (**Figure 2d**). Options for repair included dorsal nasal rotation flap. Instead we opted for a combined primary linear closure for both defects (**Figures 2 e, f**).

Case 6: Patient presented with defects of the right lower eyelid and the right temple after Mohs surgery (**Figure 3a**). Options for repair included primary closure of the temple defect and rotation, bilateral A-T advancement flap, upper to lower lid transposition flap, or skin graft for the lower eyelid defect. Instead we opted for a Tenzel rotation flap to close both defects, incorporating the temple defect into the standing cone normally excised with this flap (**Figures 3 b, c**).

Case 7: Patient presented with defects of the right nasal tip and the left nasal supratip after Mohs surgery (**Figure 4a**). Both defects were closed with a single rotation flap incorporating the left nasal supratip defect (**Figure 4a, arrow**) into the tissue that would

normally be removed at the pivot point of a dorsal nasal rotation flap (**Figures 4 b, c**).

Case 8: Another patient presented with defects of the left and right nasal dorsum after Mohs surgery (**Figure 4d**). Similar to Case 7, the two nasal dorsum defects were treated as one with a dorsal nasal rotation flap with the subsequent cone positioned in the smaller defect site on the left nasal dorsum (**Figure 4e**).

Discussion

In our practice, we limit the number of Mohs surgeries to two tumors per patient per day. Treating no more than two tumors in a single day provides tolerability for the patient, subsequent relative ease in wound care, and fewer limitations on activities after surgery. It is also convenient for the patient who travels a long distance for Mohs surgery to have at least two tumors treated during the same visit. A combined repair creates an opportunity to extend the tissue conservation principle of Mohs surgery⁴ and possibly decrease cost.

References

1. Schinstine M, Goldman GD. Risk of synchronous and metachronous second nonmelanoma skin cancer when referred for Mohs micrographic surgery. *J Am Acad Dermatol.* 2001 Mar;44(3):497-9. [PMID: 11209121]
2. Ruiz ES, Karia PS, Morgan FC, Liang CA, Schmults CD. Multiple Mohs micrographic surgery is the most common reason for divergence from the appropriate use criteria: A single institution retrospective cohort study. *J Am Acad Dermatol.* 2016 Oct;75(4):830-1. [PMID: 27646739]
3. Bialy TL, Whalen J, Veledar E, Lafreniere D, Spiro J, Chartier T, Chen SC. Mohs micrographic surgery vs traditional surgical excision: a cost comparison analysis. *Arch Dermatol.* 2004 Jun;140(6):736-42. [PMID: 15210467]
4. Shriner DL, McCoy DK, Goldberg DJ, Wagner RF Jr. Mohs micrographic surgery. *J Am Acad Dermatol.* 1998 Jul;39(1):79-97. [PMID: 9674401]