

UC Davis

Dermatology Online Journal

Title

A verrucous presentation of mycosis fungoides

Permalink

<https://escholarship.org/uc/item/6d97p2b9>

Journal

Dermatology Online Journal, 20(8)

Authors

Bunata, Kristin
Jahan-Tigh, Richard Reza
Curry, Jonathan
et al.

Publication Date

2014

DOI

10.5070/D3208023526

Copyright Information

Copyright 2014 by the author(s). This work is made available under the terms of a Creative Commons Attribution-NonCommercial-NoDerivatives License, available at <https://creativecommons.org/licenses/by-nc-nd/4.0/>

Peer reviewed

Case Report

A verrucous presentation of mycosis fungoides.

Kristin Bunata¹, Richard Reza Jahan-Tigh MD^{1,2,4}, Jonathan Curry MD³, Madeleine Duvic MD⁴

Dermatology Online Journal 20 (8): 3

¹**University of Texas Medical School at Houston, Houston, Texas**

²**Departments of Dermatology and Pathology, University of Texas Health Science Center Houston, Houston, Texas**

³**Department of Pathology, University of Texas M.D. Anderson Cancer Center, Houston, Texas**

⁴**Department of Dermatology, University of Texas M.D. Anderson Cancer Center, Houston, Texas**

Correspondence:

Madeleine Duvic, MD, Professor and Deputy Chairman
Department of Dermatology, University of Texas M.D. Anderson Cancer Center
1400 Pressler Avenue, Unit 1452
Houston, TX, USA 77030
Phone: 713-745-4615
mduvic@mdanderson.org

Abstract

Mycosis Fungoides (MF) is the most common cutaneous T-cell lymphoma and can have a variety of clinical and histological manifestations, including erythrodermic, pustular, bullous, hypo/hyperpigmented, and verrucous forms. We describe a case of a 59-year-old woman who presented with verrucous hyperkeratotic plaques on her distal fingertips, dorsal feet, and areolae that were subsequently biopsied and shown to be mycosis fungoides. This case highlights one of the many atypical manifestations of MF and underscores the need to have a high clinical suspicion for the disease.

Keywords: Mycosis fungoides, verrucous, cutaneous T-cell lymphoma (CTCL)

Abbreviation / Acronym List:

MF: Mycosis Fungoides

PVA: Poikiloderma vasculare atrophicans

ENV: Elephantiasis nostras verrucosa

TCR: T-cell receptor

Introduction

Mycosis Fungoides (MF) is the most common cutaneous T-cell lymphoma and can have many different manifestations [1]. The classic histology is characterized by atypical lymphocytes lining up along the dermal-epidermal junction, entering the epidermis with minimal spongiosis, and forming collections of atypical cells called “Pautrier’s microabscesses”. Clinically, lesions are grouped into three different stages including patches, plaques, and tumors. However, MF can be difficult to diagnose as it may masquerade as other conditions. We present a case of MF with a verrucous appearance initially diagnosed as psoriasis.

Case synopsis

A 59-year-old woman presented with a three-year history of pruritic lichenified plaques on her hands, arms, areola, and scalp. A biopsy done of the hand plaques had been interpreted as psoriasis but the plaques continued to worsen despite treatment with high potency topical steroids and a two-month trial of acitretin. Her past medical history was significant for hypertension and bipolar disorder and her medications included metoprolol and aripiprazole. A review of systems was significant for a one-year history of severe pruritus concentrated on her lesions. Physical exam revealed patchy alopecia throughout her scalp with prominent tumors as well as large crusted hyperpigmented plaques on her arms and legs. Her distal fingertips, dorsal feet, and areolae had verrucous hyperkeratotic plaques (Figures 1-4). There was non-pitting edema of hands/feet and bilateral inguinal lymphadenopathy.

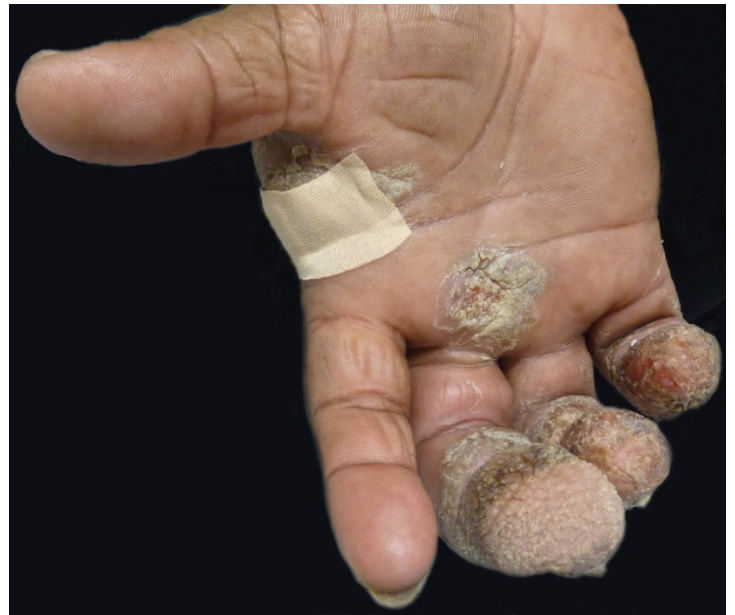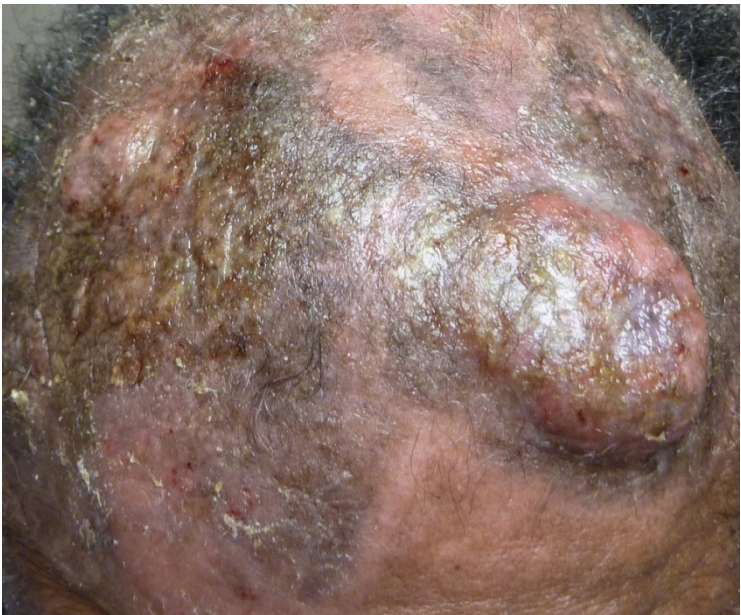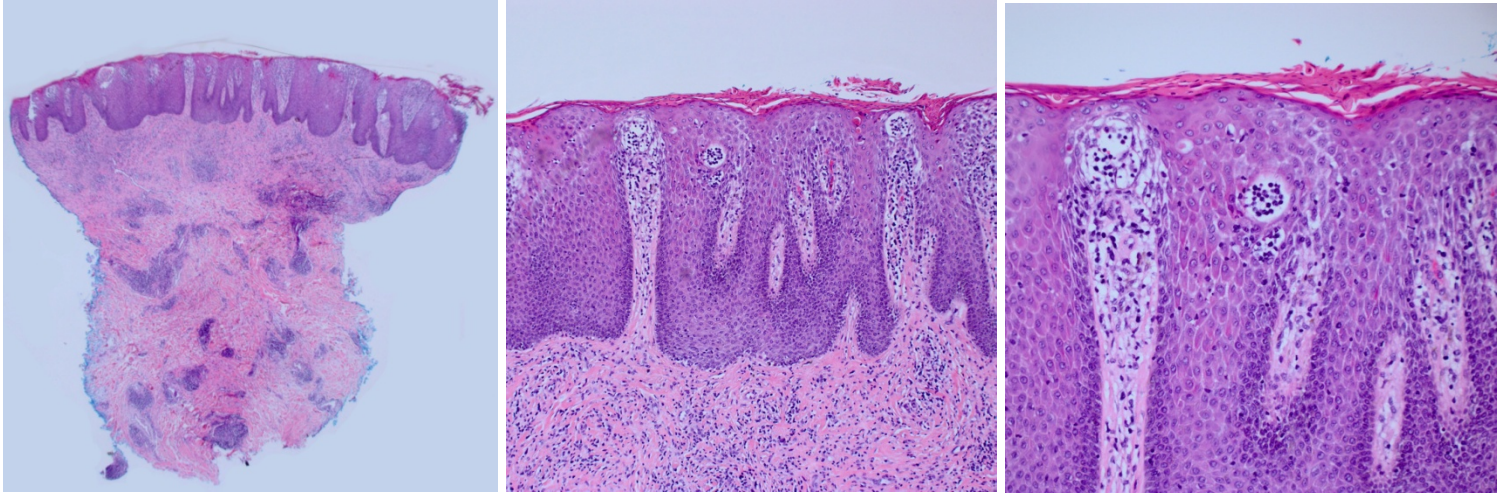


Figure 1. Tumors and alopecia of the scalp **Figure 2.** Verrucous plaques on distal fingertips

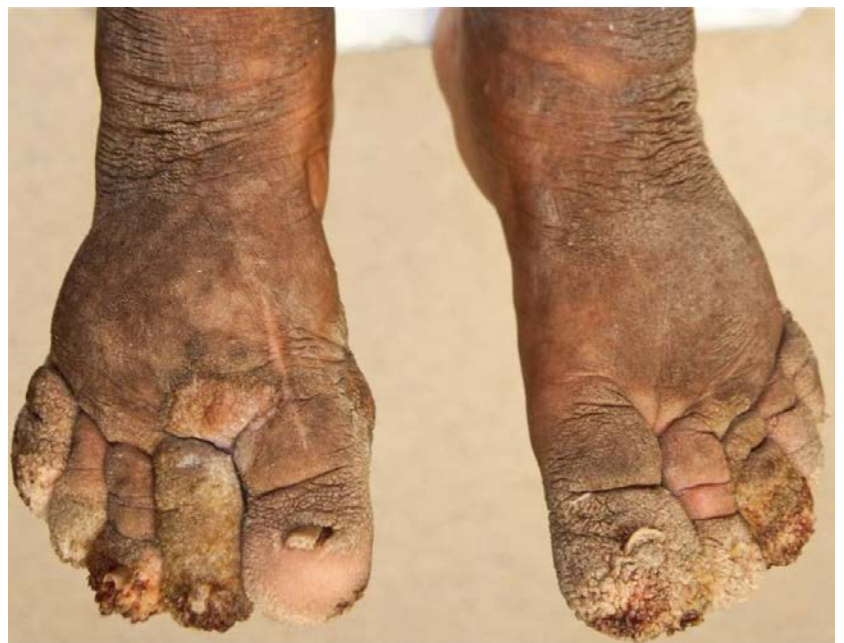
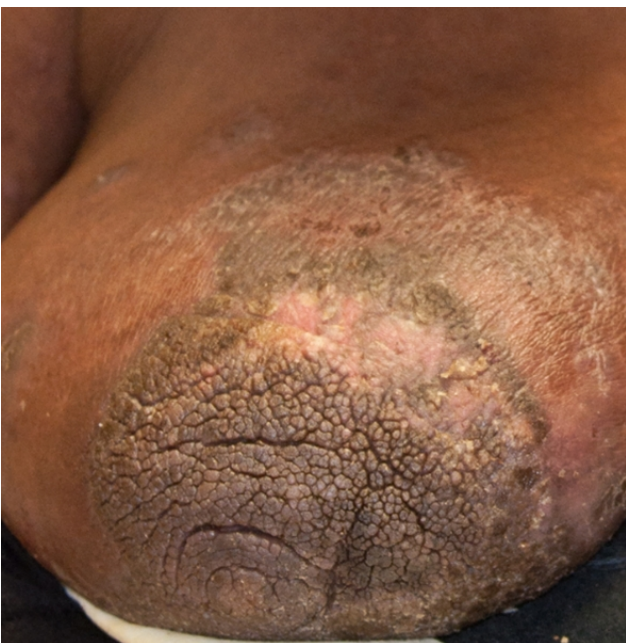
Figure 3. Thickened verrucous areolar plaque **Figure 4.** Confluent verruciform plaques on bilateral dorsal feet with onycholysis

Biopsies of the verrucous plaques from the areola and right hand demonstrated psoriasiform epidermal hyperplasia, a confluent parakeratotic stratum corneum, suprapapillary thinning, spongiosis, and a dense lymphocytic infiltrate along the dermal-epidermal junction (especially in the papillary dermis) and in the superficial perivascular plexus (Figure 5-6). Atypical lymphocytes were concentrated in the epidermal microabscesses (Figure 7). Immunohistochemical studies showed the lymphocytic infiltrate to be predominantly CD3+ and CD4+ with scattered benign appearing epidermal lymphocytes staining for CD8. There was dramatic loss of CD7 in the epidermal microabscesses and in the suprapapillary dermal infiltrate. The dermal CD4:CD8 ratio was approximately 5:1 (Figures 8-11) Alpha-beta T-cell receptor gene rearrangement was positive for a clonal population.



Figures 5-7. Hematoxylin and eosin staining from left areola punch biopsy showing atypical dermal lymphocytic infiltrate with involvement of overlying epidermis; The epidermis demonstrates psoriasiform hyperplasia with spongiosis and scattered epidermotropic atypical lymphocytes, most of which are forming epidermal aggregates (20x, 100x, 200x).

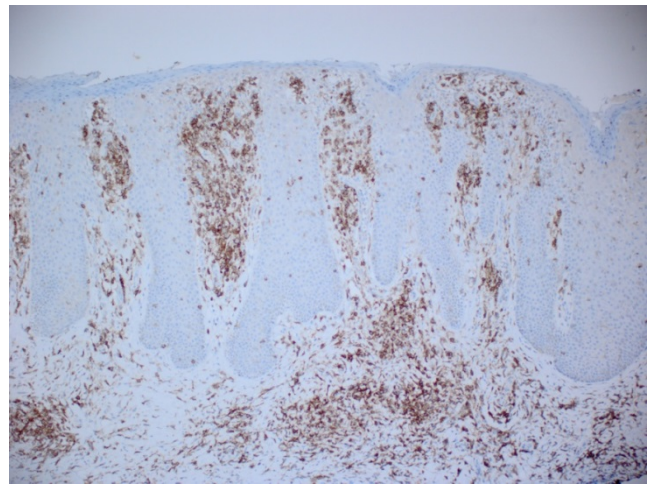
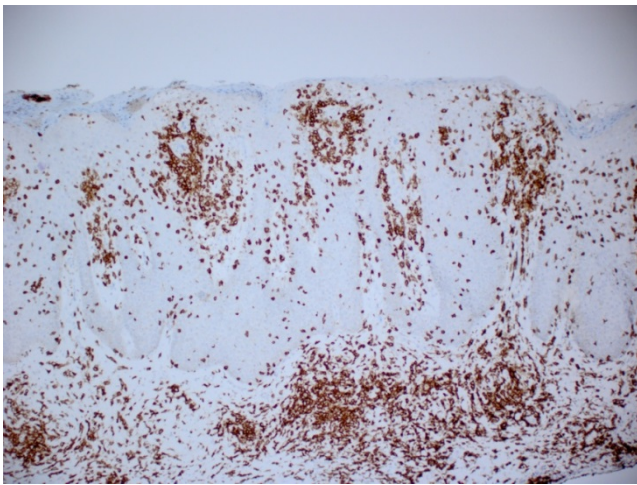


Figure 8. CD3 immunohistochemistry shows abundant T-cells. **Figure 9.** CD4 immunohistochemistry staining the majority of the atypical epidermal and dermal lymphocytic infiltrate

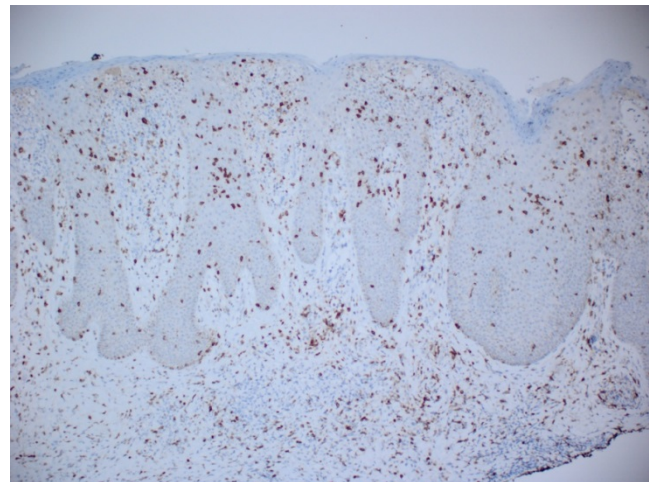
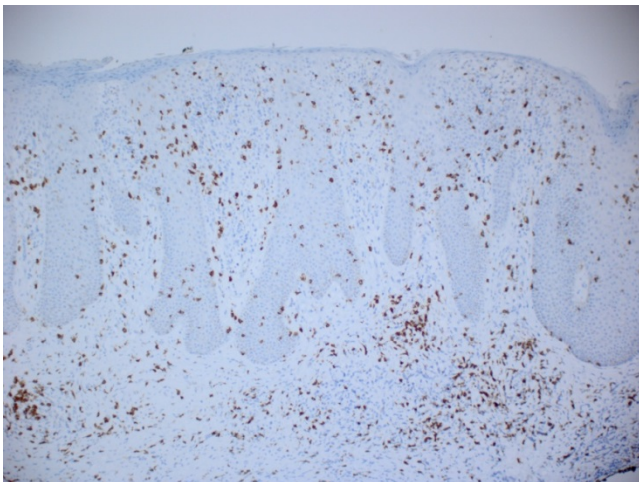


Figure 10. CD8 immunohistochemistry highlights scattered reactive epidermal and dermal T-cells. **Figure 11.** CD7 shows dramatic loss in the Pautrier's microabscesses and atypical dermal lymphocytes.

A PET-CT scan was significant for bilateral cervical, axillary, and inguinal lymphadenopathy. Peripheral blood flow cytometry was normal except for a low CD8 count of 52/uL (nl 78-746/uL). Bone marrow biopsy showed trilinear hematopoiesis with lymphocytosis and a subset of lymphocytes with atypical morphological features. Cultures were negative for all organisms other than *Staphylococcus aureus*. The patient was diagnosed with stage IIB mycosis fungoides and was started on oral bexarotene 300mg/m²/day. Her disease eventually progressed through bexarotene and, although other systemic therapies were attempted, she ultimately succumbed to her disease.

Discussion

In 1896, Hallopeau and Bureau first recognized the presence of verrucous lesions in MF and noted that although hyperkeratosis of palmo-plantar surfaces was a common finding in MF, similar lesions elsewhere were quite unusual [2]. Likewise, Jeanselme and Burnier described three patients with hyperkeratotic verrucous lesions predominantly on distal extremities [3] and Asel et al. reported a presentation of MF consisting of verrucous plaques and nodules on bilateral lower extremities [4]. The lesions may be quiescent for long periods as demonstrated by Price et al. who described a patient with verrucous lesions entirely confined to one foot for a period of 24 years [5]. Tyring et al. reported a patient with a widespread verrucous presentation of MF and concurrent poikiloderma vasculare atrophicans (PVA), in which several of the verrucous lesions originated where PVA had previously been observed [6].

The widespread distribution of the verrucous lesions in our patient is unique in that it occurred in the absence of PVA. In particular, involvement of bilateral areolae is particularly unusual given that distal extremities are often the sole location of verrucous lesions. A portion of the verrucous appearance may be secondary to edema causing a cutaneous reaction similar to incipient elephantiasis nostras verrucosa in the setting of lymphedema. In this form of elephantiasis, prolonged lymphostasis results in the accumulation of protein-rich fluid, which is thought to promote fibroblast proliferation leading to fibrosis of the dermis and subcutaneous tissue. Lymphangitis may then cause further fibrosis of the dermis, and the lymphedema worsens. Hence, a cycle of lymphedema and fibrosis is begun and the condition continues to progress [7].

A multitude of histological patterns have been reported in MF, including the psoriasiform reaction pattern seen in our case [8]. Clues that help distinguish the MF from psoriasis are the presence of atypical lymphocytes, the loss of CD7, and the clonality of the TCR. In addition to psoriasis, the clinical differential includes elephantiasis nostras verrucosa, chronic cutaneous candidiasis, tuberculosis verrucosa cutis, and deep fungal infections or mycetomas. These can be excluded on the basis of histology and culture. In our patient, none of her cultures were positive for any organism other than *Staphylococcus aureus*.

This case illustrates the importance of maintaining a high index of suspicion for MF, especially when conditions do not respond as expected to treatment as has been documented previously [9]. In our case, the patient presented with scalp tumors after failing treatment for psoriasis. Increasing awareness about atypical presentations such as this case can help improve early recognition and treatment of the disease.

References

1. Zackheim HS, McCalmont TH. Mycosis fungoides: the great imitator. *J Am Acad Dermatol.* 2002 Dec;47(6):914-8. [PMID: 12451378]
2. Hallopeau H, Bureau G. Sur un cas de mycose fungoide avec localisation initiale eruptions polymorphes et vegetations axillaire et inguinales. *Bull Soc Fr Dermatol Syphiligr* 1896;7:480-2.
3. Jeanselme E, Burnier J. La forme verruqueuse et hyperkeratosique du mycosis fongoide. *Ann Dermatol Venereol.* 1926;7:65-72.
4. Asel ND, Spiller WF, Chivington PV Jr. Mycosis fungoides with verrucous lesions. *Arch Dermatol* 1951;63:635-8. [PMID: 14818427]
5. Price NM, Fuks ZY, Hoffman TE. Hyperkeratotic and verrucous features of mycosis fungoides. *Arch Dermatol* 1977;113(1):57-60. [PMID: 831623]
6. Tyring SK, Jones CS, Lee PC, Fine JD. Development of verrucous plaques and gross hematuria in advanced cutaneous T-cell lymphoma. *Arch Dermatol* 1988;124(5):655-7. [PMID: 3364989]
7. Sisto K, Khachemoune A. Elephantiasis nostras verrucosa: a review. *Am J Clin Dermatol* 2008; 9(3):141-6. [PMID: 18429642]
8. Reddy K, Bhawan J. Histologic mimickers of mycosis fungoides: a review. *J Cutan Pathol.* 2007 Jul;34(7):519-25. [PMID: 17576330]

9. Zackheim HS, Koo J, LeBoit PE, McCalmont TH, Bowman PH, Kashani-Sabet M, Jones C, Zehnder J. Psoriasiform mycosis fungoides with fatal outcome after treatment with cyclosporine. *J Am Acad Dermatol*. 2002 Jul;47(1):155-7. [PMID: 12077599]