

UC Davis

Dermatology Online Journal

Title

Disseminated cutaneous sporotrichosis

Permalink

<https://escholarship.org/uc/item/62j0t5r9>

Journal

Dermatology Online Journal, 19(11)

Authors

Chang, Shurong
Hersh, Andrew M
Naughton, Greg
et al.

Publication Date

2013

DOI

10.5070/D31911020401

Copyright Information

Copyright 2013 by the author(s). This work is made available under the terms of a Creative Commons Attribution-NonCommercial-NoDerivatives License, available at <https://creativecommons.org/licenses/by-nc-nd/4.0/>

Peer reviewed

Case Presentation

Disseminated cutaneous sporotrichosis

Shurong Chang MD PhD¹, Andrew M. Hersh MD², Greg Naughton MD MS², Kevin Mullins BS², Maxwell A. Fung MD^{1,3}, and Victoria R. Sharon MD DTMH¹

Dermatology Online Journal 19 (11): 8

¹Department of Dermatology, University of California, Davis

²Department of Internal Medicine, University of California, Davis

³Department of Pathology, University of California, Davis

Correspondence:

Victoria R. Sharon, MD, DTMH
University of California, Davis
Department of Dermatology
3301 C Street, Suite 1400
Sacramento, CA 95816

Abstract

The dimorphic fungus *Sporothrix schenckii* commonly causes localized cutaneous disease with lymphocutaneous distribution. However, disseminated sporotrichosis occurs predominantly in immunocompromised patients. We report a case of disseminated cutaneous sporotrichosis in a patient with newly diagnosed HIV with a CD4 count of 208. The patient presented with multiple cutaneous and subcutaneous nodules as well as fever and malaise. Tissue culture and skin biopsy confirmed the diagnosis of sporotrichosis. He was started on itraconazole 200mg twice a day with rapid resolution of fever along with cessation of the development of new lesions.

Keywords: HIV, sporotrichosis, itraconazole

Case Report

A 41-year-old man with a history of intravenous drug use, alcohol abuse, and recently diagnosed HIV with a CD4 count of 208, presented with fever, malaise, and cutaneous and subcutaneous nodules. The nodules were first noted five weeks prior to presentation on the left hand, but progressively spread to other body sites. He had been most recently living in a tent adjacent to bushes in an urban setting and acknowledged frequent minor cutaneous trauma from sharp pine needles.

Physical examination was notable for an excess of 50 disseminated erythematous papules, vesiculopustules, and subcutaneous nodules, many of which developed ulceration with black hyperkeratotic crusts (Figure 1A). On the arms and legs, several of these subcutaneous nodules were distributed in a sporotrichoid pattern, along the lymphatic vessels. There was marked cervical lymphadenopathy. The differential diagnosis included deep fungal infection including sporotrichosis, secondary syphilis, and bacterial infection. A 4mm punch biopsy obtained from an intact vesiculopustule on the abdomen demonstrated multiple isolated yeast cells surrounded by a mixed neutrophilic and granulomatous infiltrate (Figure 1B). Fungal culture of skin tissue confirmed the diagnosis of disseminated *Sporothrix schenckii*.

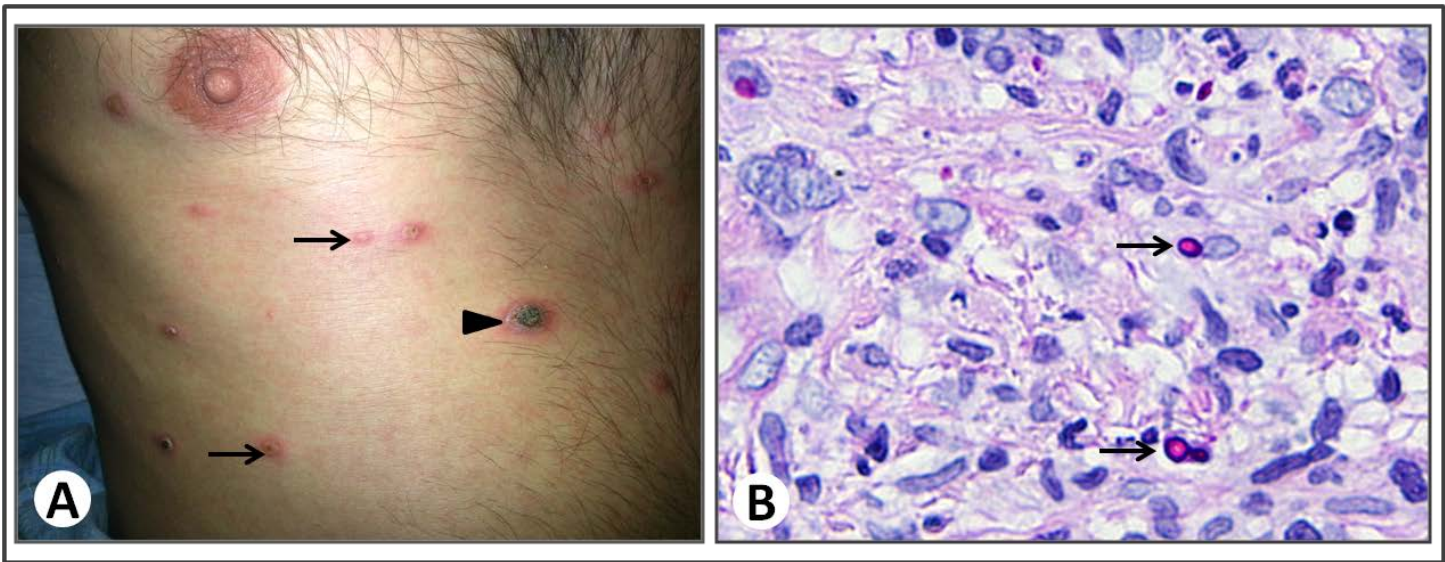


Figure 1 A. Multiple erythematous vesiculopustules (arrows) and ulcerated nodules (arrowhead) on the trunk B. Yeast cells (arrows) surrounded by granulomatous and neutrophilic infiltrates (PAS stain, 600X)

Treatment was subsequently initiated with itraconazole 200mg twice daily, which resulted in rapid resolution of fever and cessation of the development of new lesions. The patient was concomitantly started on highly active antiretroviral therapy prior to discharge.

Discussion

Sporotrichosis is a subacute to chronic subcutaneous fungal infection typically caused by traumatic inoculation of the dimorphic fungus *Sporothrix schenckii* from the soil, sphagnum moss, and other vegetative matter. Zoonotic transmission, especially from felines, has also been reported [1]. Localized disease most commonly presents in a lymphocutaneous distribution, whereas disseminated cutaneous disease predominantly occurs in an immunocompromised setting, as in this patient. In a large series of patients reported from China, disseminated cutaneous sporotrichosis represented 1.75% (8/457) of all sporotrichosis cases [2].

The association of HIV and disseminated sporotrichosis has been reported since the discovery of HIV in the early 1980s [3]. In 2012, Freitas et al reported 21 cases of sporotrichosis in HIV patients in Rio de Janeiro. Of these, 7/21 manifested disseminated disease involving the skin and at least one other system, such as mucosa or osteoarticular tissues; meningoenophalitis was also reported. Widespread cutaneous disease was documented in 5/21. Of these patients with known CD4 counts, all except two (CD4 of 488 and 212) were below 200. In contrast, all cases with lymphocutaneous and fixed cutaneous disease had CD4 counts in excess of 200 [4]. These data demonstrate a positive correlation between disseminated disease and immunosuppression in HIV patients.

Although predominantly a disease in the immunocompromised, disseminated sporotrichosis has also been reported in immunocompetent patients [5]. Sporotrichosis should therefore be considered in all patients with polymorphous progressive cutaneous and subcutaneous nodules.

Reference

1. Reed KD, Moore FM, Geiger GE, Stemper ME. Zoonotic transmission of sporotrichosis: case report and review. *Clin Infect Dis.* 1993; 16:384-387. [PMID: 8095815]
2. Song Y, Li SS, Zhong SX, Liu YY, Yao L, Huo SS. Report of 457 sporotrichosis cases from Jilin province, northeast China, a serious endemic region. *J Eur Acad of Dermatol and Venereol.* 2013; 27:313-318. [PMID: 22176524]
3. Matter SE, Bailey DM, Sexton DJ. Immune deficiency presenting as disseminated sporotrichosis. *J Okla State Med Assoc.* 1984; 77:114-117. [PMID:6726496]
4. Freitas DF, de Siqueira Hoagland B, do Valle AC, Fraga BB, de Barros MB, de Oliveira Schubach A, de Almeida-Paes R, Cuzzi T, Rosalino CM, Zancopé-Oliveira RM, Gutierrez-Galhardo MC. Sporotrichosis in HIV-infected patients: report of 21 cases of endemic sporotrichosis in Rio de Janeiro, Brazil. *Medical Mycol.* 2012; 50:170-178. [PMID: 21859385]
5. Sharon VR, Kim J, Sudhakar S, Fung MA, Maniar A. Disseminated cutaneous sporotrichosis. *Lancet Infect Dis.* 2013; 13:95. [PMID: 23257234]