

UC Davis

Dermatology Online Journal

Title

Nodular lymphangitis related to methicillin-resistant staphylococcus aureus infection

Permalink

<https://escholarship.org/uc/item/5x52n3tg>

Journal

Dermatology Online Journal, 29(2)

Authors

Trepanowski, Nicole
Alomran, Abdulaziz
Mahalingam, Meera
et al.

Publication Date

2023

DOI

10.5070/D329260771

Copyright Information

Copyright 2023 by the author(s). This work is made available under the terms of a Creative Commons Attribution-NonCommercial-NoDerivatives License, available at <https://creativecommons.org/licenses/by-nc-nd/4.0/>

Peer reviewed

Nodular lymphangitis related to methicillin-resistant *Staphylococcus aureus* infection

Nicole Trepanowski^{1,2} BS, Abdulaziz Alomran³ MD, Meera Mahalingam^{3,4} MD PhD, Mariko R Yasuda^{5,6} MD, Rebecca I Hartman^{2,6,7} MD MPH

Affiliations: ¹Boston University School of Medicine, Boston, Massachusetts, USA, ²Department of Dermatology, Brigham and Women's Hospital, Boston, Massachusetts, USA, ³Department of Dermatology, Tufts University School of Medicine, Boston, Massachusetts, USA, ⁴Dermatopathology Section, Department of Pathology and Laboratory Medicine, VA Integrated Service Network, West Roxbury, Massachusetts, USA, ⁵Department of Dermatology, Massachusetts General Hospital, Boston, Massachusetts, USA, ⁶Harvard Medical School, Boston, Massachusetts, USA, ⁷Dermatology Section, Department of Medicine, VA Integrated Service Network, Jamaica Plain, Massachusetts, USA

Corresponding Author: Rebecca Hartman MD MPH, Department of Dermatology, Brigham and Women's Hospital, 221 Longwood Avenue, Boston, Massachusetts 02115, Tel: 617-732-4918, Email: rhartman@bwh.harvard.edu

Abstract

Nodular lymphangitis, also known as lymphocutaneous syndrome or sporotrichoid lymphangitis, presents with inflammatory nodules along the lymphatic vessels, typically involving the upper or lower extremities. Although the most common cause of nodular lymphangitis is infection due to *Sporothrix schenckii*, *Nocardia brasiliensis*, *Mycobacterium marinum*, or *Leishmania braziliensis*, it is important for clinicians to be aware of methicillin-resistant *Staphylococcus aureus* as a rare cause of nodular lymphangitis and perform gram stain, bacterial culture, and antibiotic sensitivity profiles when appropriate. History of recent travel or exposures, incubation time, presence of systemic symptoms, and presence of ulceration, suppuration, or drainage can serve as diagnostic clues, but microbiological tissue cultures and histopathologic studies confirm the diagnosis. Herein, we present a case of nodular lymphangitis caused by methicillin-resistant *Staphylococcus aureus* (MRSA); tissue culture and antibiotic sensitivities were used to guide treatment.

Keywords: abscess, cellulitis, infection, lymphangitis, lymphocutaneous, MRSA, nodular, sporotrichosis, sporotrichoid

Introduction

Nodular lymphangitis, also called lymphocutaneous syndrome and sporotrichoid lymphangitis, presents

with superficial cutaneous inflammatory nodules along the lymphatic drainage pathway [1]. Nodular lymphangitis most commonly occurs due to infectious etiologies and manifests in the upper or lower extremities [2]. Microbiological tissue cultures and skin biopsy confirm diagnosis.

Herein we present a case of nodular lymphangitis due to infection with methicillin-resistant *Staphylococcus aureus* (MRSA) following a course of prednisone for eczematous dermatitis.

Case Synopsis

A 95-year-old man who resides at home with a past medical history of type 2 diabetes mellitus and atopic dermatitis, previously well-controlled with topical corticosteroids, presented to the dermatology clinic with an eczematous, pruritic rash with erythematous plaques covering the trunk, arms, and shins. A punch biopsy over the right flank revealed acantholytic and spongiotic dermatosis, consistent with a flare of his preexisting atopic dermatitis as well as coexistent Grover disease on the torso. The patient was treated with a prednisone taper (50mg × four days, decreased by 10mg × four days until completed), which led to resolution of the patient's dermatitis and pruritus. However, two weeks after initiation of prednisone, the patient presented with new lesions over the bilateral thighs and shins, noted by a family member. At that time, the patient had two days of prednisone treatment

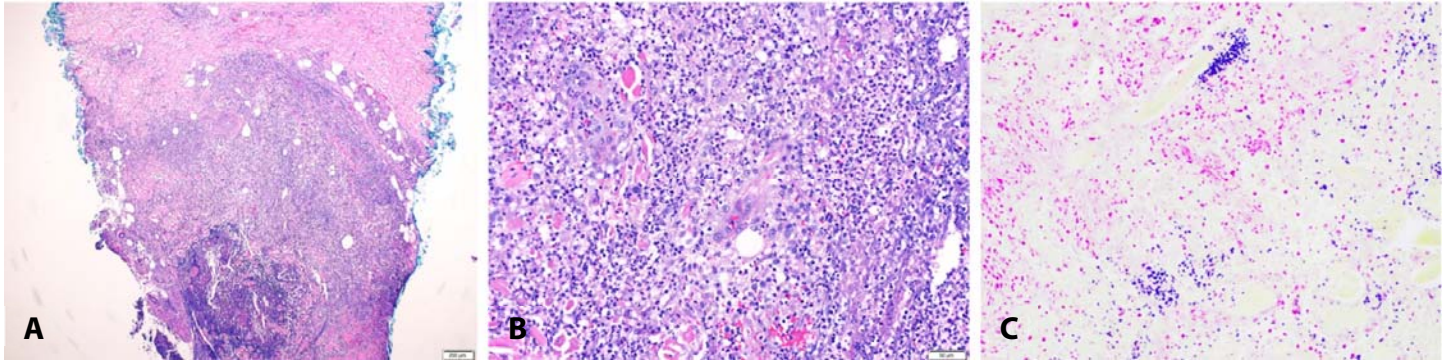


Figure 1. **A)** Nodular and erythematous lesions on the bilateral lower extremities in a lymphatic distribution, including lesions on the right medial thigh, right medial shin, left mid-thigh, and left lateral shin. **B)** Erythematous nodule on the left lateral shin. **C)** Dusky, violaceous erythematous nodule on the right medial thigh with ulceration with overlying purulent exudate.

remaining and he denied fevers, recent travel, or other symptoms. The patient had no exposure to soil, gardening, or aquatic environments.

Physical examination revealed multiple violaceous indurated nodules on the bilateral thighs and shins, some of which expressed pus with gentle palpation (**Figure 1**). These nodules were distributed along the lower extremity lymphatic drainage pathways. Two punch biopsies of the left thigh were performed, revealing superficial to deep suppurative inflammation with numerous clusters of bacterial cocci in the reticular dermis identified on Brown and Hopps (**Figure 2**). No fungi or mycobacteria were detected with periodic acid-Schiff, acid-fast, or Fite stains. Bacterial culture revealed multi-drug resistant MRSA, sensitive to tetracycline. The patient was treated with a two-week course of doxycycline 100mg twice daily.

The patient's nodules resolved following antibiotic treatment, but the patient experienced recurrence of the pruritic rash on the trunk and back, for which application of clobetasol 0.05% ointment twice daily provided minimal improvement. Given recurrence of the eczematous dermatitis, the patient was initiated on subcutaneous dupilumab 600mg, followed by 300mg one week later and every other week thereafter, with no recurrence of significant eczematous eruption and MRSA infection.

Case Discussion

Due to the presence of suppurative nodules along the lymphatic pathways of drainage, a diagnosis of nodular lymphangitis was favored. Classically, the infectious causes of nodular lymphangitis are *Sporothrix schenckii*, *Nocardia brasiliensis*,

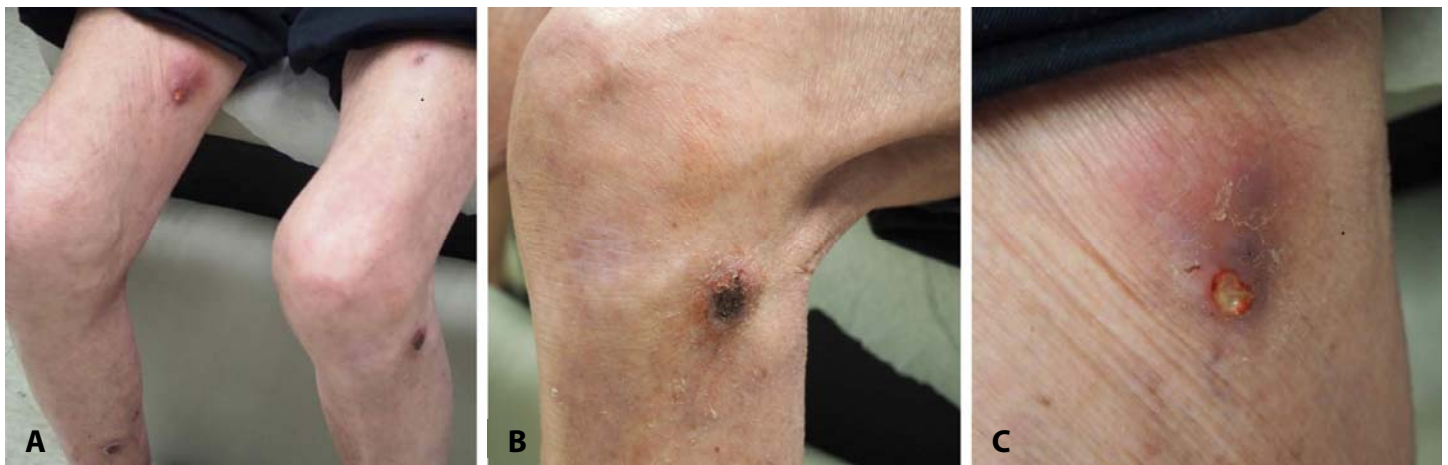

Figure 2. Histopathologic specimens from patient nodules. Superficial-to-deep suppurative inflammation. H&E, **A)** 25x, and **B)** 4x. **C)** Gram stain showing gram-positive cocci in clusters at high power, 400x.

Mycobacterium marinum, or *Leishmania braziliensis* [1]. Diagnostic clues include travel history, environmental exposures, incubation time, presence or absence of systemic involvement, and presence of ulceration, suppuration, or drainage [1]. Symptoms may predict etiology, i.e., nodular lymphangitis with *Leishmania braziliensis* is often non-purulent and painless, whereas purulent causes of nodular lymphangitis include *Staphylococcus aureus*, *Streptococcus pyogenes*, *Nocardia asteroides*, and other *Nocardia* species [1].

Infection with *Staphylococcus aureus* is a rare cause of nodular lymphangitis [1]. Previous cases of nodular lymphangitis due to *Staphylococcus aureus* have been described in both immunocompetent and immunocompromised patients [3-6]. However, the majority of reported cases were caused by methicillin-sensitive *Staphylococcus aureus* [3-6], with the exception of one case in a premature neonate at intravenous line sites [7]. The case presented herein is unique both because of the causative organism (MRSA) and lack of known injury or inoculation site. Nodular lymphangitis due to *Staphylococcus aureus* is infrequently reported, but both methicillin-sensitive and methicillin-resistant *Staphylococcus aureus* are common causes of

lymphangitic streaking [8]. The recent prednisone course may have predisposed our patient to MRSA infection, but the patient had other MRSA risk factors, including a diagnosis of diabetes mellitus [9]. Additionally, the incidence of community-acquired MRSA has been increasing [10].

Conclusion

Although rare, nodular lymphangitis can occur due to infection with *Staphylococcus aureus* [1]. In a patient presenting with nodular lymphangitis with no travel or exposure history, *Staphylococcus aureus* infection should be considered. Gram stain and bacterial culture should be included in diagnostic testing for nodular lymphangitis in appropriate patients. Nodular lymphangitis due to *Staphylococcus aureus* typically presents with nodular lesions, often forming abscesses with drainage of purulent fluid [1]. Due to increasing antibiotic resistance, an antibiotic sensitivity profile should guide therapeutic selection.

Potential conflicts of interest

The authors declare no conflicts of interest.

References

1. Tirado-Sánchez A, Bonifaz A. Nodular Lymphangitis (Sporotrichoid Lymphocutaneous Infections). Clues to Differential Diagnosis. *J Fungi*. 2018;4:56. [PMID: 29747448].
2. Giordano CN, Kalb RE, Brass C, et al. Nodular lymphangitis: Report of a case with presentation of a diagnostic paradigm. *Dermatol Online J*. 2010;16:1. [PMID: 20875322].
3. Lieberman AA, Grossman ME, Bloomgarden D. Sporotrichoid Lymphangitis Due to *Staphylococcus aureus* in a Diabetic Patient. *Clin Infect Dis*. 1995;21:433-4. [PMID: 8562757].
4. Tanaka S, Mochizuki T, Watanabe S. Sporotrichoid Pyogenic Bacterial Infection. *Dermatology*. 1989;178:228-30. [PMID: 2670620].
5. Jacobson-Dunlop E, Takiguchi R, Ward T, et al. Sporotrichoid *Staphylococcus aureus* Infection in an Immunosuppressed Patient. *Arch Dermatol*. 2010;146:1435-7. [PMID: 21173335].
6. Rotemberg V, Valins W, Husan S, Grossman M. *Staphylococcus aureus* sporotrichoid lymphangitis without bacteremia in a transplant recipient. *Transpl Infect Dis*. 2015;17:137-9. [PMID: 25582343].
7. McDonald HH, Dehesa L, Gilson RT. Erythematous subcutaneous nodules in a neonate. *Pediatr Dermatol*. 2017;34:103-104. [PMID: 28054721].
8. Kimia R, Voskoboynik B, Hudgins JD, et al. Is lymphangitis streaking associated with different pathogens? *Am J Emerg Med*. 2021;46:34-37. [PMID: 33714052].
9. Kutlu SS, Cevahir N, Akalin S, et al. Prevalence and risk factors for methicillin-resistant *Staphylococcus aureus* colonization in a diabetic outpatient population: a prospective cohort study. *Am J Infect Control*. 2012;40:365-8. [PMID: 21864943].
10. David MZ, Daum RS. Community-associated methicillin-resistant *Staphylococcus aureus*: epidemiology and clinical consequences of an emerging epidemic. *Clin Microbiol Rev*. 2010;23:616-87. [PMID: 20610826].