

UC Davis

Dermatology Online Journal

Title

Florid cutaneous papillomatosis as a marker of neoplastic recurrence

Permalink

<https://escholarship.org/uc/item/5qr833n1>

Journal

Dermatology Online Journal, 24(8)

Authors

Esteves, M
Antunes, I
Azevedo, F

Publication Date

2018

DOI

10.5070/D3248041140

Copyright Information

Copyright 2018 by the author(s). This work is made available under the terms of a Creative Commons Attribution-NonCommercial-NoDerivatives License, available at <https://creativecommons.org/licenses/by-nc-nd/4.0/>

Peer reviewed

Florid cutaneous papillomatosis as a marker of neoplastic recurrence

M Esteves, I Antunes, F Azevedo

Affiliations: Department of Dermatology and Venereology, Centro Hospitalar de São João EPE, Porto, Portugal

Corresponding Author: Mariana Esteves MD, Centro Hospitalar São João EPE, Porto, Alameda Professor Hernâni Monteiro, 4200-319 Porto, Portugal, E-mail: mariana.cbesteves@gmail.com

Abstract

Florid cutaneous papillomatosis is a rare paraneoplastic dermatosis, most commonly associated with gastric adenocarcinoma. It is characterized by a sudden onset of hyperkeratotic papules, clinically indistinguishable from viral warts. We report an 80-year-old man who presented to our department with a two-month history of multiple verrucous lesions affecting the face, perioral region, and hands. Two years before, he was treated for a gastric adenocarcinoma with a subtotal gastrectomy, but showed no evidence of residual disease or recurrence. Given the clinical background, a diagnosis of florid cutaneous papillomatosis was considered. Skin biopsy excluded a viral origin, and tumour recurrence was later identified through an abdominal ultrasound. The onset of this entity is typically prior or concurrent with the diagnosis of the internal malignancy, but it may also represent the first sign of recurrence of a previously treated neoplasm. Its early recognition is essential to ensure a thorough investigation and prompt treatment.

Keywords: florid cutaneous papillomatosis, paraneoplastic dermatosis, gastric adenocarcinoma

Introduction

Florid cutaneous papillomatosis (FCP) is a rare condition characterized by the abrupt appearance of numerous verrucous papules on the face, trunk, and extremities, that are morphologically identical to viral warts [1-12]. It is considered an obligatory paraneoplastic dermatosis, as it is always associated with an internal malignancy [1-4].

Case Synopsis

An 80-year-old man was referred to our department for verrucous pruritic lesions affecting the face, perioral region, and hands that had rapidly developed over the past two months. He had a previous medical history of a gastric adenocarcinoma stage pT4N3M0, diagnosed two years before and treated with a subtotal gastrectomy with regional lymphadenectomy. Histological examination of the surgical piece confirmed complete resection and the patient was kept under periodic medical surveillance. Computed tomography scans and an upper gastrointestinal endoscopy showed no evidence of residual disease or recurrence; therefore, no adjuvant therapy was instituted.

At our first consultation, the patient complained of fatigue and mild dysphagia. On physical examination, he exhibited confluent papillomatosis

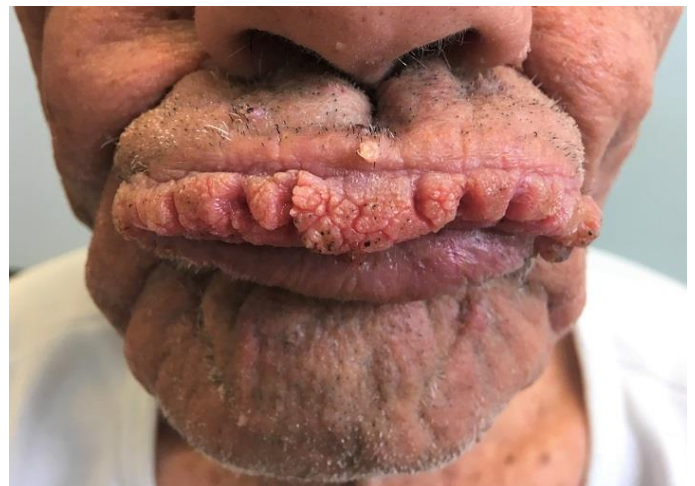

Figure 1. Confluent papillomatous lesions across the upper lip vermilion.

across the upper lip vermilion, diffusely affecting the tongue (Figure 1). Skin-colored hyperkeratotic papules were also visible on the cheeks and dorsa of the hands, morphologically resembling verrucae vulgaris (Figure 2). There were no other relevant cutaneous lesions and the remaining clinical examination was unremarkable.

A cutaneous biopsy was performed on the upper lip lesions. Histopathologic analysis revealed papillary architecture with hyperkeratosis but no evidence of koilocytes or other typical features of viral cytopathic effect (Figure 3). There was no presence of human papillomavirus on the biopsy specimen by polymerase chain reaction.

During the month that followed our first consultation, the patient experienced a rapid deterioration of his general health status. He complained of significant fatigue and dysphagia and he began experiencing epigastric pain, nausea, and vomiting. Serial analytical studies revealed a progressive elevation of inflammatory parameters and lactate dehydrogenase, as well as hyperbilirubinemia and increased cholestasis markers. An abdominal ultrasound showed multiple mesenteric and retroperitoneal lymphadenopathies (up to 40mm in diameter) that were not previously

present and were considered highly suggestive of progression of the gastric neoplasia. The patient was admitted to the department of internal medicine for further investigation and treatment but died the day after.

Case Discussion

Florid cutaneous papillomatosis, also known as Schwartz-Burgess syndrome, is a rare paraneoplastic dermatosis that was first described by Pollitzer in 1891 but named only in 1978 [1-4]. The largest literature review was conducted by Gheeraert in 1991 and identified 23 cases of FCP [1]. It appears to occur two times more frequently in men and has its peak incidence between the ages of 53 and 72 years [1-3], although there are reports of an earlier onset [8]. Every patient diagnosed with this condition has an underlying known or occult malignancy. The most commonly reported neoplasia is gastric adenocarcinoma [1-12]. However, it may occur in association with other intraabdominal malignancies, as well as lung or breast carcinoma and lymphoproliferative disorders [1-3, 10, 11].

Clinically, FCP presents as a sudden eruption of multiple verrucous papules and nodules resembling clusters of verrucae vulgaris [1-9]. These first appear on the extremities, particularly on the dorsa of hands and wrists and may later spread to involve the trunk, the face, and even the entire body. Lesions can also affect the oral mucosa [4-7, 11], as was evident in our case. Pruritus is typically an important feature, either limited to the affected areas or generalized; sometimes it is the first clinical symptom, prior to the onset of cutaneous lesions [1-4]. In unusual cases, an extensive growth of the lesions may occur, leading to significant physical disfigurement and social exclusion [8, 9].

Histopathologic findings include papillomatosis and pronounced hyperkeratosis with irregular acanthosis. Epidermal vacuolization, parakeratosis, eosinophilic inclusions, or other typical microscopic features of common viral warts are not present [1-4, 7, 12]. Attempts to detect human papillomavirus DNA in skin biopsy specimens are negative [1-3],

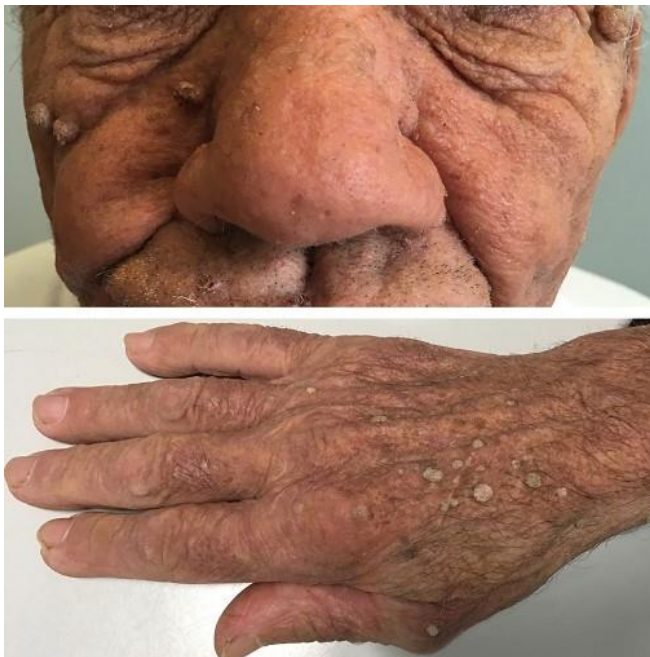

Figure 2. Hyperkeratotic warty papules on the cheeks and dorsa of the hands.

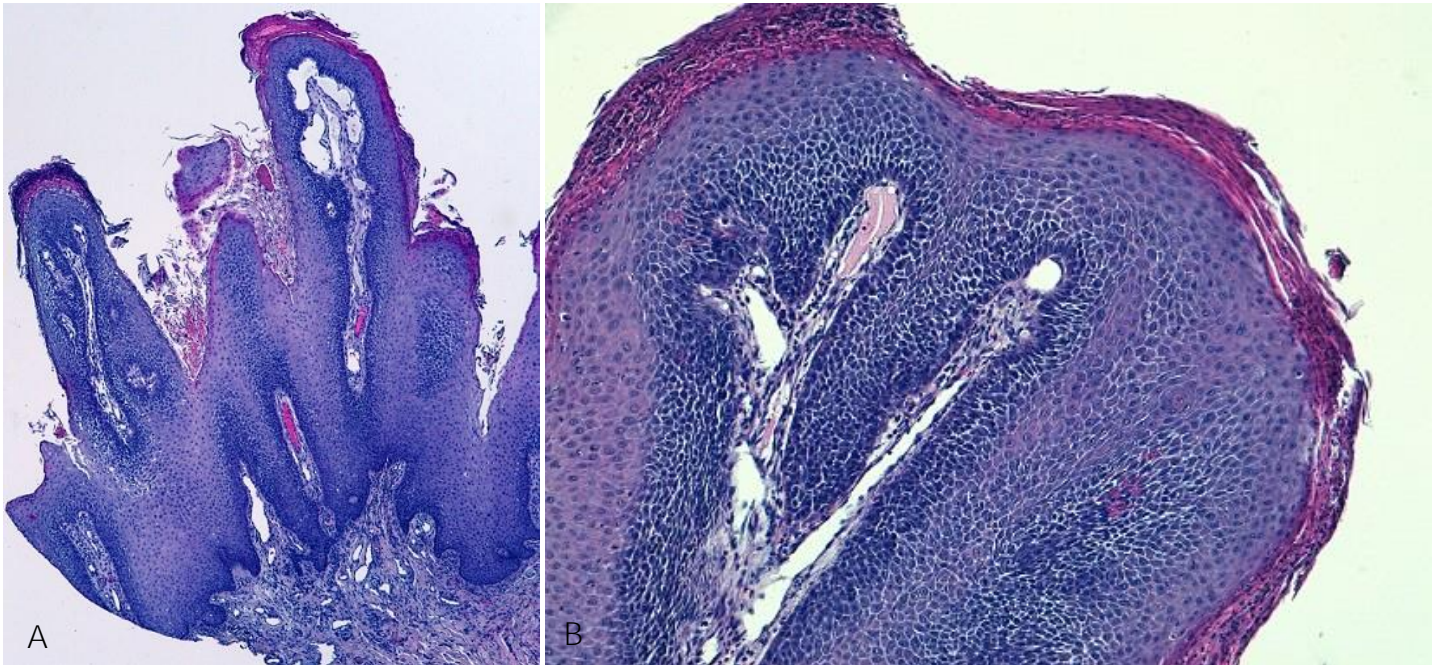


Figure 3. Histopathological analysis revealing a pavementous lesion of papillary architecture with hyperkeratosis. H&E, A) 40 \times , B) 100 \times .

thus making the hypothesis of an infectious etiology unlikely.

Florid cutaneous papillomatosis is considered by some authors to be a clinical variant of malignant acanthosis nigricans (MAN), along with other signs of internal malignancy, especially tripe palms and the sign of Leser-Trélat. The simultaneous presence of these paraneoplastic markers has been described before in the literature [4, 5, 7, 10, 12], although each one of them can develop as an isolated dermatosis. In our patient, even though other cutaneous manifestations of MAN were not present at the time of diagnosis, FCP lesions may have represented the first sign of this continuum, as has been reported [6].

The association between these different paraneoplastic manifestations suggests that they are most likely induced by the underlying malignancy and that they share a common pathogenic pathway. The exact mechanism still remains to be fully understood, but a current hypothesis suggests that the secretion of transforming growth factor- α and other active mediators by the tumor into the circulation induces mitotic and antiapoptotic effects on the epidermal keratinocytes by activation of tyrosine kinases [3-7, 9, 10].

As with other paraneoplastic syndromes, the onset of FCP is frequently prior or concurrent with the diagnosis of the primary malignancy [1-4, 6]. Nevertheless, in rare cases, it manifests later and may even represent the first sign of relapse of a previously treated neoplasm [11]. That was the case in our patient, in which FCP lesions preceded identification of tumor recurrence by several weeks. It is also noteworthy that the dermatosis shows a parallel course with the evolution of the tumor, given that reappearance or exacerbation of skin lesions follow local progression or distant metastases [1-4, 6, 7, 12], establishing its role as a cutaneous neoplastic marker.

The main therapeutic intervention should be aimed at the treatment of the underlying neoplasm, either through surgery or chemotherapy [3, 6, 12]. Results are often unsatisfactory [9, 12]; still, significant improvement of FCP lesions may be found in up to one-third of treated patients [4]. Local therapy of skin lesions can be attempted with a palliative intention. Topical treatments include 5-fluorouracil, calcipotriol, retinoids, podophyllotoxin, or liquid nitrogen [3, 6, 9, 12], with variable clinical results. Systemic retinoids constitute another possible

approach, with mild reduction of oral papillomatosis being reported following acitretin [12].

Conclusion

Of particular interest in the present case is the appearance of FCP lesions years after treatment of an internal malignancy, preceding the diagnosis of tumor recurrence. To the best of our knowledge,

there is only one case published in the literature in which this paraneoplastic dermatosis followed a similar clinical course.

In conclusion, this case highlights the value of FCP as a neoplastic marker. Early recognition of this entity by clinicians is of utmost importance to ensure a complete investigation and prompt treatment of an occult malignancy or neoplastic recurrence.

References

1. Gheeraert P, Goens J, Schwartz RA, Lambert WC, Schroeder F, Debusscher L. Florid Cutaneous Papillomatosis, Malignant Acanthosis Nigricans, and Pulmonary Squamous Cell Carcinoma. *Int J Dermatol*. 1991;30(3):193-97. [PMID: 2037404].
2. Schwartz RA. Florid Cutaneous Papillomatosis. *Clin Dermatol*. 1993;11(1):89-91. [PMID: 8339205].
3. Janniger EJ, Schwartz RA. Florid Cutaneous Papillomatosis. *J Surg Oncol*. 2010;102(6):709-12. [PMID: 20973109].
4. Brinca A, Cardoso JC, Brites MM, Tellechea O, Figueiredo A. Florid Cutaneous Papillomatosis and Acanthosis Nigricans Revealing Gastric Adenocarcinoma. *An Bras Dermatol*. 2011;86(3):573-77. [PMID: 21738980].
5. Vilas-Sueiro A, Suárez-Amor Ó, Monteagudo B, de las Heras C. Acanthosis nigricans maligna, papilomatosis cutáneo-mucosa florida y paquidermatoglifia adquirida en paciente con adenocarcinoma gástrico. *Actas Dermosifiliogr*. 2015;106(5):438-39. [PMID: 25544016].
6. Klieb HB, Avon SL, Gilbert J, Sade S, Enepekides D. Florid Cutaneous and Mucosal Papillomatosis: Mucocutaneous Markers of an Underlying Gastric Malignancy. *J Clin Oncol*. 2013;31(13):e218-19. [PMID: 23530104].
7. Yang YH, Zhang RZ, Kang DH, Zhu WY. Three paraneoplastic signs in the same patient with gastric adenocarcinoma. *Dermatol Online J*. 2013;19(7):18966. [PMID: 24010512].
8. Singhi MK, Gupta LK, Bansal M, Jain V, Kachhawa D. Florid cutaneous papillomatosis with adenocarcinoma of stomach in a 35 year old male. *Indian J Dermatol Venereol Leprol*. 2005;71(3):195-96. [PMID: 16394412].
9. Csete B, Moezzi M, Lengyel Z, Hodosi B, Zombai E, Battyáni Z. Florid cutaneous papillomatosis leading to social exclusion. *Br J Dermatol*. 2005;153(3):667-69. [PMID: 16120165].
10. Bottoni U, Dianzani C, Pranteda G, Innocenzi D, De Giacomo P, Balzani A, Zampetti M, Pala S, Calvieri S. Florid cutaneous and mucosal papillomatosis with acanthosis nigricans revealing a primary lung cancer. *J Eur Acad Dermatol Venereol*. 2000;14(3):205-8. [PMID: 11032067].
11. Schulmann K, Strate K, Pox CP, Wieland U, Kreuter A. Paraneoplastic Acanthosis Nigricans with Cutaneous and Mucosal Papillomatosis Preceding Recurrence of a Gastric Adenocarcinoma. *J Clin Oncol*. 2012;30(32):e325-26. [PMID: 23008315].
12. Stawczyk-Macieja M, Szczerkowska-Dobosz A, Nowicki R, **Majewska H, Dubowik M, Sokołowska-Wojdyło M.** Malignant acanthosis nigricans, florid cutaneous papillomatosis and tripe palms syndrome associated with gastric adenocarcinoma. *Postepy Dermatol Alergol*. 2014 Feb;31(1):56-8. [PMID: 24683401].