

UC Davis

Dermatology Online Journal

Title

Hobnail Hemangioma on the Trunk

Permalink

<https://escholarship.org/uc/item/5nx224k2>

Journal

Dermatology Online Journal, 19(5)

Authors

Krishna, C. Vijay
Reddy, G. Madhusudhan
Senthil Kumar, A. L.
et al.

Publication Date

2013

DOI

10.5070/D3195018179

Copyright Information

Copyright 2013 by the author(s). This work is made available under the terms of a Creative Commons Attribution-NonCommercial-NoDerivatives License, available at <https://creativecommons.org/licenses/by-nc-nd/4.0/>

Peer reviewed

Photo Vignette

Hobnail Hemangioma on the Trunk

C.Vijay Krishna MD, G. Madhusudhan Reddy MBBS, Senthil Kumar A.L. MBBS, A.Vijaya Mohan Rao MD

Dermatology Online Journal 19 (5): 10

Department of Dermatology, Venereology, and Leprology, Narayana Medical College & Hospital, Nellore-524002, India

Correspondence:

C. Vijay Krishna, MD
Assistant Professor,
Department of Dermatology,
Narayana Medical College & Hospital,
Nellore-524002, India
E-mail: vijay_postgradmed@yahoo.com
Phone No: 91-9491042940
Fax: 91- 0861 - 2331763

Abstract

Hobnail hemangioma is a rare, benign vascular growth that typically presents in the third and fourth decades of life. It classically presents as a targetoid lesion with a violaceous central papule surrounded by a peripheral ecchymotic rim. Common sites of involvement include extremities and trunk. We present this case of hobnail hemangioma in a 10-year-old boy because of its rarity.

Keywords: Hobnail Hemangioma

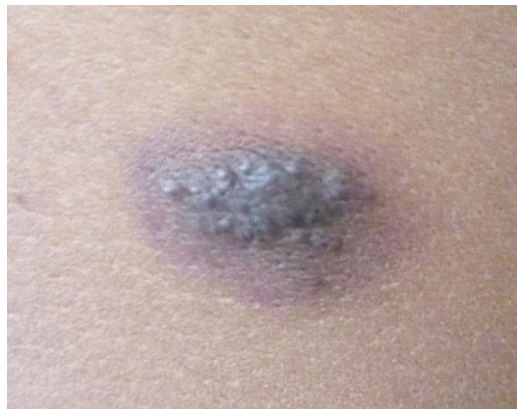


Figure 1. A well-defined plaque on the trunk with a violaceous centre and ecchymotic rim giving a “targetoid” appearance

Case synopsis

A 10-year-old boy presented with a 7-year history of a single, asymptomatic plaque on the right side of the trunk (Fig. 1). The lesion started as an erythematous papule and later gradually increased in size. Cutaneous examination revealed a single non-tender oval plaque of 2x3 cm, present on the right side of the trunk. The plaque had a violaceous center and a peripheral ecchymotic rim, giving a targetoid appearance. The remainder of the skin examination was unremarkable. There was no history of fluid filled lesions, trauma, or insect bite preceding the lesion. The boy was otherwise in good health. A punch biopsy was performed from the for histopathological examination (Fig. 2,3 & 4).

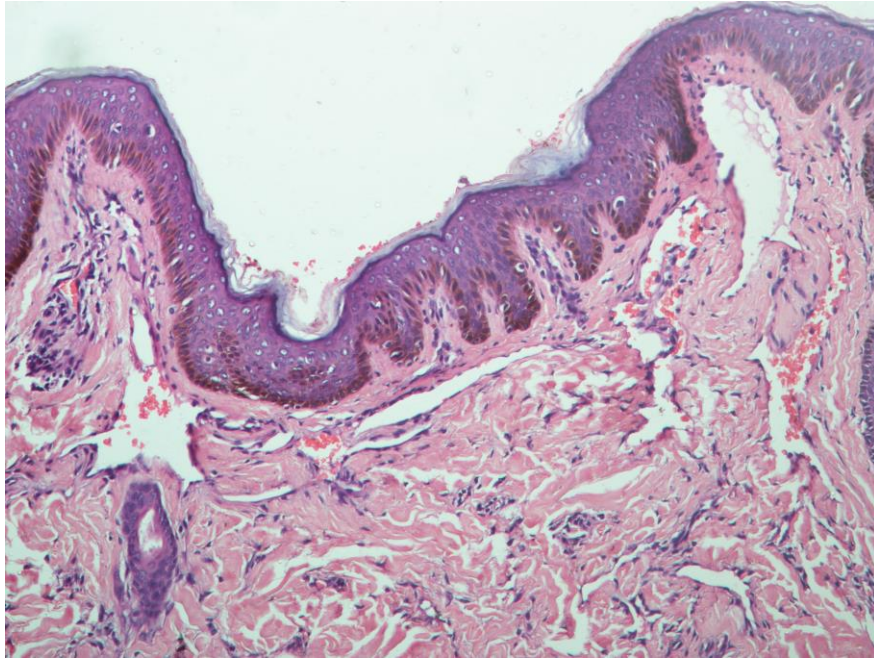


Figure 2. Proliferation of dilated thin walled mature capillaries within the superficial dermis. Within the lower dermis the proliferation was less prominent, and was made up of angulated capillaries that extended interstitially (H & E x100)

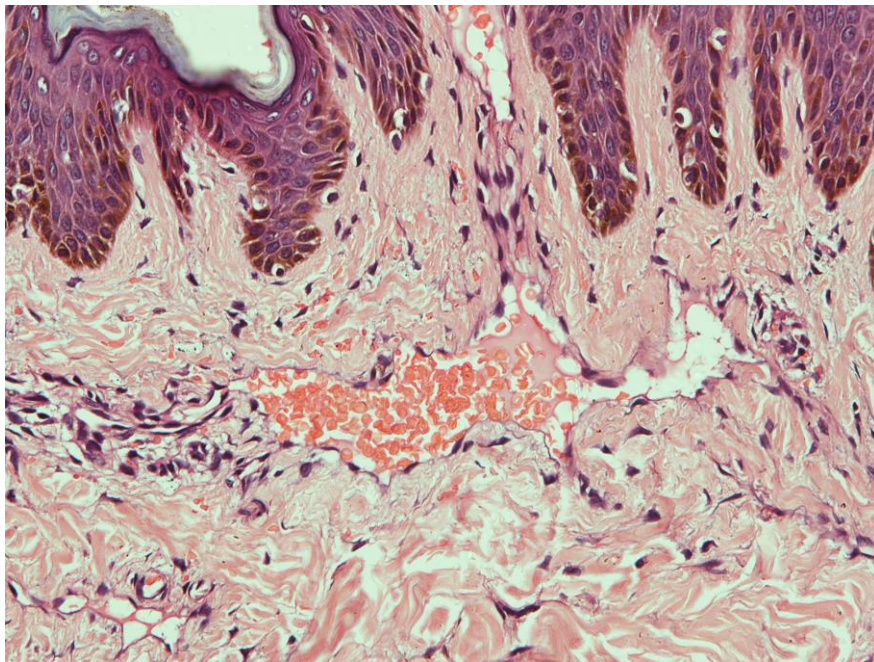


Figure 3. A few capillaries in superficial plexus showed prominent plump endothelial cells projecting into the lumina resembling "hobnails" (H& E x200)

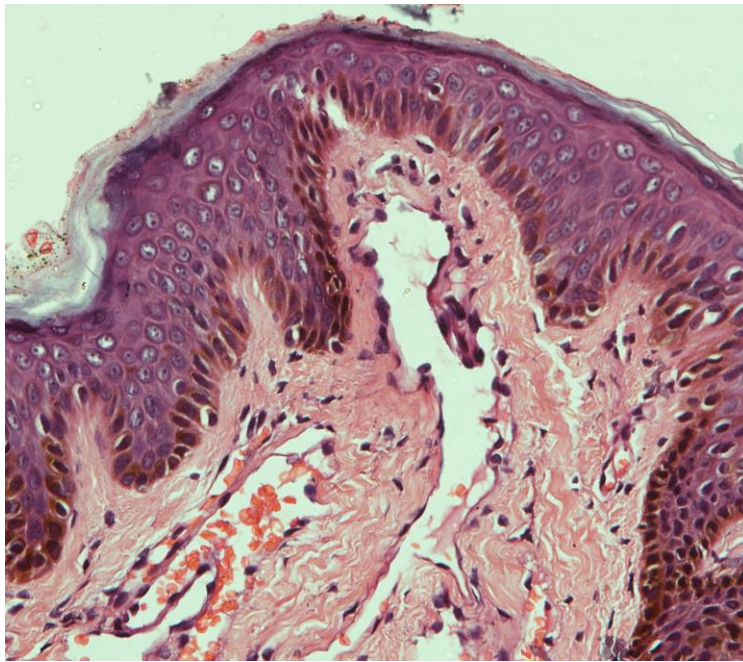


Figure 4. Focally, intraluminal papillary projections could be seen within the capillaries (H& E x200)

CD31 immunostaining was strongly positive. D2-40 marker was not done owing to unavailability. The lesion was subsequently excised and there has been no recurrence after six months of follow-up.

Discussion

Hobnail hemangioma, also known as targetoid hemosiderotic hemangioma (THH), is a benign vascular tumor generally confined to the superficial and mid dermis. THH was first reported in 1988 by Santa Cruz and Aronberg [1]. The term hobnail hemangioma was coined by Guillou et al [2] because of the hobnail-like appearance of the endothelial cells. Published reports of hobnail hemangioma reveal a slight male preponderance with an age range of 5 to 72 years, more common in the third and fourth decades of life [3]. The etiology of hobnail hemangioma is unclear, but trauma [4] to a preexisting hemangioma and the influences of sex steroid hormones [5] have been proposed. Hobnail hemangioma classically presents as a single, annular, targetoid, brown to violaceous central papule surrounded by a thin pale area and a peripheral ecchymotic ring that can expand or subsequently disappear with persistence of the central papule. The characteristic targetoid appearance is owing to peripheral hemorrhage and hemosiderin deposition. Atypical presentations include macular, popular, and non-targetoid forms. Lesions are usually less than 1 cm in diameter and are most commonly seen on proximal extremities and trunk. The clinical differential diagnosis includes microcystic lymphatic malformation into which bleeding has occurred, melanocytic nevus, infantile hemangioma, tufted angioma, Kaposi's sarcoma, and insect bite reaction. The clinical setting is helpful in differentiating these entities because hobnail hemangioma occurs as a small, solitary, asymptomatic, lesion in an otherwise healthy individual. Microcystic lymphatic malformation appears as skin-colored pseudovesicles, resembling frogspawn. Lesions of Kaposi sarcoma are multiple and of variable size.

Histopathologic features of hobnail hemangioma vary according to the duration or age of the individual lesion. Characteristic features of early lesions in the superficial dermis are irregularly dilated vessels lined by hobnail endothelial cells. The hobnail (matchstick appearing) endothelial cells have scanty cytoplasm and rounded nuclei that protrude into the lumina. Focally, intraluminal papillary projections and fibrin thrombi can be seen in superficial blood vessels. In the deeper dermis, the vascular spaces are slit-like and appear to dissect through collagen bundles. In the later stages, lesions show collapsed vascular lumina, fibrosis, and hemosiderin deposition. In one series, the tumor cells stained for CD31 in all cases studied, whereas only 3 out of 28 cases stained completely for CD34 [6]. Recently, Frank et al [7] supported the lymphatic origin of hobnail hemangioma using the lymphatic endothelial cell marker D2-40 positivity and CD34 negativity in most but not all cases. The histological differential diagnosis of hobnail hemangioma includes the family of vascular tumors characterized by epithelioid endothelial cells. Hobnail hemangioma represents the benign end of the spectrum of this group, which also includes Dabska tumor and retiform hemangioendothelioma. In addition, angiosarcoma and Kaposi sarcoma should also be considered in the differential diagnosis. Angiosarcoma can be differentiated from hobnail hemangioma by the presence of cellular atypia in the former. Factors that favor Kaposi sarcoma [8] are the presence of plasma cells and spindle-shaped cells, apoptotic endothelial cells, and HHV-8 positivity. Hobnail

hemangioma is benign. Therefore, local excision or excisional biopsy may be done. Recurrence after excision has not been reported.

References

1. Santa Cruz DJ, Aronberg J. Targetoid hemosiderotic hemangioma. *J Am Acad Dermatol* 1988; 19(3):550–8. [PMID: 3170814]
2. Guillou L, Calonje E, Speight P, Rosai J, Fletcher CD. Hobnail haemangioma: a pseudomalignant vascular lesion with a reappraisal of targetoid hemosiderotic haemangioma. *Am J Surg Pathol* 1999; 23(1):97–105. [PMID: 9888709]
3. Ibrahim M, Shwayder T. Hobnail hemangioma in a nine-year old boy: a rare case presented with dermoscopy. *Dermatol Online J* 2010; 16(4): 7. [PMID: 20409414]
4. Christenson LJ, Stone MS. Trauma-induced simulator of targetoid hemosiderotic hemangioma. *Am J Dermatopathol* 2001;23(3):221-223. [PMID: 11391103]
5. Morganroth GS, Tigelaar RE, Longley BJ, Luck LE, Leffell DJ. Targetoid hemangioma associated with pregnancy and the menstrual cycle. *J Am Acad Dermatol* 1995;32(2 Pt 1):282-284. [PMID: 7829718]
6. Mentzel T, Partanen TA, Kutzner H. Hobnail hemangioma (“targetoid hemosiderotic hemangioma”): clinicopathologic and immunohistochemical analysis of 62 cases. *J Cutan Pathol* 1999;26(6):279-286. [PMID: 10472756]
7. Franke FE, Steger K, Marks A, Kutzner H, Mentzel T. Hobnail hemangiomas (targetoid hemosiderotic hemangiomas) are true lymphangiomas. *J Cutan Pathol* 2004;31(5):362-7. [PMID: 15059220]
8. Chor PJ, Santa Cruz DJ. Kaposi's sarcoma. A clinicopathologic review and differential diagnosis. *J Cutan Pathol* 1992;19(1):6-20. [PMID:1556269]