

# UC Davis

## Dermatology Online Journal

### Title

A curious case of blue-green discoloration in a middle-aged indian man: Chromhidrosis

### Permalink

<https://escholarship.org/uc/item/5jj4859x>

### Journal

Dermatology Online Journal, 21(11)

### Authors

Ghosh, Sudip Kumar  
Rudra, Olympia  
Kar, Rajarshi  
et al.

### Publication Date

2015

### DOI

10.5070/D32111029289

### Copyright Information

Copyright 2015 by the author(s). This work is made available under the terms of a Creative Commons Attribution-NonCommercial-NoDerivatives License, available at <https://creativecommons.org/licenses/by-nc-nd/4.0/>

Peer reviewed

## Case presentation

### A curious case of blue-green discoloration in a middle-aged indian man: Chromhidrosis

Sudip Kumar Ghosh MD DNB<sup>1</sup>, Olympia Rudra MD<sup>1</sup>, Rajarshi Kar MD<sup>2</sup>, Arghyaprasun Ghosh MD<sup>1</sup>, Megha Agarwal MBBS<sup>1</sup>

Dermatology Online Journal 21 (11): 9

<sup>1</sup>Department of Dermatology, Venereology, & Leprosy, R.G.Kar Medical College, Kolkata-700004, W.B. India.

<sup>2</sup>Department of Biochemistry, UCMS, Delhi-95, India.

## Correspondence:

Sudip Kumar Ghosh  
Department of Dermatology, Venereology, & Leprosy,  
R.G.Kar Medical College, Kolkata-700004, W.B. India.  
e-mail: dr\_skghosh@yahoo.co.in

---

## Abstract

**Introduction:** Chromhidrosis is a rare sweat gland disorder characterized by the excretion of colored sweat. It can be classified as apocrine, true eccrine, and pseudochromhidrosis. Amongst the different types of chromhidrosis, green chromhidrosis is extremely rare. We describe herein a case of blue green chromhidrosis induced by ingestion of homeopathic medicine.

**Case report:** A middle aged man presented to us with blue green discoloration of hands and feet. There was a preceding history of ingestion of homeopathic medication. Histopathology from the involved skin showed greenish particles within eccrine glands. Initial blood copper level was high which returned to normal level after discontinuation of the homeopathic medicine. Spectrophotometry revealed high copper content of the green sweat.

**Conclusion:** Our case emphasizes the importance of considering any type of ingested medicine, including homeopathic medicine, as a probable cause of chromhidrosis.

**Keywords:** blue green, chromhidrosis, homeopathy

## Introduction

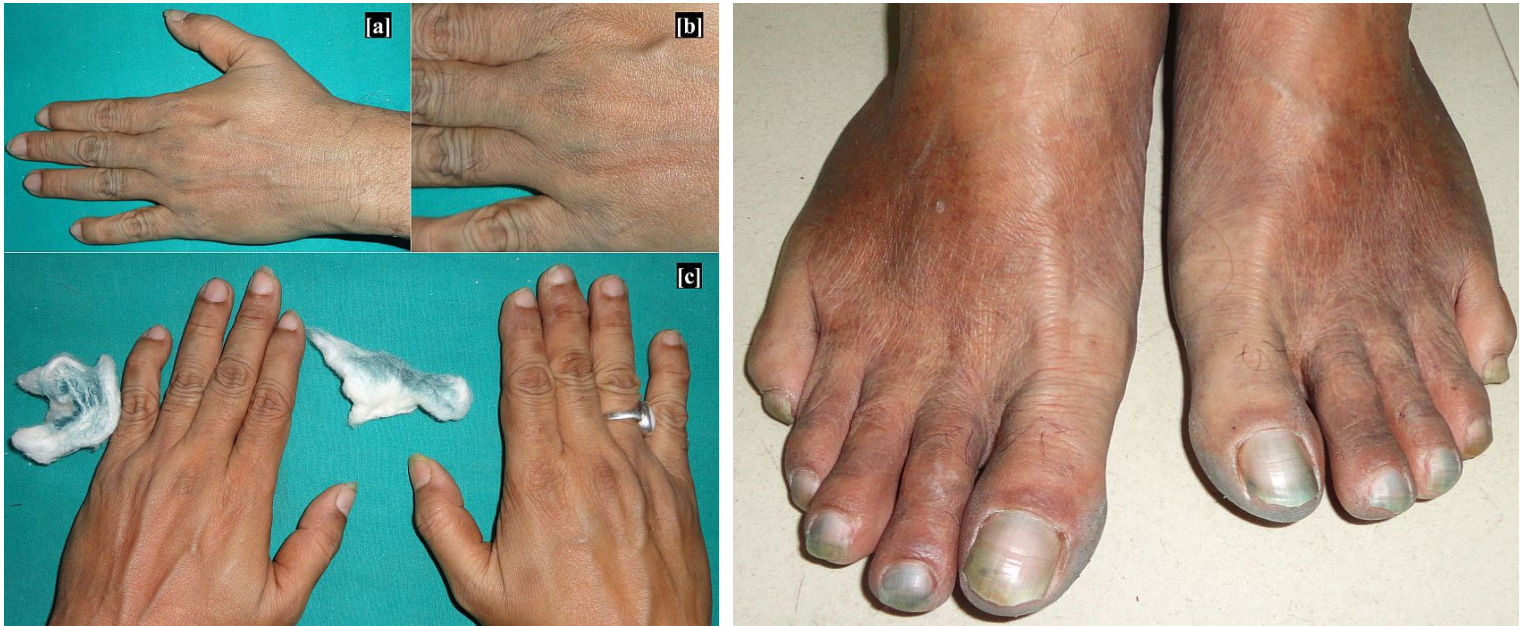Chromhidrosis is a rare sweat gland disorder characterized by the excretion of colored sweat [1, 2]. It can be classified as apocrine, true eccrine, and pseudochromhidrosis [2]. Apocrine chromhidrosis commonly occurs over the face and axilla and less frequently on the abdomen, chest, thighs, groin, and genitalia [3]. In comparison, eccrine chromhidrosis is relatively rarer [1, 2]. It usually occurs as a consequence of ingestion of exogenous dyes or drugs [1, 2]. Amongst the different colors of sweat, green chromhidrosis is extremely rare. On the other hand, homeopathic medicines are easily available over the counter and hence, they are indiscriminately being used in tropical countries like India. As a result of this, many cutaneous or extra-cutaneous side effects may occur which are often under-reported. We report here a case of blue green chromhidrosis induced by ingestion of homeopathic medicine.

## Case synopsis

A 54-year-old man presented with greenish discoloration of his hands and feet since the last two days. It was preceded by consumption of a homeopathic medication (which medication?) for upper respiratory tract infection for the last five days. There was no history of application of any topical medication, dye, or coloring agent in the recent past.

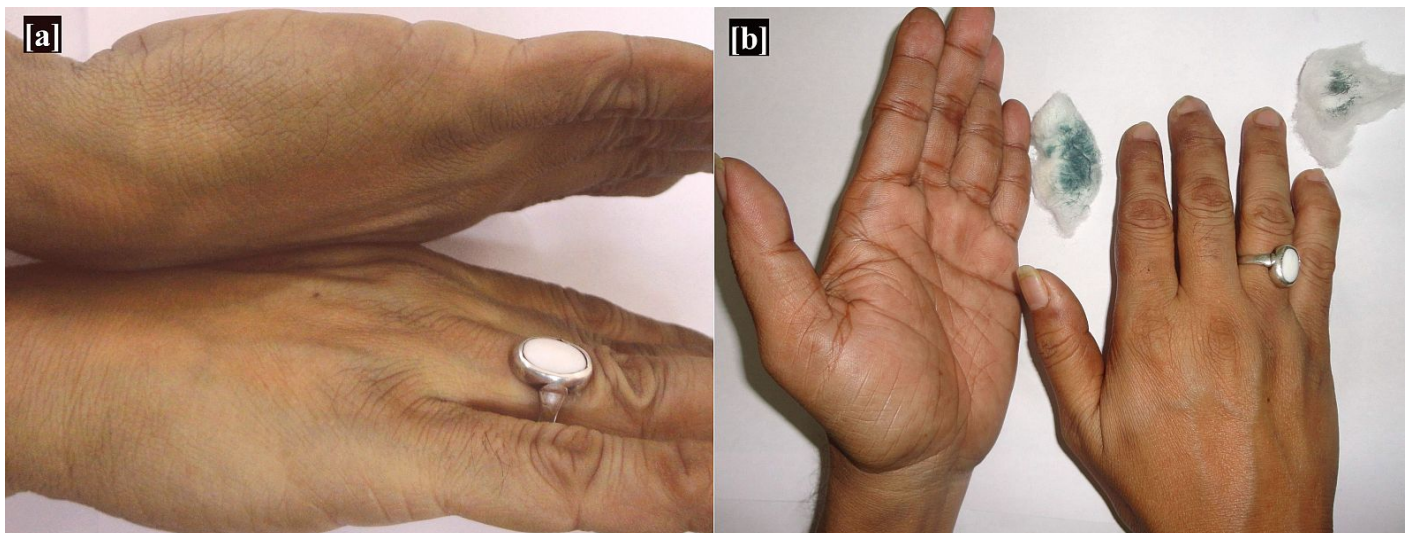
He did not take any other systemic medication and there was no occupational exposure to any chemicals or dyes. The greenish tinge first appeared over the dorsum of his hands and then gradually progressed to involve the palms, forearms, arms, legs, and feet.

The patient also noticed slight greenish coloration of undergarments. Examination revealed greenish discoloration over his hands, feet, and nails. {Figure 1 and 2}



**Figure 1.** [a and b] Blue green discoloration over the hands. [c] Blue green color, wiped off by cotton. **Figure 2.** Blue green discoloration involving nails and feet.

However, his axillae, areolar area, and groin were free from any discoloration. The patient's oral and nasal secretions, tears, urine and stool were all of normal color. Hair and mucosae were normal. The green color could be removed with cotton only to reappear again within a few minutes. {Figure 3} Interestingly, the color intensified after induction of sweating. The wiped-off secretion was odorless. Wood's lamp examination of the affected area showed no fluorescence. Systemic examination including psychological evaluation was non-contributory. His routine blood examination and biochemical panels including complete hemogram and liver function tests were normal. The patient's blood copper level at presentation was slightly raised (180  $\mu\text{g/dL}$ ) (normal range: 63.7-140.12  $\mu\text{g/dL}$ ).



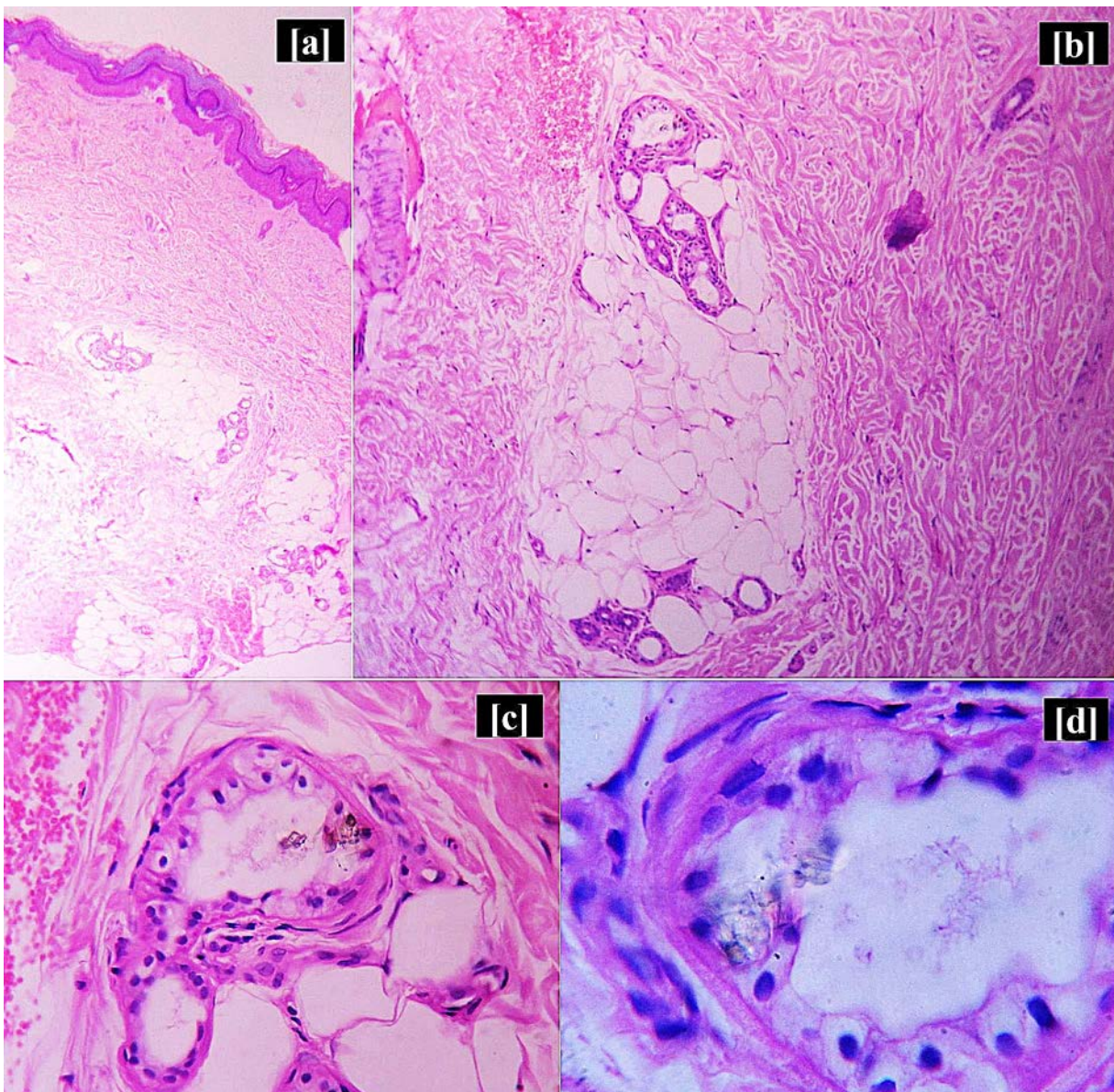
**Figure 3.** [a] Reappearance of the green color after exertion. [b] Cotton smeared with blue green sweat.



The patient was exerted to sweat and 0.5 ml of sweat was collected. The entire amount was absorbed in a filter paper and dried, and sent for analysis to detect the presence of copper.

The amount of copper content was analyzed by Graphite furnace atomic absorption spectrophotometer (Perkin Elmer, PinAAcle 900T).<sup>[4,5]</sup> The filter paper soaked with the patient's sweat was briefly digested with 10.0 mL of acid mixtures of HF, HNO<sub>3</sub> and HClO<sub>4</sub> (in 7:3:1 ratio) on hot plate at 200°C. The digested material was then evaporated to dryness. The residues were re-dissolved in 2% HNO<sub>3</sub> and analyzed by graphite furnace atomic absorption spectrometer (GFAAS). The measurement was done in triplicate and reagent blank was used to negate the presence of metals in the reagents and the filter paper. The copper content in sweat was 2.14 µg/ml which is much higher than expected (normal range: 0.3- 0.8 µg/ml). However, subsequent blood copper level (on 7<sup>th</sup> day) and 24-hour urinary copper level (on 2<sup>rd</sup> day) were within normal limits.

Ultrasonography of the whole abdomen was normal. Gram staining of the secretion was negative. Bacterial culture of the sweat grew out no organism. KOH preparation of the scrapings obtained from the affected area showed no fungal elements. A 4-mm punch biopsy specimen was obtained at the day of presentation from the medial aspect of palm where green color was most prominent. Histopathological examination revealed amorphous greenish particle within the eccrine glands. {Figure 4} The patient was followed up regularly. Greenish discoloration diminished a few days after discontinuation of the homeopathic medicine and completely resolved on the 14<sup>th</sup> day. Based on the clinical features and investigation findings, a diagnosis of green eccrine chromhidrosis was made. According to the causality assessment scales proposed by the World Health Organization Collaborating Centre for International Drug Monitoring, the Uppsala Monitoring Centre (WHO-UMC), and the Naranjo Adverse Drug Reaction Probability Scale, the causal role of homeopathic medicine in this case was 'probable'.



**Figure 4.** Histopathology of skin showing [a(HE stain x 40)] Hyperkeratosis and mild acanthosis [b(HE stain x 100)] Normal eccrine glands, [c(HE stain x 400)] and [d(HE stain x 1000)]: Eccrine gland containing greenish particles .

## Discussion

About 10% of people may have colored sweat that is considered to be acceptable and within the normal range [2]. This discoloration mainly occurs due to accumulation of breakdown product of tyrosine, melanin or heme, which is insoluble to fat solvents and can stain clothes [6]. In case of apocrine chromhidrosis, the secretion of colored sweat usually starts at puberty when the secretory function of apocrine gland begins [1, 7]. It gradually decreases with old age, owing to the natural regression of sweat glands [1, 7]. Sensations of warmth, pricking or tingling are sometimes experienced by the patient as premonitory symptoms, before appearance of apocrine secretion. Coloring may be intensified with emotional stimuli, exercise, and manipulation of skin [1].

In apocrine chromhidrosis, oxidized lipofuscin pigment granules are seen within apocrine glands in higher concentration and higher oxidative state [1, 2, 7]. More oxidized lipofuscins appear darker in color [1].

Eccrine chromhidrosis is usually lighter in color than its apocrine counterpart. The color may be blue, red, yellow or green. In such condition, water soluble pigment from certain dyes or drugs is excreted through eccrine sweat glands [8]. In case of the present patient, the temporal course of the condition favored the diagnosis of homeopathy drug- induced, blue-green eccrine chromhidrosis. Blue-green sweating may be seen in copper workers due to excessive occupational exposure to copper [2, 3, 6]. In view of this fact, we estimated the blood copper, urinary copper and copper content of the sweat.

As the blood copper level at presentation and the copper content of the sweat were high, we speculate that the homeopathy medicine (used by the patient) might have had high copper content.

Literature suggests that homeopathic formulations use copper metal in several tinctures like *Cuprum aceticum*, *Cuprum Arsenicosum*, *Cuprum Metallicum*, and *Cuprum Sulphuricum* amongst others [9]. However, the precise composition of the homeopathy medicine was not mentioned on the label of the products. Since the patient came to us with empty bottles of the medicine, we could not analyze the composition of the same, which is a limitation of this report. Green colored sweating may also occur rarely in a patient with liver failure or hyperbilirubinemia [3, 10]. Triwongwaranat et al reported a case of green eccrine chromhidrosis in patient with advanced intrahepatic cholangiocarcinoma and progressive jaundice [8]. Brown-colored direct bilirubin is secreted through the eccrine glands, converted to green-colored biliverdin by oxidative processes giving rise to green sweat in those patients [10].

Pseudochromhidrosis refers to the condition where colorless sweat turns colored after reaching the surface of the skin [1, 11, 12]. It occurs due to chromogenic or porphyrin-producing bacteria, fungus, and extrinsic dyes or paints [1, 2, 7, 11]. *Malassezia furfur*, *Bacillus* spp, *Corynebacterium*, and *Piedraia* are reported to cause pseudochromhidrosis [2, 6, 7, 12].

Apart from this, psychiatric evaluation is indispensable to rule out the possibilities of application of some substances to the skin in order to simulate a disease (dermatitis simulata) [6].

The diagnosis of chromhidrosis is essentially clinical. Wood's lamp examination is helpful in some cases [1] although it was not contributory in our case. Fungal and bacteriological cultures are often done to exclude infectious causes of pseudochromhidrosis.

Additionally, histopathological findings are often helpful in establishing the diagnosis. It is important to differentiate between apocrine, eccrine, and pseudochromhidrosis for the treatment and prognosis of a particular patient [12].

Apocrine chromhidrosis is usually difficult to treat due to its relapsing nature. There is no definite treatment option that targets the accumulation of lipofuscin. Therefore, treatment is usually targeted towards reducing the sweating. Topical capsaicin, 20% aluminium chloride hexahydrate solution, and botulinum toxin have been used in the treatment of apocrine chromhidrosis with variable success rate [3, 7, 12]. If eccrine chromhidrosis is suspected secondary to ingestion of drugs or exposure to dye, the offending agent should be eliminated [12]. The patient should be monitored regularly. Usually the color subsides within a few days, as was seen in our patient. Pseudochromhidrosis can be treated successfully with topical or systemic antibiotics or with antifungals. Avoidance of dyes, paints and proper counseling is also helpful in some cases of pseudochromhidrosis. To conclude, our case emphasizes the importance of considering ingested medicines, homeopathic or otherwise, as a probable cause of chromhidrosis.

## Reference

1. Zouboulis CC, Tsatsou F. Disorders of the apocrine sweat glands. In: Goldsmith LA, Katz SI, Gilchrist BA, Paller AS, Leffel DJ, Wolff K editors. Fitzpatrick's Dermatology in General Medicine. 8th ed. New York: The McGraw-Hill; 2012:947-59.
2. Rodríguez-Martín M, Rodríguez MS, Cabrera AN. Palmar and digital black pseudo-chromhidrosis: a case report. *Int J Dermatol* 2010; 49:562-4. [PMID: 20534093]
3. James WD, Berger TG, Elston DM. *Andrews' Diseases of the Skin: Clinical Dermatology*. 11th ed. Philadelphia: Saunders Elsevier; 2011.
4. Chakraborty P, Chakraborty S, Ramteke D, Chennuri K. Kinetic speciation and bioavailability of copper and nickel in mangrove sediments. *Marine pollution bulletin* 2014; 88: 224-230. [PMID: 25282180]
5. Chakraborty P, Ramteke D, Chakraborty S. Geochemical partitioning of Cu and Ni in mangrove sediments: Relationships with their bioavailability. *Mar Pollut Bull* 2015 ;93:194-201.[PMID: 25748786]
6. Leite RM, Nery NS. Dermatitis simulata: The mystery of the blue girl. *Int J Dermatol* 2007; 46:1317-9. [PMID: 18173538]
7. Pérez Tato B, Zamora Martínez E, Sánchez Albisua B, Pérez González YC, Polimón Olabarrieta I, Marinero Escobedo S, et al. Facial and axillary apocrine chromhidrosis. *Dermatol Online J* 2012; 18:13. [PMID: 22483524]
8. Triwongwanat D, Kasemsarn P, Boonchai W. Green pigmentation on the palms and soles. Acral green pigmentation (eccrine chromhidrosis). *JAMA Dermatol* 2013;149:1339-40. [PMID: 24026431]
9. Krupanidhi S, Sreekumar A, Sanjeevi CB. Copper & biological health. *Indian J Med Res*. 2008;128:448-61.[ PMID:19106440]
10. Narciso-Schiavon JL, Di Giunta G, André MH, Dimatos OC, Dantas-Corrêa EB, Nunes DH et al. Green sweat: an atypical finding in drug-induced liver disease. *Liver Int* 2014;34:816-7. [PMID:24373125]
11. Krishnam A S, Bharathi S, Krishnan S. An interesting case of bisacodyl (dulcolax)-induced chromhidrosis. *Indian J Dermatol Venereol Leprol* 2012;78:756-8.[ PMID:23075652]
12. Burggraaff JEC, Linthorst GE, Hoogerwerf JJ. Transient Blue Skin: Pseudo-chromhidrosis, *EJCRIM* 2014;1:doi: 10.12890/2014\_000084.

**Acknowledgment: The authors are grateful to Dr. Parthasarathi Chakraborty and Sucharita Chakraborty for analysis of copper content. The analysis was done in National Institute of Oceanology, Dona Paula, Goa, India.**