

UC Davis

Dermatology Online Journal

Title

Lymphomatoid papulosis and recurrent transitional cell carcinoma of the bladder: a paraneoplastic association

Permalink

<https://escholarship.org/uc/item/5751t3sj>

Journal

Dermatology Online Journal, 20(4)

Authors

Leong, WMS
Aw, CWD
Tan, KB

Publication Date

2014

DOI

10.5070/D3204022369

Copyright Information

Copyright 2014 by the author(s). This work is made available under the terms of a Creative Commons Attribution-NonCommercial-NoDerivatives License, available at <https://creativecommons.org/licenses/by-nc-nd/4.0/>

Letter

Lymphomatoid papulosis and recurrent transitional cell carcinoma of the bladder: a paraneoplastic association

WMS Leong¹, CWD Aw¹, KB Tan²

Dermatology Online Journal 20 (4): 17

¹Division of Dermatology, National University Hospital, Singapore

²Department of Pathology, National University Hospital, Singapore

Correspondence:

Wai Mun Sean Leong, M.B.B.S.
University Medicine Cluster
National University Hospital
5 Lower Kent Ridge Road
Singapore 119074
Phone: 67795555
Email: sean_wm_leong@nuhs.edu.sg

Abstract

Lymphomatoid papulosis is a rare, papulonodular skin eruption with histologic features of a CD30+ T cell lymphoma. We present a 79-year-old man with lymphomatoid papulosis and transitional cell carcinoma of the bladder.

Introduction

Lymphomatoid papulosis (LyP) is a rare, recurrent, self-healing papulonodular skin eruption with histologic features of a CD30+ malignant T cell lymphoma [1]. It belongs to a group of cutaneous CD30+ lymphoproliferative disorders, which includes cutaneous T cell lymphoma [2]. Patients with LyP are at risk of developing a second cutaneous or nodal lymphoma [3,4]. However, an association with transitional cell carcinoma (TCC) of the bladder has not been reported in the literature. This case illustrates a possible association between these two conditions.

Case synopsis

A 79-year-old man complained of a slightly itchy rash on the arms, neck, and shoulders for one year. Betamethasone-gentamicin cream previously afforded partial improvement.

Approximately 9 months prior to presentation at the dermatology clinic, he was diagnosed to have TCC of the bladder (T1G3) and had undergone a trans-urethral resection of bladder cancer (TURBT) in December 2006 and January 2007. His past history was significant for ischemic heart disease, cervical spondylosis, and dyspepsia, all of which were medically stable.

Examination revealed erythematous non-follicular nodules on the anterior arms and neck (Figure 1). There was no hepatosplenomegaly or peripheral lymphadenopathy.

Initial investigations comprising of a complete blood cell count and differential, renal and liver function tests, including serum lactate dehydrogenase, were within normal limits. A chest radiograph did not reveal any hilar enlargement.

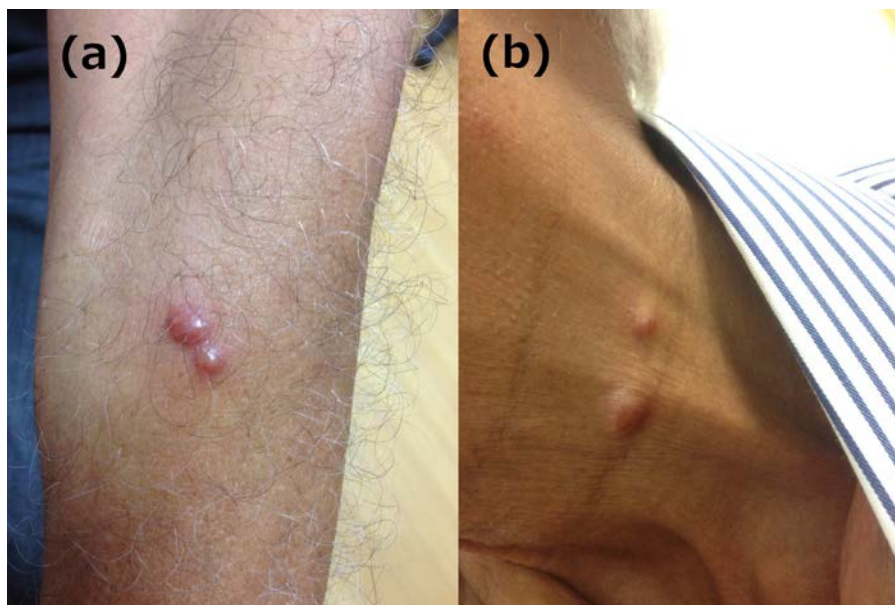

Figure 1: Erythematous papules and nodules on the arm and neck

A biopsy of a skin nodule on the hand revealed a dense lymphocytic infiltrate in the upper, mid, and lower dermis in an interstitial and perivascular pattern (Figure 2). The lymphocytes were medium to large in size with variable degrees of atypia and mitotic figures. Lymphocytic exocytosis within the epidermis forming small intraepidermal groups of lymphocytes was also seen. The epidermis also showed spongiosis and parakeratosis.

Immunohistochemistry revealed that most of the lymphocytes were positive for CD3, CD2, and CD30 with small numbers of intervening CD20 positive B lymphocytes (Figure 2). There was an equal number of CD4 and CD8 lymphocytes with reduced CD5 and CD7 lymphocytes. Minor populations of lymphocytes with CD56, Granzyme B, and TIA-1 positivity were also noted. A negative reaction for Alk-1 was noted.

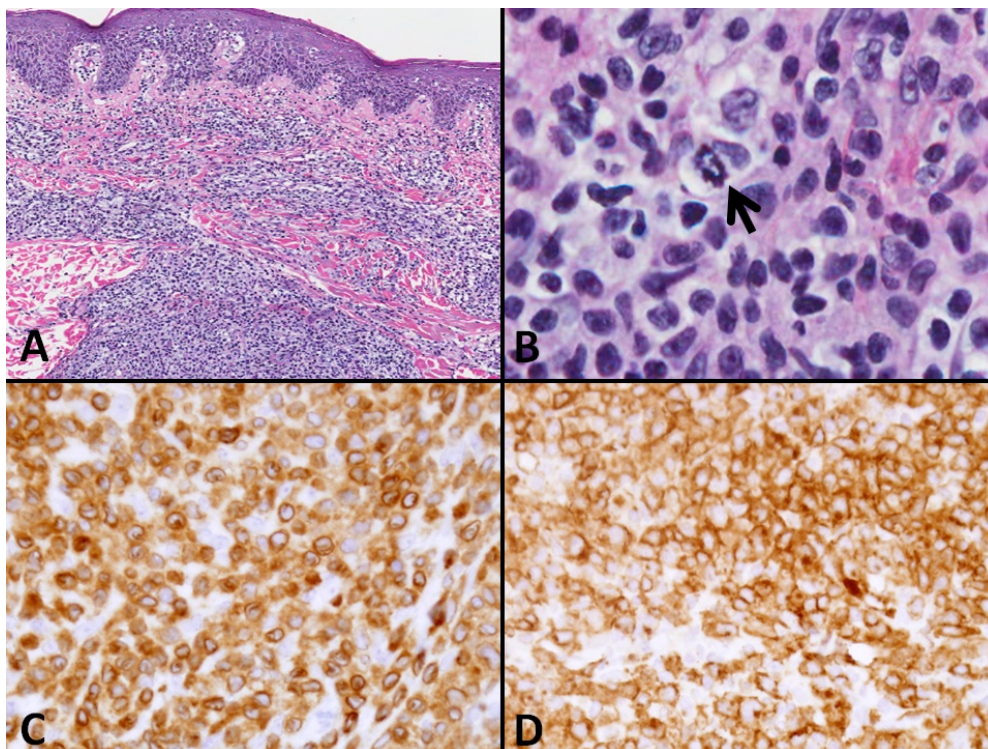


Figure 2. A: Low magnification view of the skin biopsy showing a heavy dermal cellular infiltrate B: High magnification view showing medium-to-large lymphoid cells with scattered mitoses (arrow) C: The lesional lymphoid cells are reactive for the pan T-cell marker, CD3. D.: Immunoreactivity for CD30 is also noted. (A and B: Haematoxylin and Eosin; C and D: Immunoperoxidase, original magnification, A: x40, B: x400, C and D x100)

In view of the relatively chronic indolent history of the eruption together with the biopsy findings, a diagnosis of lymphomatoid papulosis was made. Oral methotrexate 5mg per week was prescribed with good resolution of the primary lesions. The methotrexate was stopped upon complete clearance of lesions.

Subsequently, the patient continued to have two recurrences of bladder cancer at different locations in the bladder requiring two more episodes of TURBT and multiple treatments of intravesical chemotherapy including mitomycin and Bacillus

Calmette–Guérin (BCG). Within a month prior to each recurrence, the patient would experience a flare of his lymphomatoid papulosis and he would then restart on oral methotrexate 5mg weekly. Shortly after each TURBT, his lymphomatoid papulosis would also go into remission. The patient is currently still on follow-up with both the dermatology and urology departments for the above problems.

Discussion

Lymphomatoid papulosis (LyP) is a rare, recurrent, self-healing papulonodular skin eruption with histologic features of a CD30+ malignant T cell lymphoma [1]. It often runs a relapsing-remitting course with a peak incidence in the fifth decade. The etiology of LyP is still unknown. The diagnosis of LyP is dependent on the correlation between typical skin lesions (recurrent eruption of groups of disseminated papules and nodules in different stages of evolution that evolve and regress spontaneously) together with typical histologic, immunophenotypic (expression of CD 30), and cytogenetic features (clonal rearrangement of TCR genes)[5]. LyP has been associated with a lifetime increased risk of developing lymphomas [3,4] and long term follow up is thus necessary to watch for progression of the disease. LyP usually responds well to either psoralen-UVA therapy or low-dose methotrexate [5], as in our patient. A previous case series report in Peru demonstrated a paraneoplastic association between lymphomatoid papulosis and non-Hodgkin's lymphoma [6], but no reports have been published regarding a possible paraneoplastic association between LyP and solid tumors.

Urogenital tumors, especially renal cell carcinoma, are often associated with paraneoplastic syndromes, although the most common of these are neurological [7]. Paraneoplastic syndromes are extremely uncommon in bladder cancers [8]. Previously reported paraneoplastic dermatological syndromes associated with TCC of the bladder are dermatomyositis [9], Bazex syndrome [10], and the Leser-Trélat sign [11]. This is the first case report suggesting a strong association of TCC of the bladder with LyP. In this patient, the eruption preceded the onset of the diagnosis of the bladder cancer by approximately three months and subsequently, each flare of LyP was followed closely by tumor recurrence. Urogenital tumors that are associated with such paraneoplastic syndromes often have a poorer prognosis [8].

References

1. Macaulay, W.L., Lymphomatoid papulosis. A continuing self-healing eruption, clinically benign--histologically malignant. *Arch Dermatol*, 1968; 97(1): 23-30. [PMID: 5634442]
2. Willemze, R., et al., WHO-EORTC classification for cutaneous lymphomas. *Blood*, 2005; 105(10): 3768-85. [PMID: 1629317]
3. Bekkenk, M.W., et al., Primary and secondary cutaneous CD30(+) lymphoproliferative disorders: a report from the Dutch Cutaneous Lymphoma Group on the long-term follow-up data of 219 patients and guidelines for diagnosis and treatment. *Blood*, 2000; 95(12): 3653-61. [PMID: 10845893]
4. Wang, H.H., et al., Increased risk of lymphoid and nonlymphoid malignancies in patients with lymphomatoid papulosis. *Cancer*, 1999; 86(7): 1240-5. [PMID: 10506709]
5. Kempf, W., et al., EORTC, ISCL, and USCLC consensus recommendations for the treatment of primary cutaneous CD30-positive lymphoproliferative disorders: lymphomatoid papulosis and primary cutaneous anaplastic large-cell lymphoma. *Blood*, 2011; 118(15): 4024-35. [PMID: 21841159]
6. Ortega-Loayza, A.G., et al., Cutaneous manifestations of internal malignancies in a tertiary health care hospital of a developing country. *An Bras Dermatol*, 2010; 85(5): 736-42. [PMID: 21152807]
7. Sacco, E., et al., Paraneoplastic syndromes in patients with urological malignancies. *Urologia internationalis*, 2009; 83(1): 1-11. [PMID: 19641351]
8. Perez Arbej, J.A., et al., [Paraneoplastic syndromes in urology]. *Arch Esp Urol*, 1991; 44(8): 943-9. [PMID: 1796856]
9. Xu, R., et al., A rare paraneoplastic dermatomyositis in bladder cancer with fatal outcome. *Urol J*, 2013; 10(1): 815-7. [PMID: 23504689]
10. Arregui, M.A., et al., Bazex's syndrome (acrokeratosis paraneoplastica)--first case report of association with a bladder carcinoma. *Clin Exp Dermatol*, 1993; 18(5): 445-8. [PMID: 8252768]
11. Martínez-Morán C, Sanz-Muñoz C, Miranda-Romero A. Leser-Trélat sign associated with Sézary syndrome and transitional cell carcinoma of the bladder. *Actas Dermosifiliogr*. 2007 Apr; 98(3):214-5. [PMID: 17504710]