

# UCSF

## UC San Francisco Previously Published Works

### Title

Stemless shoulder arthroplasty: review of short and medium-term results

### Permalink

<https://escholarship.org/uc/item/54n7k993>

### Journal

JSES International, 3(3)

### ISSN

2666-6383

### Authors

Upfill-Brown, Alexander  
Satariano, Nicholas  
Feeley, Brian

### Publication Date

2019-10-01

### DOI

10.1016/j.jses.2019.07.008

Peer reviewed



## Stemless shoulder arthroplasty: review of short and medium-term results

Alexander Upfill-Brown, MD, MSc <sup>a</sup>, Nicholas Satariano, MD <sup>b</sup>, Brian Feeley, MD <sup>b,c,\*</sup>

<sup>a</sup> Department of Orthopaedic Surgery, David Geffen School of Medicine at UCLA, Los Angeles, CA, USA

<sup>b</sup> Department of Orthopedic Surgery, University of California at San Francisco, San Francisco, CA, USA

<sup>c</sup> San Francisco Veterans Affairs Medical Center, Department of Veterans Affairs, San Francisco, CA, USA

### ARTICLE INFO

#### Keywords:

Shoulder arthroplasty  
reverse shoulder arthroplasty  
stemless  
press-fit  
canal-sparing

Level of evidence: Level IV, Systematic Review

**Background:** The number of anatomic total shoulder (TSA), hemiarthroplasty (HA), and reverse total shoulder arthroplasties (RTSA) is rapidly increasing in the United States. Stemless shoulder arthroplasty has numerous theoretical advantages, including preserved bone stock, decreased operating time, reduced rate of intraoperative humerus fracture, and flexibility of anatomic reconstruction. Only recently studies with more than 5 years of mean follow-up have become available.

**Methods:** The MEDLINE database was systematically queried to identify all studies reporting outcomes regarding anatomic or reverse stemless shoulder arthroplasty. Studies were categorized according to mean reported follow-up. Outcome scores and range of motion measurements were compiled. Complication and revision rates due to failure of the humeral or glenoid components were summarized.

**Results:** Nineteen TSA and HA studies with a total of 1115 patients were identified, with 4 studies and 162 patients with a mean follow-up between 60 and 120 months. Six RTSA studies with a total of 346 patients were identified, all with a mean follow-up between 18 and 60 months. There was a reliable improvement in outcomes compared with preoperative scores across studies. A cumulative 0.7% (8 of 1115) humeral component complication rate was found for TSA and HA components. There was a cumulative 1.7% (6 of 346) humeral complication rate for RTSA prostheses.

**Conclusions:** In the studies reporting similar outcome measures, there were reliable improvements on par with stemmed counterparts. Aggregate complication rates appear similar to those published in the literature for stemmed components. Evidence supporting the utility and safety of stemless designs would be strengthened by longer-term follow-up and additional prospective comparative studies.

© 2019 The Author(s). Published by Elsevier Inc. on behalf of American Shoulder and Elbow Surgeons. This is an open access article under the CC BY-NC-ND license (<http://creativecommons.org/licenses/by-nc-nd/4.0/>).

The incidence of total shoulder arthroplasty (TSA) and reverse shoulder arthroplasty (RTSA) continues to rapidly increase in the United States, with a documented 5-fold rise over the previous decade.<sup>36</sup> A growing proportion of these procedures are RTSA, with one recent study finding RTSA accounting for 33% of all shoulder arthroplasty, along with 44% TSA and 23% hemiarthroplasty (HA).<sup>29</sup> The implant designs have also undergone rapid changes with the advent of short stems and now most recently stemless components.

Theoretical advantages of stemless designs include preservation of humeral bone stock, reduced periprosthetic fracture with the elimination of broaching, reduction in stress shielding, more flexibility in reconstruction in cases of altered anatomy such as

post-traumatic malunion, and less complex revision surgery.<sup>10,11,16</sup> The numerous potential benefits make these new implants a promising option in the near future for clinical practice.

However, there are also possible disadvantages including the theoretical risk of component loosening before osseous ingrowth has occurred and the reliance on adequate humeral metaphyseal bone stock. Although in some cases lesser tuberosity fixation after osteotomy may be more challenging with stemless designs, there are several modern strategies to obtain a robust subscapularis repair including suture anchors, transosseous tunnels, and direct tendon to tendon repair. Although the lack of long-term follow-up (FU) has made some surgeons hesitant to use these implants, since the introduction of the stemless design in Europe in 2004, there have now been a growing number of studies reporting on medium-term 5- to 10-year FU.<sup>15,17,37</sup>

With several smaller studies present in the literature, a larger comprehensive analysis of the data available for stemless shoulder analysis can be performed. We present a systematic review of the

No Institutional Review Board approval was required for this study.

\* Corresponding author: Brian Feeley, MD, Department of Orthopaedic Surgery, University of California San Francisco, 1500 Owens St, San Francisco, CA 94158, USA.  
E-mail address: [Brian.Feeley@ucsf.edu](mailto:Brian.Feeley@ucsf.edu) (B. Feeley).

published studies of patients undergoing stemless TSA, HA, and RTSA. Attention is focused on functional outcomes as well as reported complication and revision rates. We hypothesized that functional outcomes would be similar for stemless versus stemmed implants, and that humeral complications would not differ substantially from previously published rates for stemmed components.

**Methods**

A broad search of English-language literature was conducted beginning from January 1, 2000, through August 1, 2018. Investigators searched both MEDLINE through PubMed and Google Scholar using MeSH search terms including “stemless,” “canal-sparing,” “reverse,” “shoulder replacement,” or “shoulder arthroplasty.” A manual reference check of previous reviews and published studies was conducted to identify any additional relevant studies.

To meet inclusion criteria, studies needed to include more than 5 patients undergoing TSA, HA, or RTSA report functional outcomes measured using either standardized metrics or range of motion (ROM) measurement, and explicitly comment on complications. No threshold was set for minimum FU time. Studies were classified according to the mean length of FU into 3 groups: very short term (mean FU <18 months), short term (FU 18-60 months), and medium term (60-120 months).

Outcome measures reported by the authors varied substantially. Most included Constant-Murley scores (CMS),<sup>12</sup> with other common metrics including the Disabilities of the Arm, Shoulder, and Hand score and the American Shoulder and Elbow Surgeons score. Most authors also reported explicit measures of ROM, such as external rotation (ER), abduction, and flexion.

All complications were examined in each study, with attention focused on humeral component–related complications and revisions. Revision rates due to failure of the humeral or glenoid component were also summarized. Study, patient, and treatment characteristics were summarized with the use of basic descriptive statistics.

**Results**

A total of 19 studies of anatomic stemless TSA and HA were included in the analysis, with a mean FU between 6 and 108 months. Across the 19 included studies, a total of 1115 patients who underwent stemless TSA (n = 814) or HA (n = 301) were identified: 212 in very short–term FU studies, 741 in short-term FU studies, and 162 in medium-term FU studies (Table 1). A total of 6 studies involving stemless RTSA were identified involving 346 patients, all with a mean FU in the short-term category between 18 and 60 months (Table IV).

A total of 5 stemless TSA/HA implants from 6 different prosthesis companies were identified. These included the Total Evolutive Shoulder System (TESS; Biomet, Warsaw, IN, USA), the Eclipse stemless shoulder prosthesis (Arthrex, Freieham, Germany) (Fig. 1, A, B), the Affinis (Mathys AG, Bettlach, Switzerland), the Sidus Stem-Free Shoulder System (Zimmer Biomet, Warsaw, IN, USA), and the Simpliciti total shoulder system (Wright Medical, Memphis, TN, USA) (Fig. 1, C, D). The Simpliciti by Wright Medical and the Sidus system by Zimmer Biomet are the only devices currently Food and Drug Administration approved for use in the United States.

A total of 2 stemless RTSA implants were identified including the TESS short reverse corolla (Biomet) and the Verso stemless reverse metaphyseal TSA prosthesis (Innovative Design Orthopaedics, London, UK). Neither stemless RTSA device is currently approved by the Food and Drug Administration.

**Table 1**  
Summary of stemless anatomical TSA and HA studies identified, grouped by average length of follow-up

Study	Device	Type	Patients		Reported indications	Mean FU (mo)	Reported outcomes
			TSA	HA			
<b>Medium term</b>							
Habermeyer et al 2015 <sup>15</sup>	Arthrex/Eclipse	Case series	29	39	Primary OA, post-trauma OA, postinfectious OA, instability, CTA, GD	72	CMS, ER, Flex, Abd
Hawi et al 2017 <sup>17</sup>	Arthrex/Eclipse	Case series	17	32	Post-trauma OA, primary OA, instability, CTA, postinfectious OA	108	CMS, ER, Flex, Abd
Uschok et al 2017 <sup>37</sup>	Arthrex/Eclipse	Randomized	14		Primary OA	68	CMS, ER, Flex, Abd
Beck et al 2018 <sup>4</sup>	Biomet/TESS	Case series	31		Primary OA, RA, post-traumatic and HH necrosis	95	CMS, QuickDASH, VAS, Abd, Flex
<b>Short term</b>							
Huguet et al 2010 <sup>19</sup>	Biomet/TESS	Case series	19	44	Primary OA, post-trauma OA, osteonecrosis	45	CMS, ER, Flex
Brunner et al 2012 <sup>8</sup>	Arthrex/Eclipse	Case series	119	114	Primary OA, post-trauma OA, postinfectious OA, AVN, RA, instability, CTA	23	CMS, ER, Flex, Abd
Berth and Pap 2012 <sup>6</sup>	Biomet/TESS	Randomized	41		Primary OA	31	CMS, DASH, ER, Abd, Flex
Razmjou et al 2013 <sup>27</sup>	Biomet/TESS	Comparative	17		Primary OA	>24	RCMS, ASES, QuickDASH, WOOS
Bell and Coghlan 2014 <sup>5</sup>	Mathys/Affinis	Case series	12		Primary OA	>24	CMS, ASES, DASH, SPADI, Abd
Mariotti et al 2014 <sup>25</sup>	Wright Med/Simpliciti	Comparative	9		Primary OA	24	CMS, SST, ER, IR, Abd, Flex
Ballas et al 2016 <sup>3</sup>	Biomet/TESS	Case series	27		Malunion	44	CMS
Churchill et al 2016 <sup>11</sup>	Wright Med/Simpliciti	Case series	149		Primary OA, post-trauma OA	>24	CMS, ASES, SST, VAS, ER, Abd, IR
Spranz et al 2017 <sup>33</sup>	Biomet/TESS	Comparative	12		Primary OA	52	CMS, ER, Flex, Ext, Abd
Krukenberg et al 2018 <sup>22</sup>	Zimmer/Sidus	Case series	73	32	Primary OA, post-trauma OA, AVN, instability, RA	>24	CMS, ASES, SSV, ER, Flex
Heuberger et al 2018 <sup>18</sup>	Arthrex/Eclipse	Case series	33	40	Primary OA, post-trauma OA	58	CMS
<b>Very short term</b>							
Sayed-Noor et al 2018 <sup>28</sup>	Biomet/TESS	Case series	63		Primary OA	12	QuickDASH, ER, Abd
Maier 2015 <sup>24</sup>	Biomet/TESS	Comparative	12		Primary OA	6	CMS, ER, IR, Abd, Flex
Schoch et al 2011 <sup>30</sup>	Arthrex/Eclipse	Case series	115		Primary OA, post-trauma OA	12	CMS, ER, Abd, Flex
Kadum et al 2011 <sup>20</sup>	Biomet/TESS	Case series	22		Primary OA, post-trauma OA, RA	14	QuickDASH, EQ-5D, VAS

TSA, total shoulder arthroplasty; HA, hemiarthroplasty; FU, follow-up; OA, osteoarthritis; CTA, cuff tear arthropathy; GD, glenoid dysplasia; CMS, Constant-Murley score; ER, external rotation; Flex, flexion; Abd, Abduction; TESS, Total Evolutive Shoulder System; RA, rheumatoid arthritis; HH, humeral head; DASH, Disabilities of the Arm, Shoulder, and Hand score; VAS, visual analog scale for pain; AVN, avascular necrosis; RCMS, relative Constant-Murley score; ASES, American Shoulder and Elbow Surgeons score; WOOS, Western Ontario Osteoarthritis Shoulder score; SPADI, Shoulder Pain and Disability Index; SST, Simple Shoulder Test; IR, internal rotation; SSV, Subjective Shoulder Value.

**Table II**  
Summary of humeral component complications in stemless anatomical TSA and HA

Study	Patients	Complications	Radiologic changes	Related revisions
<b>Medium term</b>				
Habermeyer et al 2015 <sup>15</sup>	78		1 incomplete RLL, 3 partial osteolysis under HH, 34% with decreased BD of GT	None
Hawi et al 2017 <sup>17</sup>	43	1 asymptomatic radiological loosening	1 incomplete RLL on HH, 29% decrease BD over GT	None
Uschok et al 2017 <sup>37</sup>	14		Reduced BD in GT in 29%	None
Beck et al 2018 <sup>4</sup>	31		None	None
<b>Short term</b>				
Huguet et al 2010 <sup>19</sup>	63	5 intraoperative fracture of metaphysis	None	
Brunner et al 2012 <sup>8</sup>	233	1 asymptomatic radiological loosening	9 incomplete RLL <2 mm, 5 incomplete RLL >2 mm, 2 RLL >2 mm	None
Berth and Pap 2012 <sup>5</sup>	41		None	None
Razmjou et al 2013 <sup>27</sup>	17		1 RLL	
Bell and Coghlan 2014 <sup>5</sup>	12		None	None
Mariotti et al 2014 <sup>25</sup>	9		None	
Ballas et al 2016 <sup>3</sup>	27		1 osteolysis under HH	None
Churchill et al 2016 <sup>11</sup>	149		None	None
Spranz et al 2017 <sup>33</sup>	12			
Krukenberg et al 2018 <sup>22</sup>	105	1 intraoperative fracture greater tuberosity	1 incomplete RLL HH	None
Heuberger et al 2018 <sup>18</sup>	73		8 with signs osteolysis, decreased BD over GT in 43%	None
<b>Very short term</b>				
Sayed-Noor et al 2018 <sup>28</sup>	63			None
Maier 2015 <sup>24</sup>	12			None
Schoch et al 2011 <sup>30</sup>	115			
Kadum et al 2011 <sup>20</sup>	22			

TSA, total shoulder arthroplasty; HA, hemiarthroplasty; RLL, radiolucent lines; HH, humeral head; BD, bone density; GT, greater tuberosity.

### Stemless TSA and HA outcomes

Primary osteoarthritis was the most common indication reported for stemless TSA, though studies varied in the indications included in analysis. There was considerable variability in reported outcome measures; the most commonly reported is the CMS with 84% (n = 16) of studies reporting preoperative and postoperative values (Table I). A total of 73% (n = 14) of studies were case series, 15% (n = 3) of studies were nonrandomized comparisons of stemmed and stemless humeral components, and 10% (n = 2) were randomized studies of stemmed versus stemless components.

Looking specifically at the randomized trials, the study by Berth and Pap<sup>6</sup> analyzed 82 patients evenly randomized to stemless (TESS; Biomet) or cemented stem components. They found no

difference in functional outcomes at more than 24 months of FU; however, there was significantly increased operating room (OR) time (106 vs. 92 minutes) and estimated blood loss (593 vs. 496 mL) reported in the stemmed group compared with the stemless group. The second study by Uschok et al<sup>37</sup> analyzed 40 patients randomized to stemless (Eclipse; Arthrex) or press-fit stem components, with 29 patients available for analysis at more than 60 months of FU. The authors found no difference in functional outcomes between either group postoperatively.

A graphical representation of 2 commonly reported outcomes, ER and CMS, is displayed in Figure 2. Across studies, there was a reliable improvement in both CMS and ER postoperatively compared with preoperatively, with a roughly 30-point improvement in CMS and a 20° increase in ER.

**Table III**  
Summary of glenoid component complications in stemless anatomical TSA and HA

Study	Patients	Complications	Radiologic changes	Related revisions
<b>Medium term</b>				
Habermeyer et al 2015 <sup>15</sup>	78	2 loosening	Incomplete RLL in 8.3% of MBC and 53% of cemented	2
Hawi et al 2017 <sup>17</sup>	43		5 with RLL, 27% with incomplete RLL	None
Uschok et al 2017 <sup>37</sup>	14	2 loosening	2 incomplete RLL	0
Beck et al 2018 <sup>4</sup>	31	1 loosening, 1 failure MBC	20 of 22 with RL	1
<b>Short term</b>				
Huguet et al 2010 <sup>19</sup>	63		None	
Brunner et al 2012 <sup>8</sup>	233	1 loosening	None	1
Berth and Pap 2012 <sup>5</sup>	41	1 intraoperative fracture	9 with RL	None
Razmjou et al 2013 <sup>27</sup>	17	6 intraoperative perforation	1 subsidence	
Bell and Coghlan 2014 <sup>5</sup>	12		8 incomplete RLL	None
Mariotti et al 2014 <sup>25</sup>	9		None	
Ballas et al 2016 <sup>3</sup>	27		None	None
Churchill et al 2016 <sup>11</sup>	149	1 loosening	None	1
Spranz et al 2017 <sup>33</sup>	12		NR	
Krukenberg et al 2018 <sup>22</sup>	105		6 complete RLL, 10 incomplete RLL	None
Heuberger et al 2018 <sup>18</sup>	73		None	None
<b>Very short term</b>				
Sayed-Noor et al 2018 <sup>28</sup>	63		NR	None
Maier 2015 <sup>24</sup>	12		NR	None
Schoch et al 2011 <sup>30</sup>	115	2 loosening	NR	
Kadum et al 2011 <sup>20</sup>	22		NR	

TSA, total shoulder arthroplasty; HA, hemiarthroplasty; RLL, radiolucent lines; MBC, metal-backed component; RL, radiolucent; NR, not reported.

**Table IV**  
Summary of stemless RTSA studies identified

Study	Device	Type	Patients	Reported indications	Mean FU (mo)	Reported outcomes
Ballas and Béguin 2013 <sup>2</sup>	Biomet/TESS	Case series	56	RCT, CTA, primary OA	59	CMS, OSS, ER, Abd
Kadum et al 2014 <sup>21</sup>	Biomet/TESS	Comparative	16	CTA, primary OA with RCD, post-trauma sequelae, RA	39	QuickDASH, EQ-5D, VAS, IR, Abd, Flex
Teissier et al 2015 <sup>34</sup>	Biomet/TESS	Case series	87	RCT, CTA	41	CMS, QuickDASH, ASES, ER, Abd, Flex
von Engelhardt et al 2015 <sup>38</sup>	Biomet/TESS	Case series	65	CTA, revision arthroplasty	18	RCMS, DASH
Levy et al 2016 <sup>23</sup>	IDO/Verso	Case series	98	CTA, post-trauma sequelae, RA, RCT, RCD	50	CMS, SSV, ER, IR, Abd
Moroder et al 2016 <sup>26</sup>	Biomet/TESS	Comparative	24	CTA	34	CMS, ASES, SSV, VAS*

RTSA, reverse total shoulder arthroplasty; FU, follow-up; TESS, Total Evolutive Shoulder System; RCT, rotator cuff tear; CTA, cuff tear arthropathy; OA, osteoarthritis; CMS, Constant-Murley score; OSS, Oxford Shoulder Score; ER, external rotation; Abd, abduction; RCD, rotator cuff deficiency; RA, rheumatoid arthritis; DASH, Disabilities of the Arm, Shoulder, and Hand score; VAS, visual analog scale; IR, internal rotation; Flex, flexion; ASES, American Shoulder and Elbow Surgeons score; RCMS, relative Constant-Murley score; SSV, Subjective Shoulder Value.

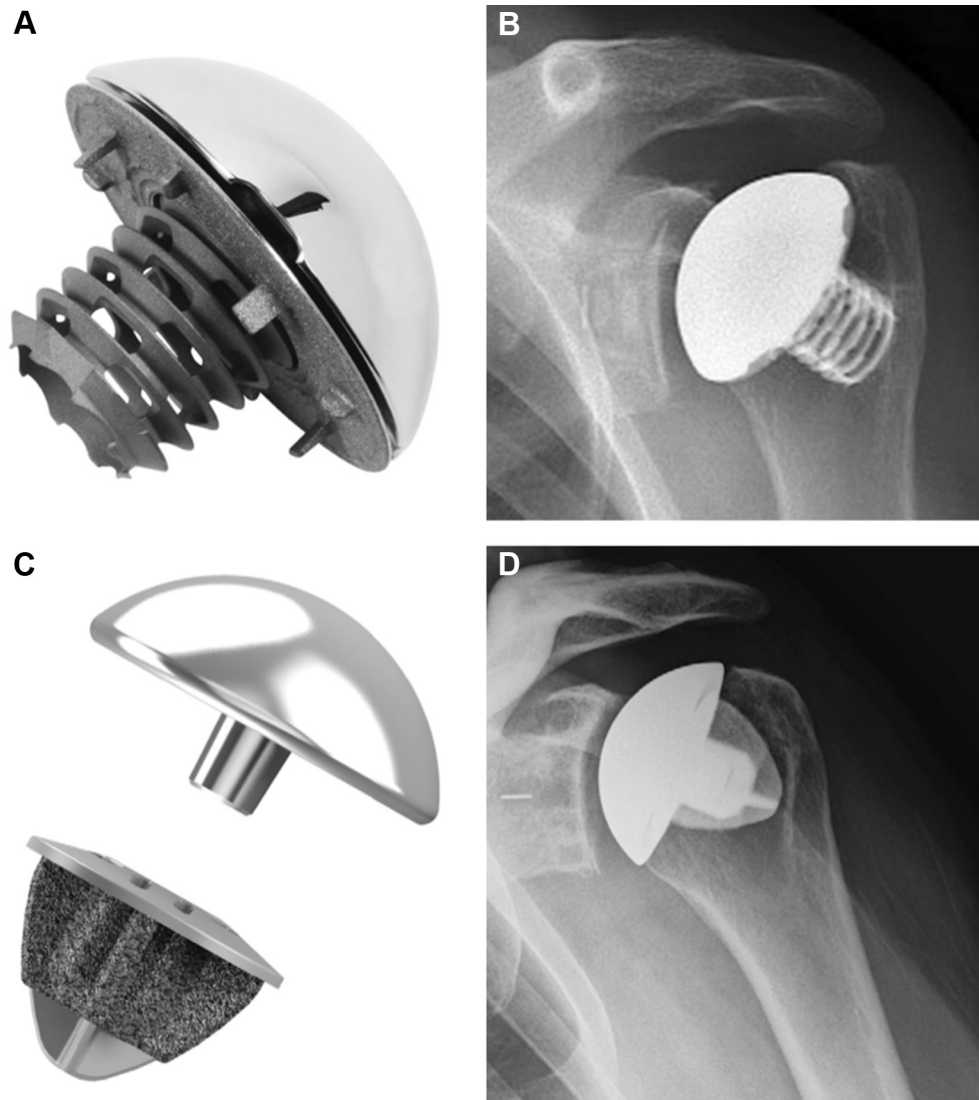
\* Only postoperative values reported for these scores.

### Stemless RTSA outcomes

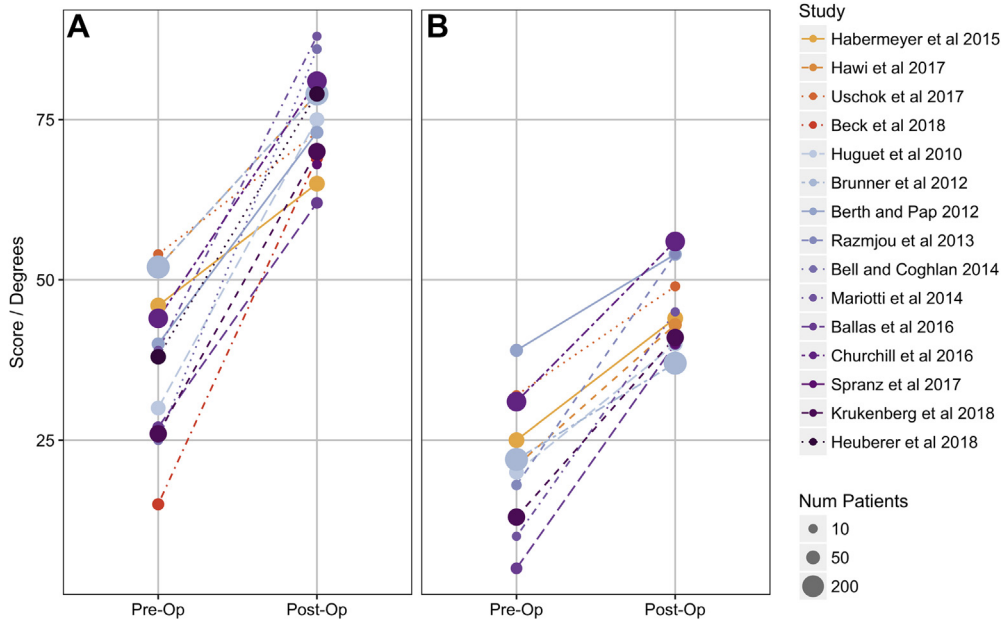
The most common indications were cuff tear arthropathy and rotator cuff tear (Table IV). Four studies were case series reporting a variety of outcomes. Two studies were nonrandomized

comparisons between stemmed and stemless RTSA components, neither finding any significant difference in functional outcomes.

Reported outcomes varied substantially between studies, with 50% (n = 3) of the studies reporting CMS preoperatively and postoperatively, 1 reporting only postoperative values, and the



**Figure 1** Humeral components from 2 stemless total shoulder arthroplasty systems most commonly found in literature. (A) Picture of the Eclipse (Arthrex, Naples, FL, USA) from Habermeyer et al.<sup>15</sup> with (B) the representative AP radiograph from Brunner et al.<sup>5</sup> (C) Picture of Simpliciti (Wright Medical, Memphis, TN, USA) and (D) the representative anteroposterior radiography both from Churchill et al.<sup>11</sup>



**Figure 2** Reported outcomes before and after anatomical stemless total shoulder arthroplasty and hemiarthroplasty for Constant-Murray score (A) and external rotation (B). Colors represent each study, with warm colors corresponding to medium-term follow-up studies and cool colors corresponding to short-term follow-up studies. Very short-term studies (average follow-up <18 months) were excluded.

remaining 2 studies using other outcome measures including the Disabilities of the Arm, Shoulder, and Hand score.

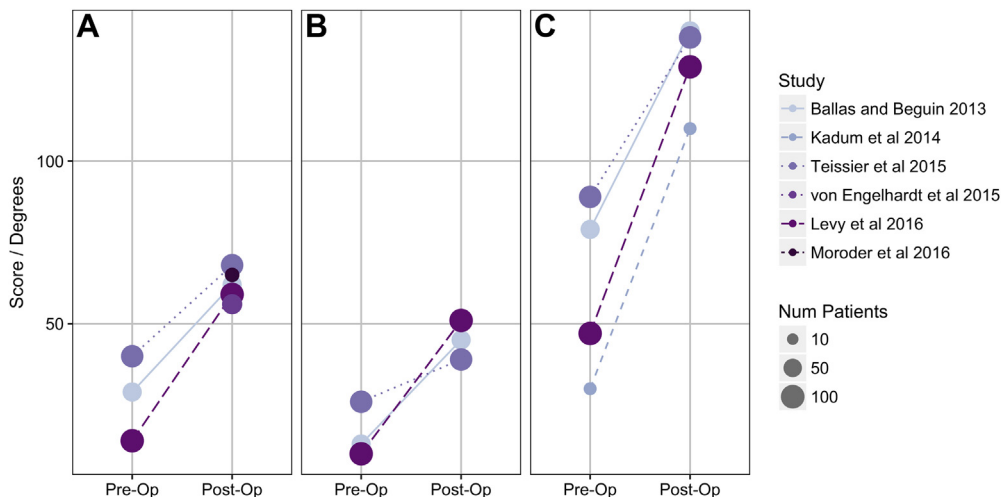
CMS and ER and abduction measurements preoperatively and postoperatively are summarized in Figure 3 for those studies with the available information. There was an approximately 30-point improvement in CMS, a 20° increase in ER, and a 60° increase in abduction (Figure 3).

**Complications**

Of the 1115 stemless TSA and HA patients included, 0.7% (n = 8) of complications were related to the humeral component (Table II). Six were intraoperative fracture,<sup>19,22</sup> 5 of which were reported in the first published study on stemless components, and all healed with nonoperative management. Two complications were asymptomatic loosening confirmed by radiology.<sup>8,17</sup> There were no

revisions related to the humeral component. Four studies also reported changes in bone density over the greater tuberosity, with higher percentages indicating greater internal stress shielding, present in 29%,<sup>37</sup> 29%,<sup>17</sup> 34%,<sup>15</sup> and 43%<sup>18</sup> of patients undergoing stemless TSA. The one comparative study reporting changes in greater tuberosity bone density found a higher rate of reduced bone density in stemmed (47%) compared with stemless TSA components (29%), though this difference was not significant and the clinical relevance is not clear (P = .4).<sup>37</sup> When comparing bone density at the humeral calcar however, a significant increase in the rate of reduced bone density was found in the stemmed group (41%) compared with the stemless group (0%).<sup>37</sup>

Of the 346 stemless RTSA patients included, 1.7% (n = 6) experienced complications related to the humeral component (Table V). Two of 6 were instances of symptomatic loosening,<sup>2,38</sup> of which all were revised to a stemmed humeral component (one after 3 days,



**Figure 3** Reported outcomes before and after stemless reverse total shoulder arthroplasty for Constant-Murray score (A), external rotation (B), and abduction (C). Colors represent each study. The size of the point represents the number of patients in each study.



**Table V**  
Summary of humeral component complications in stemless RTSA

Study	Patients	Complications	Radiologic changes	Related revisions
Ballas and Béguin 2013 <sup>2</sup>	56	1 intraoperative fracture of metaphysis, 1 loosening (3 d)	None	1
Kadum et al 2014 <sup>21</sup>	16	None	None	None
Teissier et al 2015 <sup>34</sup>	87	None	None	None
von Engelhardt et al 2015 <sup>38</sup>	67	1 loosening (in revision), 1 malposition	NR	2
Levy et al 2016 <sup>23</sup>	98	2 intraoperative fracture of metaphysis	None	None
Moroder et al 2016 <sup>26</sup>	24	None	3 incomplete RLL	None

RTSA, reverse total shoulder arthroplasty; NR, not reported; RLL, radiolucent lines.

the other not reported). Three complications were intraoperative fracture of the metaphysis, all managed conservatively.<sup>2,23</sup> One case involved malpositioning of the humeral component, which required revision to a stemmed humeral component in the immediate postop period.<sup>38</sup> Radiographical changes were sparingly reported with only 3 reports of incomplete radiolucent lines surrounding the humeral component.<sup>26</sup>

There were substantially more complications related to the glenoid component in patients undergoing TSA and RTSA. Of the 814 anatomic TSA patients, 2.1% (n = 17) experienced complications involving the glenoid component: 9 patients with loosening, 7 with intraoperative fracture or perforation, and 1 failure of the metal-backed component (Table III). A total of 29% (n = 5) of these patients required revision of the glenoid component. Of the 346 RTSA stemless RTSA patients, 3.2% (n = 11) experienced complications involving the glenoid component: 9 patients with loosening and 2 with malpositioning (Table VI). A total of 90% (n = 10) of these patients required revision of the glenoid component.

## Discussion

The body of literature regarding stemless anatomic and RTSA continues to grow with the available prospective and randomized studies showing outcomes similar to traditional stemmed counterparts. Across retrospective case series, there were consistent improvements in commonly reported outcomes including functional scores and ROM measurements. In the available comparative studies, there was also no difference in functional outcomes between stemmed and stemless components. These outcomes are maintained in the medium-term studies identified for anatomic TSA, with a mean FU more than 60 months. Standardization across reported outcomes, including both preoperative and postoperative values, would enable more robust meta-analyses in the future.

Data from 2 studies supported claims that stemless shoulder replacement results in shorter operative time compared with stemmed components. The aforementioned randomized study by Berth and Pap<sup>6</sup> found a decreased OR time of roughly 15 minutes and a decreased estimated blood loss of roughly 100 mL in the stemless group compared with the stemmed group. Heuberer et al<sup>18</sup> found operative time to be more than 20 minutes shorter in both stemless TSA and HA compared with stemmed alternatives ( $P < .001$ ). This is an important benefit as shorter OR times have

been shown to result in fewer postoperative infections, reduced complications, and decreased cost.<sup>9,13,39</sup>

Regarding other advantages and disadvantages, previous literature has highlighted the concern for increased loosening of stemless components, while citing decreased intraoperative fracture as a theoretical benefit. This review found a 0.2% rate of asymptomatic humeral loosening (none of which required revision) and a 0.5% rate of intraoperative humeral fracture in patients undergoing stemless TSA or HA. The most recent systematic review of complication rates in anatomic and reverse stemmed shoulder arthroplasty found a 0.1% rate of humeral loosening and a 0.6% rate of intraoperative humeral fracture,<sup>7</sup> with an intraoperative fracture rate as high as 1.5% in other studies.<sup>1</sup> Thus, in studies we identified, outcomes for anatomic stemless designs were found to have a comparable rate of humeral component loosening and similar if not slightly less rate of intraoperative fracture compared with stemmed components.

In cases of stemmed RTSA, reported rates of humeral loosening are 0.7%, and although isolated humeral fracture rates are not clearly available, 2.3% of RTSA were complicated by either a glenoid or humerus intraoperative fracture.<sup>7</sup> In this review, the 6 studies available for stemless RTSA demonstrated a 0.6% rate of humeral component loosening and a 0.9% rate of humeral intraoperative fracture with no instances of glenoid fracture. Although our identified rate of humeral loosening for stemless RTSA was slightly higher than the rate identified in a recent systemic review of stemmed components,<sup>7</sup> we cannot comment on the significance of this difference given the small number of stemless RTSA patients available in the literature.

In the studies identified, we found reliable improvements in functional outcomes and largely equivocal complication rates for stemless anatomic TSA, HA, and RTSA compared with those published for stemmed components. However, there are multiple limitations to the current body of literature. First, there is an absence of long-term FU studies with an average FU of 10 years or more for stemless implants. For stemmed TSA and HA components, multiple studies have examined patients at 15 and 20 years of FU, finding survival rates of 87% to 88% at 15 years and 84% to 85% at 20 years.<sup>14,31,32,35</sup> Survival is substantially lower for stemmed anatomic HA averaging 75% to 76% at 20 years.<sup>31,32</sup> Second, there is a relative lack of randomized studies comparing stemmed and stemless components. Although these studies may be expensive,

**Table VI**  
Summary of glenoid component complications in stemless RTSA

Study	Patients	Complications	Radiologic changes	Scapular notching (%)	Related revisions
Ballas and Béguin 2013 <sup>2</sup>	56	3 disassociation	None	5 (9)	3
Kadum et al 2014 <sup>21</sup>	16	2 loosening	None	4 (25)	2
Teissier et al 2015 <sup>34</sup>	87	None	None	17 (19)	None
von Engelhardt et al 2015 <sup>38</sup>	67	3 loosening, 2 malpositioning	NR	9 (13)	4
Levy et al 2016 <sup>23</sup>	98	1 loosening	None	21 (22)	1
Moroder et al 2016 <sup>26</sup>	24	None	NR	2 (8)	None

RTSA, reverse total shoulder arthroplasty; NR, not reported.

reliance on data from case reports introduces the possibility of selection bias, which may result in underestimates of complication and revision rates associated with these new prostheses. Finally, one of the main theoretical advantages of stemless components is the preservation of bone stock and subsequently less complicated secondary or revision surgery. Although there is little data on the available literature on revisions of stemless humeral components (possibly because of their current lack of long-term FU), a study comparing outcomes in revision of stemless versus stemmed implants could shed new light on this possible advantage.

## Conclusion

In our review of all the current available literature, we identified a total of 25 studies with 1461 patients who underwent stemless TSA, HA, or RTSA. Two randomized studies were available that showed no difference in functional outcomes between patients who received stemless or stemmed components. In the studies that reported similar outcome measures, there were reliable improvements in CMS and ROM including ER and abduction. Aggregate complication rates appear similar to those reported in the literature for stemmed implants. Overall, the current data on stemless implants are promising; however, evidence supporting the utility and safety of these relatively new designs would be strengthened by longer-term FU and additional randomized studies.

## Disclaimer

The authors, their immediate families, and any research foundations with which they are affiliated have not received any financial payments or other benefits from any commercial entity related to the subject of this article.

## References

- Athwal GS, Sperling JW, Rispoli DM, Cofield RH. Periprosthetic humeral fractures during shoulder arthroplasty. *J Bone Joint Surg Am* 2009;91:594–603. <https://doi.org/10.2106/JBJS.H.00439>.
- Ballas R, Béguin L. Results of a stemless reverse shoulder prosthesis at more than 58 months mean without loosening. *J Shoulder Elbow Surg* 2013;22:e1–6. <https://doi.org/10.1016/j.jse.2012.12.005>.
- Ballas R, Teissier P, Teissier J. Stemless shoulder prosthesis for treatment of proximal humeral malunion does not require tuberosity osteotomy. *Int Orthop* 2016;40:1–7. <https://doi.org/10.1007/s00264-016-3138-y>.
- Beck S, Beck V, Wegner A, Dudda M, Patsalis T, Jäger M. Long-term survivorship of stemless anatomical shoulder replacement. *Int Orthop* 2018;42:1–4. <https://doi.org/10.1007/s00264-018-3779-0>.
- Bell SN, Coghlan JA. Short stem shoulder replacement. *Int J Shoulder Surg* 2014;8:72–5. <https://doi.org/10.4103/0973-6042.140113>.
- Berth A, Pap G. Stemless shoulder prosthesis versus conventional anatomic shoulder prosthesis in patients with osteoarthritis. *J Orthopaed Traumatol* 2012;14:31–7. <https://doi.org/10.1007/s10195-012-0216-9>.
- Bohsali KI, Bois AJ, Wirth MA. Complications of shoulder arthroplasty. *J Bone Joint Surg Am* 2017;99:256–69. <https://doi.org/10.2106/JBJS.16.00935>.
- Brunner UH, Fruth M, Rückl K, Magosch P, Tauber M, Resch H, et al. The stemless Eclipse prosthesis—indications and mid-term results. *Obere Extremität* 2012;7:22–8. <https://doi.org/10.1007/s11678-011-0152-y>.
- Childers CP, Maggard-Gibbons M. Understanding costs of care in the operating room. *JAMA Surg* 2018;153:e176233–7. <https://doi.org/10.1001/jamasurg.2017.6233>.
- Churchill RS, Athwal GS. Stemless shoulder arthroplasty—current results and designs. *Curr Rev Musculoskelet Med* 2016;9:10–6. <https://doi.org/10.1007/s12178-016-9320-4>.
- Churchill RS, Chuinard C, Wiater JM, Friedmann R, Freehill M, Jacobson S, et al. Clinical and radiographic outcomes of the Simpliciti canal-sparing shoulder arthroplasty system. *J Bone Joint Surg Am* 2016;98:552–60. <https://doi.org/10.2106/JBJS.15.00181>.
- Constant CR, Gerber C, Emery RJH, Sjøbjerg JO, Gohlke F, Boileau P. A review of the Constant score: Modifications and guidelines for its use. *J Shoulder Elbow Surg* 2008;17:355–61. <https://doi.org/10.1016/j.jse.2007.06.022>.
- Daley BJ, Cecil W, Clarke PC, Cofer JB, Guillaumondegu OD. How slow is too slow? Correlation of operative time to complications: an analysis from the Tennessee surgical quality collaborative. *J Am Coll Surg* 2015;220:550–8. <https://doi.org/10.1016/j.jamcollsurg.2014.12.040>.
- Deshmukh AV, Koris M, Zurakowski D, Thornhill TS. Total shoulder arthroplasty: long-term survivorship, functional outcome, and quality of life. *J Shoulder Elbow Surg* 2005;14:471–9. <https://doi.org/10.1016/j.jse.2005.02.009>.
- Habermeyer P, Lichtenberg S, Tauber M, Magosch P. Midterm results of stemless shoulder arthroplasty: a prospective study. *J Shoulder Elbow Surg* 2015;24:1463–72. <https://doi.org/10.1016/j.jse.2015.02.023>.
- Harmer L, Throckmorton T, Sperling JW. Total shoulder arthroplasty: are the humeral components getting shorter? *Curr Rev Musculoskelet Med* 2016;9:17–22. <https://doi.org/10.1007/s12178-016-9313-3>.
- Hawi N, Magosch P, Tauber M, Lichtenberg S, Habermeyer P. Nine-year outcome after anatomic stemless shoulder prosthesis: clinical and radiologic results. *J Shoulder Elbow Surg* 2017;26:1609–15. <https://doi.org/10.1016/j.jse.2017.02.017>.
- Heuberger PR, Brandl G, Pauzenberger L, Laky B, Kriegleder B, Anderl W. Radiological changes do not influence clinical mid-term outcome in stemless humeral head replacements with hollow screw fixation: a prospective radiological and clinical evaluation. *BMC Musculoskelet Disord* 2018;19:1–9. <https://doi.org/10.1186/s12891-018-1945-6>.
- Huguet D, DeClercq G, Rio B, Teissier J, Zipoli B, The TESS Group. Results of a new stemless shoulder prosthesis: radiologic proof of maintained fixation and stability after a minimum of three years' follow-up. *J Shoulder Elbow Surg* 2010;19:847–52. <https://doi.org/10.1016/j.jse.2009.12.009>.
- Kadum B, Mafi N, Norberg S, Sayed-Noor AS. Results of the Total Evolutive Shoulder System (TESS®): a single-centre study of 56 consecutive patients. *Arch Orthop Trauma Surg* 2011;131:1623–9. <https://doi.org/10.1007/s00402-011-1368-4>.
- Kadum B, Mukka S, Englund E, Sayed-Noor A, Sjöden G. Clinical and radiological outcome of the Total Evolutive Shoulder System (TESS®) reverse shoulder arthroplasty: a prospective comparative non-randomised study. *Int Orthop* 2014;38:1001–6. <https://doi.org/10.1007/s00264-013-2277-7>.
- Krukenberg A, McBirnie J, Bartsch S, Böhler N, Wiedemann E, Jost B, et al. Sidus Stem-Free Shoulder System for primary osteoarthritis: short-term results of a multicenter study. *J Shoulder Elbow Surg* 2018;27:1483–90. <https://doi.org/10.1016/j.jse.2018.02.057>.
- Levy O, Narvani A, Hous N, Abraham R, Relwani J, Pradhan R, et al. Reverse shoulder arthroplasty with a cementless short metaphyseal humeral implant without a stem: clinical and radiologic outcomes in prospective 2- to 7-year follow-up study. *J Shoulder Elbow Surg* 2016;25:1362–70. <https://doi.org/10.1016/j.jse.2015.12.017>.
- Maier MW. Are there differences between stemless and conventional stemmed shoulder prostheses in the treatment of glenohumeral osteoarthritis? *BMC Musculoskelet Disord* 2015;16:1–7. <https://doi.org/10.1186/s12891-015-0723-y>.
- Mariotti U, Motta P, Stucchi A, Ponti di Sant'Angelo F. Stemmed versus stemless total shoulder arthroplasty: a preliminary report and short-term results. *Musculoskelet Surg* 2014;98:195–200. <https://doi.org/10.1007/s12306-014-0312-5>.
- Moroder P, Ernstbrunner L, Zweiger C, Schatz M, Seitlinger G, Skursky R, et al. Short to mid-term results of stemless reverse shoulder arthroplasty in a selected patient population compared to a matched control group with stem. *Int Orthop* 2016;40:1–6. <https://doi.org/10.1007/s00264-016-3249-5>.
- Razmjou H, Holtby R, Christakis M, Axelrod T, Richards R. Impact of prosthetic design on clinical and radiologic outcomes of total shoulder arthroplasty: a prospective study. *J Shoulder Elbow Surg* 2013;22:206–14. <https://doi.org/10.1016/j.jse.2012.04.016>.
- Sayed-Noor AS, Pollock R, Elhassan BT, Kadum B. Fatty infiltration and muscle atrophy of the rotator cuff in stemless total shoulder arthroplasty: a prospective cohort study. *J Shoulder Elbow Surg* 2018;27:976–82. <https://doi.org/10.1016/j.jse.2017.12.021>.
- Schairer WW, Nwachukwu BU, Lyman S, Craig EV, Gulotta LV. National utilization of reverse total shoulder arthroplasty in the United States. *J Shoulder Elbow Surg* 2015;24:91–7. <https://doi.org/10.1016/j.jse.2014.08.026>.
- Schoch C, Huth J, Aghajev E, Bauer G, Mauch F. Stemless humeral head replacement in posttraumatic and primary omarthrosis patients. *Obere Extremität* 2011;6:275–81. <https://doi.org/10.1007/s11678-011-0137-x>.
- Schoch B, Schleck C, Cofield RH, Sperling JW. Shoulder arthroplasty in patients younger than 50 years: minimum 20-year follow-up. *J Shoulder Elbow Surg* 2015;24:705–10. <https://doi.org/10.1016/j.jse.2014.07.016>.
- Sperling JW, Cofield RH, Rowland CM. Minimum fifteen-year follow-up of Neer hemiarthroplasty and total shoulder arthroplasty in patients aged fifty years or younger. *J Shoulder Elbow Surg* 2004;13:604–13. <https://doi.org/10.1016/j.jse.2004.03.013>.
- Spranz DM, Bruttel H, Wolf SI, Zeifang F, Maier MW. Functional midterm follow-up comparison of stemless total shoulder prostheses versus conventional stemmed anatomic shoulder prostheses using a 3D-motion-analysis. *BMC Musculoskelet Disord* 2017;18:1–5. <https://doi.org/10.1186/s12891-017-1835-3>.
- Teissier P, Teissier J, Kouyoumdjian P, Ascencio G. The TESS reverse shoulder arthroplasty without a stem in the treatment of cuff-deficient shoulder conditions: clinical and radiographic results. *J Shoulder Elbow Surg* 2015;24:45–51. <https://doi.org/10.1016/j.jse.2014.04.005>.
- Torchia ME, Cofield RH, Settergren CR. Total shoulder arthroplasty with the Neer prosthesis: long-term results. *J Shoulder Elbow Surg* 1997;6:495–505.



36. Trofa D, Rajaei SS, Smith EL. Nationwide trends in total shoulder arthroplasty and hemiarthroplasty for osteoarthritis. *Am J Orthop (Belle Mead NJ)* 2014;43:166–72.
37. Uschok S, Magosch P, Moe M, Lichtenberg S, Habermeyer P. Is the stemless humeral head replacement clinically and radiographically a secure equivalent to standard stem humeral head replacement in the long-term follow-up? A prospective randomized trial. *J Shoulder Elbow Surg* 2017;26:225–32. <https://doi.org/10.1016/j.jse.2016.09.001>.
38. von Engelhardt LV, Mancke M, Filler TJ, Jerosch J. Short-term results of the reverse Total Evolutive Shoulder System (TESS) in cuff tear arthropathy and revision arthroplasty cases. *Arch Orthop Trauma Surg* 2015;135:1–8. <https://doi.org/10.1007/s00402-015-2218-6>.
39. Willis-Owen CA, Konyves A, Martin DK. Factors affecting the incidence of infection in hip and knee replacement. *J Bone Joint Surg Br* 2010;92:1128–33. <https://doi.org/10.1302/0301-620X.92B8>.