

# UC Davis

## Dermatology Online Journal

### Title

Primary cutaneous zygomycosis secondary to minor trauma in an immunocompromised pediatric patient: a case report

### Permalink

<https://escholarship.org/uc/item/4r2455h9>

### Journal

Dermatology Online Journal, 20(6)

### Authors

Sirignano, Samantha  
Blake, Patrick  
Turrentine, Jake E  
et al.

### Publication Date

2014

### DOI

10.5070/D3206022864

### Copyright Information

Copyright 2014 by the author(s). This work is made available under the terms of a Creative Commons Attribution-NonCommercial-NoDerivatives License, available at <https://creativecommons.org/licenses/by-nc-nd/4.0/>

Peer reviewed

## Case Report

### Primary cutaneous zygomycosis secondary to minor trauma in an immunocompromised pediatric patient: a case report

Samantha Sirignano BA, Patrick Blake MD, Jake E. Turrentine MD, Arturo R Dominguez MD

Dermatology Online Journal 20 (6): 5

University of Texas Southwestern Medical Center

#### Correspondence:

Arturo R Dominguez, MD  
University of Texas Southwestern Medical Center  
arturo.dominguez@utsouthwestern.edu

## Abstract

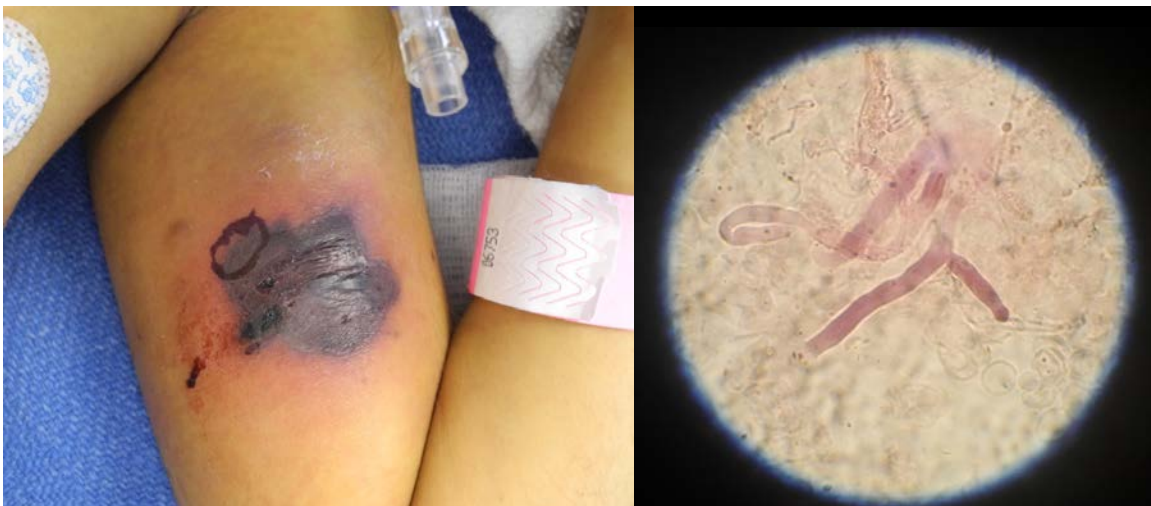Zygomycosis is an opportunistic infection generally found in immunocompromised individuals. Herein we present a pediatric patient with primary cutaneous mucormycosis that developed at a site of trauma. Diagnosis and treatment are discussed.

## Introduction

Zygomycosis is a serious infection caused by fungi of the class *Zygomycetes*. Most often caused by members of the order *Mucorales*, especially *Rhizopus* species, these infections are generally opportunistic. Risk factors include hematological malignancies, prolonged neutropenia, uncontrolled diabetes mellitus, and systemic immunosuppressive therapy, although these infections have been observed in immunocompetent hosts as well [1]. The prevalence of these infections has increased in recent years, likely following the trend of increasing opportunistic infections in general, especially in the oncology patients and transplant recipients [2 – 4]. Unfortunately, with this increase in prevalence, there has been a sustained high mortality rate related to these devastating infections, especially once a localized infection has progressed to disseminated disease [5]. Therefore, to prevent systemic dissemination and reduce mortality, early recognition and treatment of cutaneous zygomycosis is of critical importance. We report a case of a pediatric patient with primary cutaneous mucormycosis localized to a site of trauma following a bone marrow transplant and we discuss specific recommendations regarding diagnosis and treatment of cutaneous fungal infections in pediatric patients.

**Keywords:** Rhizopus, Mucorales, Mucor, Zygomycosis, Pediatric, Oncology, Transplant

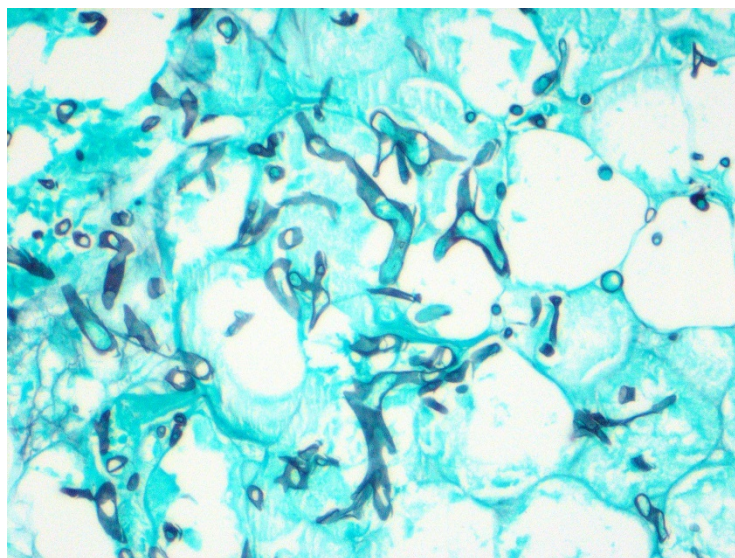
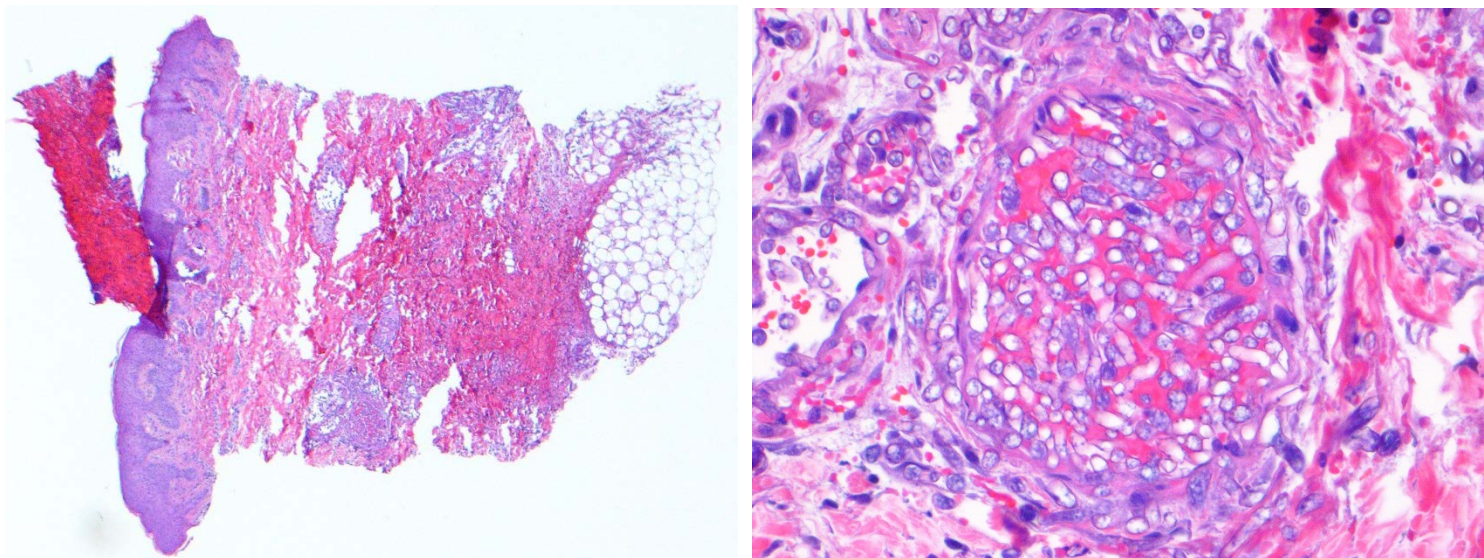
## Case synopsis



**Figure 1.** Hemorrhagic eschar on the upper arm

**Figure 2.** “Touch prep” low magnification demonstrated wide-angle branching hyphae

An 8 year old girl with a history of myelodysplastic syndrome and hemophagocytic lymphohistiocytosis was admitted to undergo chemoablative therapy and an allogenic unrelated bone marrow transplant. Her transplant was complicated by gram negative rod bacteremia requiring placement of an indwelling catheter on the left upper arm. On day 7 post-transplant, she developed thin purpuric papules at this site following removal of the catheter. Clinical laboratory studies were significant for an absolute neutrophil count of 0.23 thousand / mm<sup>3</sup> (reference range 1.80 - 8.00 thousand/mm<sup>3</sup>), further prompting concern for infectious etiology. Skin biopsy was initially deferred owing to the patient’s severe anxiety towards any physical contact.



**Figure 3A.** Low power magnification demonstrating extensive deep necrosis

**Figure 3B.** High power magnification demonstrating angiocentric invasion

**Figure 3C.** High power magnification demonstrating wide-angle branching on PAS-stained tissue

Over the next three days, the papules coalesced forming an indurated plaque with overlying necrosis and eschar. Two 4mm punch biopsies of the suspicious lesion were performed under conscious sedation. One sample was sent for tissue culture and the other for histopathologic examination. A touch prep using 10% potassium hydroxide and stained with toluidine blue was performed, which revealed pauci-septate hyphae with approximately 90 degree branching on immediate microscopic analysis. On pathologic examination with hematoxylin-eosin staining, there were pauci-septate wide-angle branching angioinvasive hyphae in the dermis accompanied by subcutaneous necrosis. While awaiting culture results, the patient was started on empiric treatment with high-dose liposomal amphotericin B 7.5 mg/kg/day and was continued on anidulafungin 45 mg IV daily as her antifungal prophylaxis. Tissue culture revealed *Rhizopus* sp., and the patient underwent surgical debridement with wound VAC placement. She also required two subsequent surgical debridements and eventual wound closure. She received a 12-week course of the dual

antifungal therapy and remains on weekly prophylaxis with liposomal amphotericin B 2.5mg/kg. At 5 month follow-up, there has been complete wound healing with no recurrence of infection.

## Discussion

Angioinvasive infections from multiple bacterial and fungal organisms may present as purpuric plaques with necrotic eschar in neutropenic patients with hematologic malignancies. In these patients, infection with one of the *zygomycoses* (which includes fungi of the orders *Mucorales*, *Phycomycete*, and *Basidiobolus*) must be considered early in the differential diagnosis because early treatment significantly improves prognosis. Zygomycosis has been known to affect any organ in the body, but most commonly presents as rhinocerebral, pulmonary, or cutaneous disease [5]. Regardless of site, these infections are aggressive with mortality rates from 35-66%, depending on comorbidities and level of immunosuppression, with disseminated disease a clear risk factor for mortality [5]. Although primary cutaneous disease has somewhat better outcomes than most modes of infection, the prognosis is very dependent on the extent of fungal spread, with a mortality of 10% in localized cutaneous infection, 26% in cutaneous infection with extension to bone, tendon, or muscle, and 94% in disseminated disease, for an overall mortality of 31% [5]. Currently, there is general consensus that high-dose liposomal amphotericin B with surgical debridement of infected tissue is the treatment of choice for zygomycosis. Amphotericin B must be started early, even while awaiting culture results, since a delay in appropriate therapy may lead to fungal spread and worsened prognosis. Hyperbaric oxygen may also be used as adjunct therapy. Although Amphotericin B is the preferred agent in zycomycosis infections, alternative treatments exist including echinocandins and posaconazole; zygomycosis is resistant to other triazoles [6, 7]. Although there has been interest in iron chelation as a treatment option, a randomized controlled trial of 20 patients treated with amphotericin B and deferasirox showed increased mortality [8].

As compared to adults, zygomycosis in the pediatric population has a similar biology with a few significant distinctions. Most of the infections are also caused by *Rhizopus* sp., as in adults [9]. The first line treatment in children is also high-dose liposomal amphotericin B and surgical debridement with possible hyperbaric oxygen, with survival rates increasing dramatically from 3% in untreated children to 70% in those receiving appropriate antifungal treatment in one small case series [9 – 11]. Although these opportunistic infections are on the rise in the adult population, in whom voriconazole is often used as antifungal prophylaxis, the incidence appears unchanged in the pediatric population. This distinction may relate to a high incidence of resistance of mucormycosis to triazoles (as discussed above) and the use of broader antifungal prophylaxis in the pediatric population [12 – 14]. Similar broad and aggressive treatments may also be responsible for the somewhat lower mortality rate of 25% of infected children [14]. The relative importance of risk factors varies between adults and children. In children, malignancy is the most common risk factor for zygomycosis (58% of cases in one analysis), whereas the most common risk factor in adults is poorly controlled diabetes mellitus [7, 14]. Furthermore, the clinical presentations differ between the two populations. Cutaneous zygomycosis is the most common presentation in children and rhinocerebral disease is the most common in adults [5, 9].

Owing to its devastating effects in high-risk pediatric and oncologic populations, cutaneous zygomycosis has particular importance in the hospital setting. Direct inoculation is the usual route of cutaneous infection, regardless of host immune status. Immunocompetent hosts tend to develop infection secondary to major or minor trauma or burns and other high risk populations tend to develop infections as a result of venous catheters, stasis ulcers, or even abrasions caused by a sterile dressing [13, 17, 18]. In contrast to other angioinvasive fungal infections caused by *Aspergillus* or *Fusarium* in which primary cutaneous infection is unlikely to disseminate (although the skin may be secondarily involved by an already disseminated infection), cutaneous zygomycosis is a primary infection characterized by rapid dissemination owing to the invasive nature of the organism [5]. This necessitates early diagnosis and aggressive treatment of localized zygomycosis given the high mortality associated with more established, invasive infections [5, 13].

The lesion classically progresses from a red purpuric plaque with or without pustules to necrosis and eschar formation, commonly extending into deeper tissues [7, 14]. Because infections by other angioinvasive fungi, such as *Aspergillus* and *Fusarium*, can give a similar presentation, tissue diagnosis with histopathologic examination and culture is of paramount importance. In this particular case, we highlight the utility of the “touch prep” (also known as *rapid touch preparation analysis*) for a rapid presumptive diagnosis, which may aid in the decision to start empiric intravenous amphotericin as opposed to other systemic antifungal agents. The touch prep technique has been described previously and shows utility in diagnosing cutaneous fungal infections, including *Aspergillus* and *Cryptococcus*, among others [15, 16]. A touch prep is performed by smearing a punch biopsy specimen and/or a small amount of tissue from the wound base onto a glass slide and treating with KOH and/or other special stains such as chlorazol black for immediate examination under light microscopy. In our case, a presumptive diagnosis of zygomycosis infection was made based on its characteristic appearance, demonstrating wide, ribbon-like, non-septate hyphae branching at 90° angles; amphotericin was initiated within hours of the biopsy [13]. Although a touch prep is a useful tool, histopathologic examination with hematoxylin and eosin (H&E) should always be performed and tissue cultures should always be done. For H&E staining, deep punch or incisional biopsies should be taken from the center of the lesion and should include subcutaneous fat in order to demonstrate the *Mucorales* spp. and the involvement of blood vessels in the section, although this

may not be seen in disease caused by the rarer Entomophthorales fungi [1, 7]. In our case, both histopathologic examination and tissue culture confirmed a diagnosis of zygomycosis and, specifically, *Rhizopus* spp. infection. Providers should consider microwave-assisted rapid tissue processing for hematoxylin-eosin staining or evaluation of frozen sections if touch prep is negative in order to expedite diagnosis. If clinical suspicion is high and rapid studies are not available, initiation of empiric amphotericin should be considered.

In cases in which there is difficulty obtaining positive tissue cultures of zygomycosis but a great deal of clinical suspicion for fungal disease, PCR assays have been found to be helpful. In particular, pan-fungal PCR incorporated with mold-specific PCR seems to be an effective method of determining the species causing a patient's disease and the most appropriate treatment for them [19]. Of note, a positive tissue culture (or fungal PCR) without clinical or histopathologic evidence of fungal infection should not necessarily be taken as evidence of infection owing to the common contamination of cultures with *Zygomycetes* and other saprophytes [13]. Lastly, although the beta-D glucan serum assay is sometimes used for presumptive diagnosis of fungal infection, the test does not detect the *Zygomycetes*, which do not produce (1,3)-beta-D-glucan.

Another salient point in this case is the challenge of performing biopsies in children, who may have emotional outbursts and behavioral issues that are not seen in adults. Although our patient had a successful outcome, the diagnosis was delayed in an attempt to spare a severely anxious child from further stress. In general, one should strive to minimize emotional trauma to children, which may be associated with needles and painful procedures. To minimize emotional trauma and facilitate performance of the biopsy procedure, biopsies may be performed under conscious sedation rather than local anesthesia. Often, hospitalized patients with risk factors for zygomycosis infection require many procedures (such as central line placements or bone marrow biopsies) and conscious sedation can be coordinated with the primary team to perform biopsies when the patient is undergoing sedation for another procedure. In our case, because of behavioral issues and parental insistence, the biopsy was coordinated with the primary team to be performed under conscious sedation. However, whereas this strategy is desirable for children and their parents, we recognize that coordination of conscious sedation is not always feasible or practical. Importantly, attempting to arrange conscious sedation should not lead to a significant delay in diagnosis and biopsy should be obtained as quickly as possible – whether using conscious sedation or local anesthesia – to make a diagnosis and prevent dissemination of infection.

In conclusion, zygomycosis is a serious condition with a high risk of mortality in infected patients. Health care professionals have the greatest chance of preventing this mortality by early diagnosis and aggressive treatment. Recognition of risk factors, clinical features, histologic characteristics, and optimal treatment, including liposomal amphotericin B and wide surgical debridement of affected tissues, is absolutely essential. In particular, cutaneous zygomycosis is strongly associated with trauma, which is often the site of the infection in the traditionally high risk groups for opportunistic infections, such as patients with malignancies and transplants. This association is especially important in the pediatric population, which contracts zygomycosis most commonly in the skin and most often secondary to malignancy-related immunosuppression. This disease is rapidly recognizable by clinical and histologic parameters and there is a relatively effective first-line treatment, making it a manageable diagnosis. Most importantly, a high level of clinical suspicion with appropriate use of tissue biopsy, early empiric treatment, and close follow-up were essential elements in our patient's recovery.

## References

1. Ribes, J., Vonover-Sams, C., Baker, D., 2000, *Zygomycetes in Human Disease*, *Clinical Microbiology Reviews*, v. 13, p. 236-301. [PMID: 10756000].
2. Skiada, A. and Petrikos, G., 2009, Cutaneous zygomycosis, *Clinical Microbiology and Infection*, v. 15, p. 41-45. [PMID: 23930354].
3. Mays, S., and Cohen, P., 2006, Emerging Dermatologic Issues in the Oncology Patient, *Seminars in Cutaneous Medicine and Surgery*, v. 25, p. 179-189. [PMID: 17174838].
4. Nicci, M. and Marr, K., 2005, Emerging Fungal Diseases, *Clinical Infectious Diseases*, v. 41, p. 521-526. [PMID: 16028162].
5. Roden, M., Zaoutis, T., Buchanan, W., *et al.*, 2005, Epidemiology and Outcome of Zygomycosis: A Review of 929 Reported Cases, *Clinical Infectious Diseases*, v. 41, p. 634-653. [PMID: 16080086].
6. Vehreschild, J.J., Birtel, A., Vehreschild, M.J., *et al.*, 2013, Mucormycosis treated with posaconazole: review of 96 case reports. *Critical Reviews in Microbiology* v. 39, p. 310-324. [PMID: 22917084].
7. Kontoyiannis, D. and Lewis, R., 2006, Invasive Zygomycosis: Update on Pathogenesis, Clinical Manifestations, and Management, *Infectious Disease Clinics of North America*, v. 20, p. 581-607. [PMID: 16984870].
8. Spellberg, B., Ibrahim, A., Chin-Hong, P., *et al.*, 2012, The Deferasirox-AmBisome Therapy for Mucormycosis (DEFEAT Mucor) study: a randomized, double-blinded, placebo-controlled trial, *Journal of Antimicrobial Chemotherapy*, v. 67, p. 715-722. [PMID: 21937481].
9. Zaoutis, T., Roilides, E., Chiou, C., *et al.*, 2007, Zygomycosis in Children: A Systematic Review and Analysis of Reported Cases, *Pediatric Infectious Disease Journal*, v. 26, p. 723-727. [PMID: 17848885].

10. Däbritz, J., Attarbaschi, A., Tintelnot, K., *et al.*, 2011, Mucormycosis in paediatric patients: demographics, risk factors, and outcome of 12 contemporary cases, *Mycoses*, v. 54, p. e785-e788. [PMID: 21623951].
11. Erbey, F., Kocabas, E., Bayram, I., *et al.*, 2012, Pediatric invasive mucormycosis cured with high dose liposomal amphotericin B, *Tuberk Toras*, v. 60, p. 375-379. [PMID: 23289469].
12. Mantadakis, E. and Samonis, G., 2009, Clinical presentation of zygomycosis, *Clinical Microbiology and Infection*, v. 15, p. 15-20. [PMID: 19754751].
13. Mays, S., Bogle, M., and Bodey, G., 2006, Cutaneous Fungal Infections in the Oncology Patient, *American Journal of Clinical Dermatology*, v. 7, p. 31-43. [PMID: 16489841].
14. Prasad, P., Vaughan, A., and Zaoutis, T., 2011, Trends in zygomycosis in children, *Mycoses*, v. 55, p.352-356. [PMID: 21981587].
15. Kourosh, AS. "Touch and Go" Rapid Bedside Diagnosis – Resuscitating the Dying Art of the Touch Prep. Poster Presentation, Texas Dermatological Society Annual Meeting, May 2013.
16. Patel NC, Kupiec-Banasikowska A, Kauffman C. Immediate Diagnosis of Cryptococcus Fungal Infection Using Touch Preparation Analysis. *Arch Dermatol.*2009;145(4):501-502. [PMID: 19380688].
17. Kontogiorgi, M., Floros, I., Koroneos, A., *et al.*, 2007, Fatal post-traumatic zygomycosis in an immunocompetent young patient, *Journal of Medical Microbiology*, v. 56, p. 1243-1245. [PMID: 17761490].
18. Lineberry, K., Boettcher, A., Blount, A., and Burgess, S., 2012, Cutaneous Mucormycosis of the Upper Extremity in an Immunocompetent Host: Case Report, *Journal of Hand Surgery*, v. 37, p. 787-791. [PMID: 22305738].
19. Sugawara, Y., Nakase, K., Nakamura, A., *et al.*, 2013, Clinical utility of a panfungal polymerase chain reaction assay for invasive fungal diseases in patients with haematologic disorders, *European Journal of Haematology*, v. 90, p. 331-339. [PMID: 23360173].