

# UC Davis

## Dermatology Online Journal

### Title

An usual elastophagocytic granuloma with involvement of the back: a possible variant of an annular elastolytic giant cell granuloma

### Permalink

<https://escholarship.org/uc/item/4bm2w0vf>

### Journal

Dermatology Online Journal, 21(4)

### Authors

Valdeolivas-Casillas, Nuria  
Pulgar, Fernando  
Dolores Velez, Maria  
et al.

### Publication Date

2015

### DOI

10.5070/D3214026265

### Copyright Information

Copyright 2015 by the author(s). This work is made available under the terms of a Creative Commons Attribution-NonCommercial-NoDerivatives License, available at <https://creativecommons.org/licenses/by-nc-nd/4.0/>

Peer reviewed

## Case presentation

### **An usual elastophagocytic granuloma with involvement of the back: a possible variant of an annular elastolytic giant cell granuloma**

**Nuria Valdeolivas-Casillas, Fernando Pulgar, María Dolores Vélez, Isabel Polo-Rodríguez, Alicia Quesada-Cortés, Cristina Guirado-Koch**

**Dermatology Online Journal 21 (4): 2**

**Servicio de Dermatología. Hospital Universitario Príncipe de Asturias. Alcalá de Henares, Madrid, Spain**

#### **Correspondence:**

Nuria Valdeolivas-Casillas  
Servicio de Dermatología  
Hospital Universitario Príncipe de Asturias  
Alcalá de Henares, Madrid, Spain  
n.valdeolivas@gmail.com

---

## **Abstract**

Annular elastolytic giant cell granuloma (AEGCG) is a very infrequent granulomatous dermatitis characterized by elastolysis and elastophagocytosis. It usually appears in middle-aged Caucasian women and is normally located in sun-exposed areas.

We present a case of a 73-year-old woman with hypertension and type II diabetes, who was admitted to the hospital for an ischemic cerebrovascular accident. She presented with annular and serpiginous skin lesions on her back and arms that had appeared seven months earlier; a clinical and histological diagnosis of elastophagocytic granuloma was made. Our patient exhibited a florid presentation and a self-limiting course.

## **Introduction**

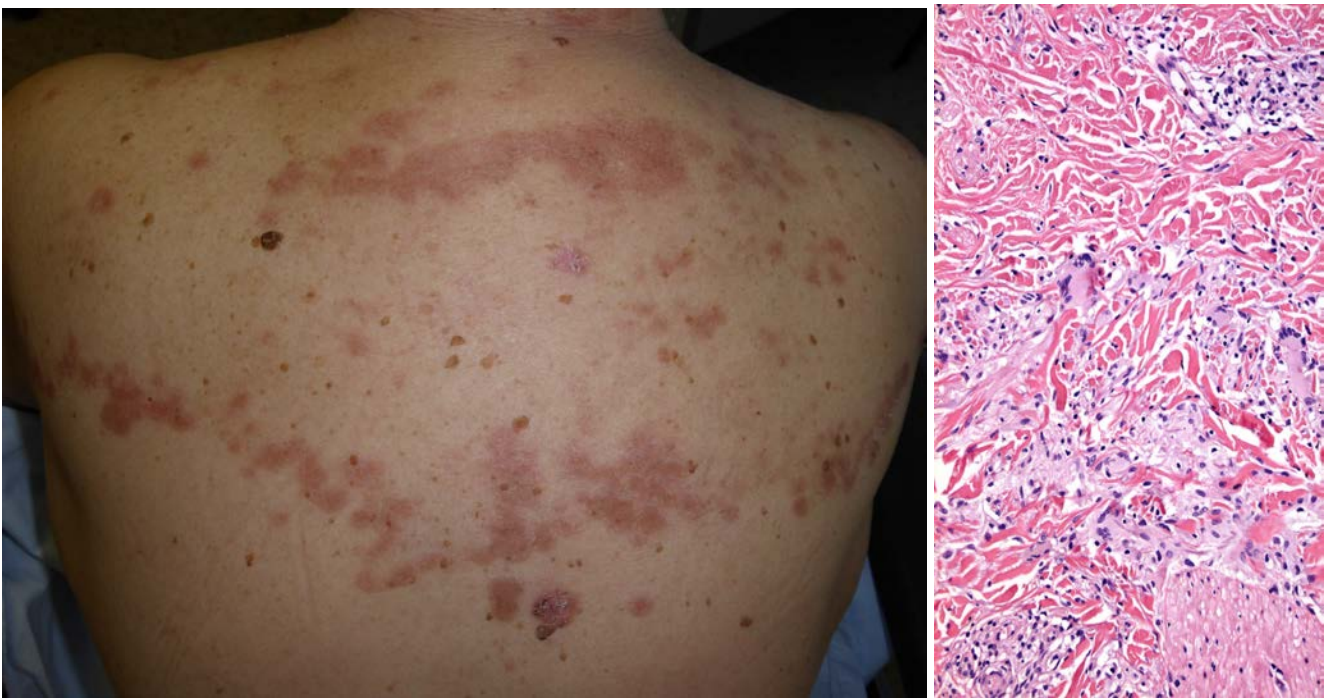
The generic term elastolytic granuloma, which predominantly affects skin exposed to sunlight, includes actinic granuloma described by O'Brien, annular elastolytic giant cell granuloma with no severe actinic damage, atypical necrobiosis lipoidica of the face and scalp [1], Miescher's granuloma [2], and granuloma multiforme. These lesions are characterized clinically by their annular shape and histologically by having a zonal pattern with granulomatous inflammation and giant cells in the annular ring together with loss of elastic fibres in the central zone of the ring. Some authors have used the term annular elastolytic giant cell granuloma as the generic term for this group of conditions, whereas others have used it for cases not associated with severe actinic damage, as is in our case [3].

## **Case synopsis**

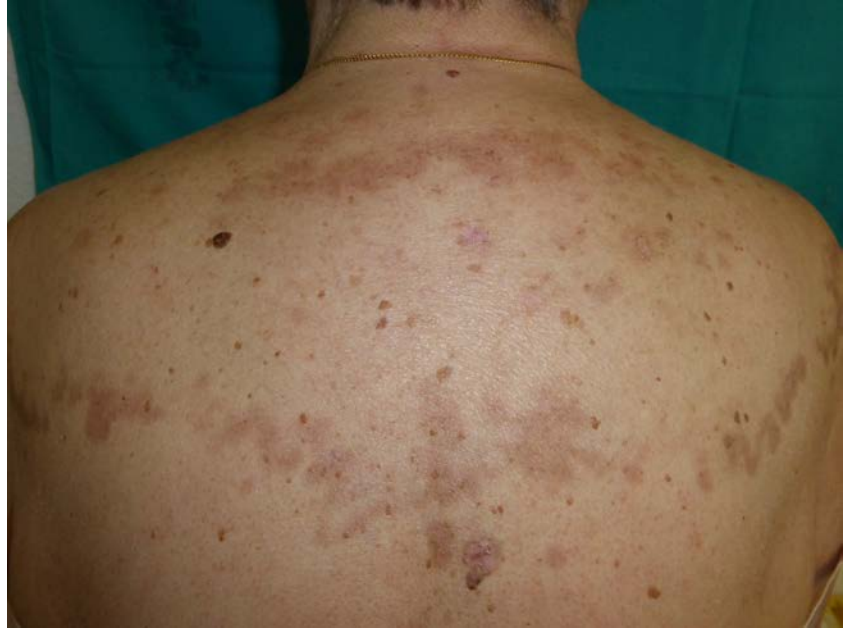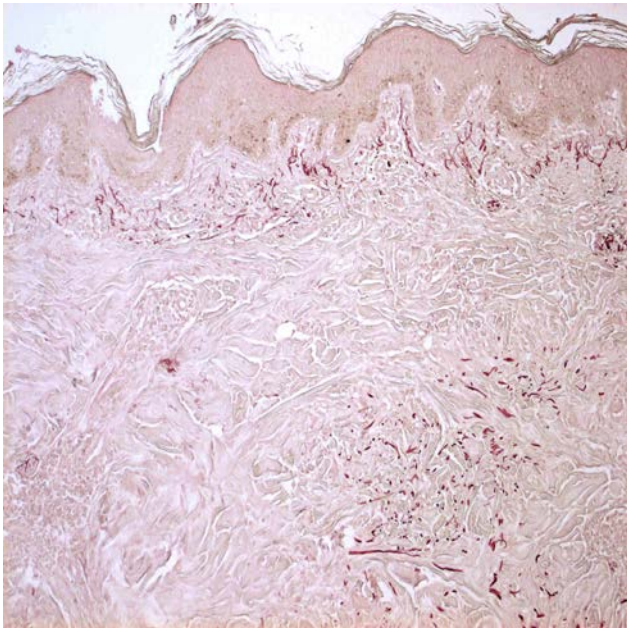
A 73-year-old woman with hypertension and type II diabetes admitted for an ischemic cerebrovascular accident, described asymptomatic lesions on her back that appeared in the last seven months.

The physical examination showed brownish erythematous papules and plaques with raised edges and serpiginous morphology that covered the whole upper third of her back and both arms (Figure 1).

With a clinical diagnosis of granulomatous disease, a biopsy was performed on the right shoulder.



**Figure 1:** Annular and serpiginous plaques can be seen on upper third of her back and both arms. **Figure 2 (20 x):** In the mid dermis there is an interstitial and diffuse granulomatous infiltration with giant cells.



**Figure 3 (10 x):** An elastic stain showed complete loss of mid dermal elastic fibres. **Figure 4:** In this image, only residual pigmentation can be seen.

Histologically, no severe actinic damage of the skin was observed. The most significant histological findings were in the mid-dermis and showed an interstitial and diffuse granulomatous infiltration consisting of histiocytes and giant cells with elastophagocytosis in the ring zone (Figure 2). An elastic stain showed complete loss of mid-dermal elastic fibres in the central zone. No necrobiosis of the collagen or mucin deposits were observed with an Alcian blue stain (Figure 3).

Based on the clinical and pathological findings, the patient was diagnosed with elastophagocytic granuloma. A month and a half after the initial assessment, the lesions on her back and shoulder cleared up spontaneously, leaving only residual pigmentation (Figure 4).

## Discussion

O'Brien first described annular lesions located in sun-exposed areas with elastolysis and elastophagocytosis in 1975, under the name of actinic granuloma [4]. The term AEGCG was later given by Hanke et al in 1979 to describe similar lesions located in non-sun exposed areas [5].

Although the cause is unknown, it has been suggested that the elastic fibres play a key role in the pathogenesis. It is not clear whether elastolysis and elastophagocytosis are primary or secondary events in the genesis of the disease [6]. Most authors have proposed factors such as ultraviolet radiation, heat, and diabetes mellitus [7] as triggers for the process, which would act by altering the antigenicity of the elastic fibres, inducing a cell-mediated immune reaction. Various authors postulate that AEGCG could be the prelude to mid-dermal elastolysis [8-9].

Clinically, the condition is characterized by the presence of annular plaques with raised edges and central atrophy [10]. A reticulated form and another papular form have been described as atypical clinical variants [11-13], but with very few reported cases. Our case differs from those previously published in literature owing to the absence of central atrophy.

Histologically, one observes the presence of granulomatous infiltration, elastophagocytosis, and elastolysis mainly in the mid-dermis. Necrobiosis, mucin deposits, or a palisaded pattern do not usually appear, unlike with necrobiosis lipoidica and granuloma annulare. Even so, some authors disagree as to whether actinic granuloma is really an entity or a variant of granuloma annulare in sun-exposed skin [14].

AEGCG has been associated with other pathologies, including systemic sarcoidosis [11], cutaneous amyloidosis [15], molluscum contagiosum [16], neoplasms [17] (hematological malignancies, prostate cancer, stomach cancer) and endocrinological disease, especially diabetes mellitus [7].

With respect to its development, a chronic course with a poor response to various treatments is typical. There are few published cases in the English literature of spontaneous regression [18], as occurred with our patient.

In conclusion, we provide an exceptional case of extensive, but self-limiting elastophagocytic granuloma. Owing to the absence of central atrophy, the interstitial and diffuse granulomatous infiltration, and the elastophagocytosis and loss of mid-dermal elastic fibers in the central zone, we feel that this case is a variant of AEGCG.

## References

1. Mehregan AH, Altman J. Miescher's granuloma of the face. A variant of the Necrobiosis lipoidica-granuloma annulare spectrum. *Arch Dermatol.* 1973; 107(1):62-4. [PMID: 4682543]
2. Dowling GB, Jones EW. Atypical (annular) necrobiosis lipoidica of the face and scalp. A report of the clinical and histological features of 7 cases. *Dermatologica.* 1967; 135(1):11-26. [PMID: 6033000]
3. Campos-Muñoz L, Díaz-Díaz RM, Quesada-Cortés A, Hernández-Cano N, Martín-Díaz MA, Regojo-Zapata RM, Casado Jiménez M. [Annular elastolytic giant cell granuloma: a case report located in non-sun exposed areas]. *Actas Dermosifiliogr.* 2006; 97(8):533-5. [PMID: 17067534]
4. O'Brien JP. Actinic granuloma: an annular connective tissue disorder affecting sun- and heat-damaged (elastotic) tissue. *Arch. Dermatol.* 1975;111:460-466. [PMID:1122146]
5. Hanke CW, Bailin PL, Roenigk HH. Annular elastolytic giant cell granuloma. A clinicopathologic study of five cases and a review of similar entities. *J Am Acad Dermatol.* 1979; 1(5):413-21. [PMID: 1122146]
6. Yanagihara M, Kato F, Mori S. Extra- and intra-cellular digestion of elastic fibers by macrophages in annular elastolytic giant cell granuloma. An ultrastructural study. *J Cutan Pathol.* 1987; 14(5):303-8. [PMID: 3680717]
7. Aso Y, Izaki S, Teraki Y. Annular elastolytic giant cell granuloma associated with diabetes mellitus: a case report and review of the Japanese literature. *Clin Exp Dermatol.* 2011; 36(8):917-9. doi: 10.1111/j.1365-2230.2011.04094. [PubMed] [PMID: 21623881]
8. Gambichler T. Mid-dermal elastolysis revisited. *Arch Dermatol Res.* 2010; 302(2):85-93. doi: 10.1007/s00403-009-1004-0. [PMID: 199367721]
9. Müller FB, Groth W. Annular elastolytic giant cell granuloma: a prodromal stage of mid-dermal elastolysis? *Br J Dermatol.* 2007; 156(6):1377-9. [PMID: 17459032]
10. Espiñeira-Carmona MJ, Arias-Santiago S, Aneiros-Fernández J, Fernández-Pugnaire MA, Naranjo-Sintes R, Aneiros-Cachaza J. Annular erythematous papules in the neckline. *Dermatol Online J.* 2011; 15: 17(1):7. [PMID: 21272498]
11. Kato H, Kitajima Y, Yaoita H. Annular elastolytic giant cell granuloma: an unusual case with papular lesions. *J Dermatol* 1991; 18: 667-70. [PMID: 1800533]
12. Marmon S, O'Reilly KE, Fischer M, Meehan S, Machler B. Papular variant of annular elastolytic giant-cell granuloma. *Dermatol Online J.* 2012; 15:18(12):23. [PMID: 23286813]
13. Morita K, Okamoto H, Miyachi Y. Papular elastolytic giant cell granuloma: a clinical variant of annular elastolytic giant cell granuloma or generalized granuloma annulare? *Eur J Dermatol* 1999; 9: 647. [PMID: 10586135]
14. Ragaz A, Ackerman AB. Is actinic granuloma a specific condition? *Am J Dermatopathol.* 1979; 1:43. [PMID: 398673]
15. Lee YS, Vijayasingam S, Chan HL. Photosensitive Annular elastolytic giant cell granuloma with cutaneous amyloidosis. *Am J Dermatopathol.* 1989; 11(5):443-50. [PMID: 2679197]
16. Agarwal S, Takwale A, Bajallan N, Berth-Jones J, Charles-Holmes S. Co-existing actinic granuloma and molluscum contagium. *Clin Exp Dermatol.* 2000; 25: 401-403. [PMID: 11012595]

17. Boussault P, Tucker ML, Weschler J, Riaux A, Bervas-Quenehervé C, Quist D, Derancourt C. Primary cutaneous CD4+ small/medium-sized pleomorphic T-cell lymphoma associated with an annular elastolytic giant cell granuloma. *Br J Dermatol.* 2009; 160(5):1126-8. doi: 10.1111/j.1365-2133.2009.09067.[PMID: 19292715]
18. Misago N, Ohtsuka Y, Ishii K, Narisawa Y. Papular and reticular elastolytic giant cell granuloma: rapid spontaneous regression. *Acta Derm Venereol.* 2007; 87(1);89-90. [PMID: 17225028]