

UC Davis

Dermatology Online Journal

Title

Umbilicated nodule over eyebrow

Permalink

<https://escholarship.org/uc/item/4993r122>

Journal

Dermatology Online Journal, 19(9)

Authors

Singh, Nidhi
Kumar, Nava
Chandrashekar, Laxmisha
et al.

Publication Date

2013

DOI

10.5070/D3199019622

Copyright Information

Copyright 2013 by the author(s). This work is made available under the terms of a Creative Commons Attribution-NonCommercial-NoDerivatives License, available at <https://creativecommons.org/licenses/by-nc-nd/4.0/>

Peer reviewed

Photo Vignette

Umbilicated nodule over eyebrow

Nidhi Singh MD, Nava Kumar MBBS, Laxmisha Chandrashekar MD DNB, Devinder Mohan Thappa MD DHA MNAMS, Rakhee Kar MD, Bheemanathi Hanuman Srinivas MD

Dermatology Online Journal 19 (9): 12

Jawaharlal Institute of Postgraduate Medical Education and Research, Puducherry, India

Correspondence:

Nidhi Singh MD
Jawaharlal Institute of Postgraduate Education and Research
Puducherry, India

Abstract

Trichofolliculoma is a pilosebaceous follicle hamartoma in which several hairs are formed within single pilosebaceous unit and protrude out of single orifice. Herein we report a 45-year-old woman with a trichofolliculoma of the eyebrow.

Case synopsis

A 45-year-old woman presented with an asymptomatic slowly growing swelling over the right eyebrow of 6 months duration. There was no history of similar lesion elsewhere in the past and no similar skin lesion in any family members. The patient could not recall any history of trauma at the site of swelling.

Examination revealed a solitary skin colored shiny, firm, non tender nodule of size 0.9X 0.5X 0.5 cm over the infero-medial aspect of the right eyebrow. The nodule had an umbilication in the center with a keratinous plug and a few terminal hairs emerging from it (Figure 1). No other mucocutaneous abnormality was detected and systemic examination was unremarkable. The nodule was excised and sent for histopathological examination.

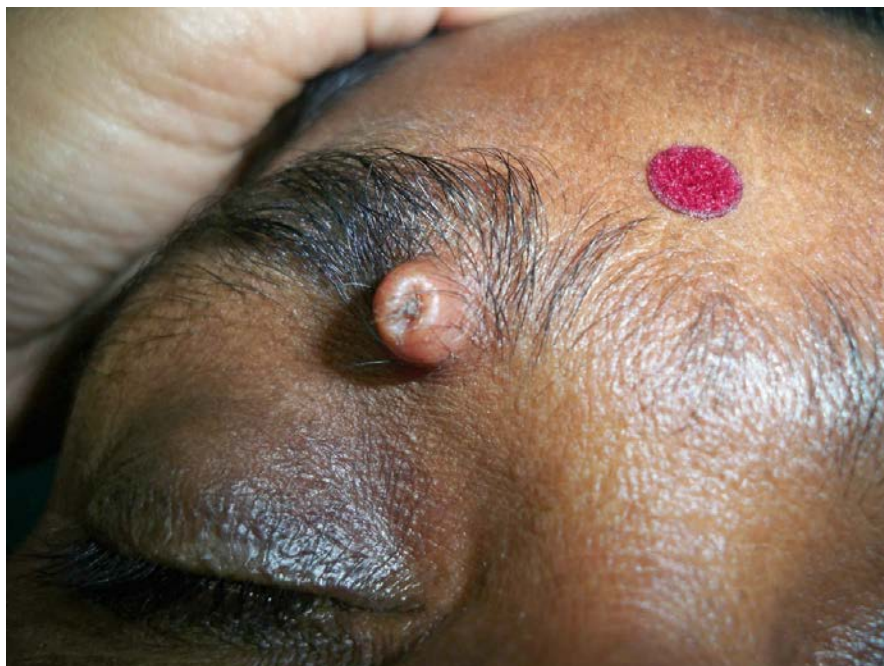

Figure 1. Solitary skin colored shiny, firm, umbilicated nodule with keratinous plug and few terminal hairs emerging over infero-medial aspect of eyebrow.

Histopathological examination revealed a well circumscribed lesion in the dermis composed of hair follicles radially arranged and opening into a centrally dilated hair follicle (Figure 2). The dilated follicular opening showed keratin debris and hair (Figure 3).

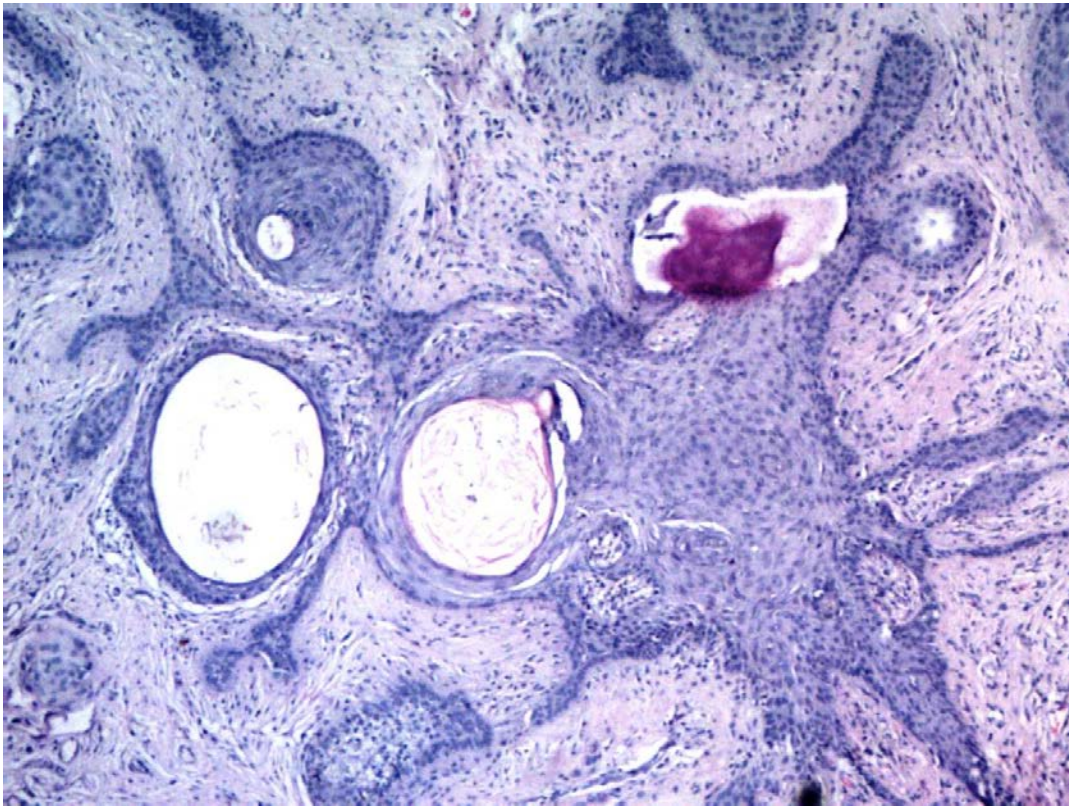


Figure 2. Hair follicles radially arranged and opening into centrally dilated hair follicle (H&E 40X).

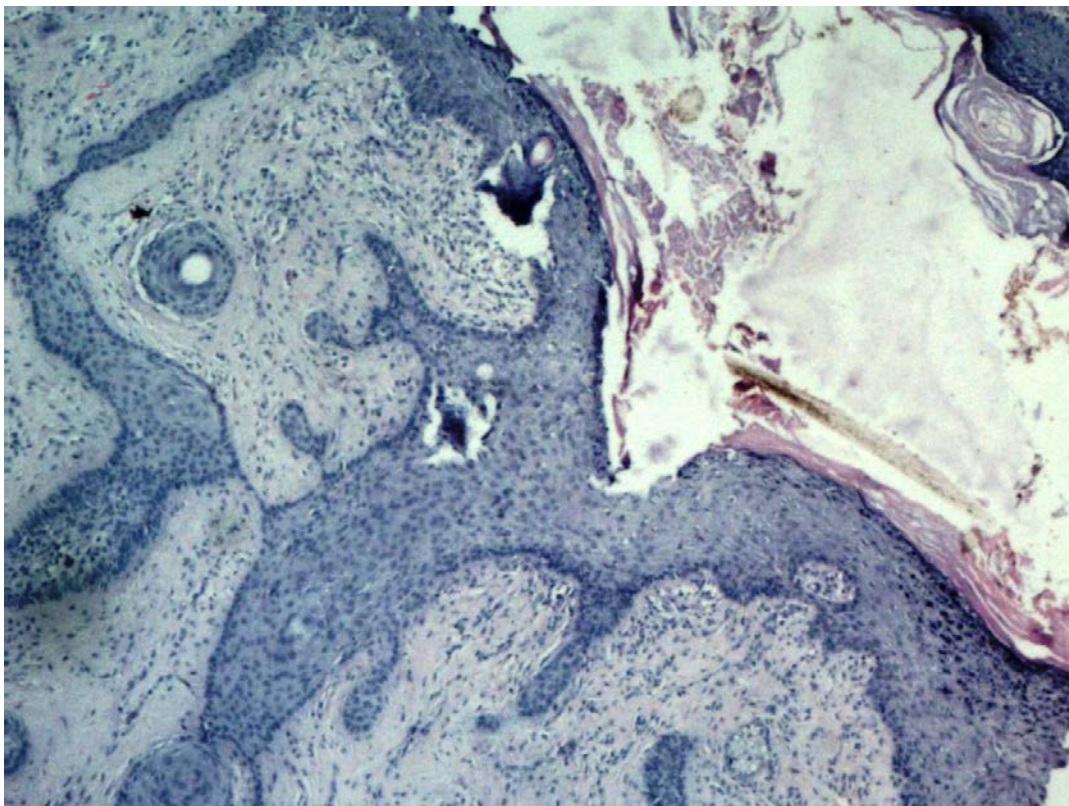


Figure 3: Dilated follicular opening containing keratin debris and hair (H&E 40X)

Discussion

Trichofolliculoma is a pilosebaceous follicle hamartoma in which several hairs are formed within a single pilosebaceous unit and protrude out of a single orifice. It is mostly observed over the head and neck area, particularly the face in young adults, but has also been reported over the vulva, scrotum, penis, external auditory meatus, intranasal area, lips, and upper extremities [1-7]. It is usually seen in adults but a single case of congenital trichofolliculoma has also been reported [8]. No definite sexual predilection is known but sporadic reports suggest a male preponderance. It is usually spontaneous in onset but rarely a history of prior trauma at the site has been reported [9]. The tumor is characterized by a small, asymptomatic, skin colored dome shaped nodule with a central pore, through which a small tuft of two or three hairs protrude. Sometimes, the central pore of the dome shaped nodule appears as a black dot.. The tuft of hair protruding from the central pore or umbilication of the nodule is characteristic [1, 9,10]. If the hair has been plucked or is too fine and missed during examination, the growth may mimic basal cell carcinoma or molluscum contagiosum. In very early stages, it may mimic trichoepithelioma, dermal nevus, or epidermoid cyst if the pore is not clearly visible [9].

Histologically, trichofolliculoma consists of abnormally large follicles with smaller radiating follicular structures referred to as “mother follicle with her babies.” The secondary follicles can present in a spectrum from an immature rudimentary matrix to well differentiated follicles. The well differentiated follicle with fine hairs is also referred to as “fingers of fully formed follicles forming fiber” [10]. On fine needle aspiration cytology, presence of clusters of cohesive branching keratinized cells admixed with loosely clustered sebaceous cells suggests a diagnosis of trichofolliculoma [11]. The evolution of trichofolliculoma is considered similar to a regressing normal hair follicle but probably in a one way direction with no regeneration from telogen to anagen. Trichofolliculoma in early stages is characterized by a few small secondary vellus hair follicles originating from a primary follicle. In a well formed trichoepithelioma, numerous secondary vellus hair follicles are seen radiating from a primary follicle. In very late stages, a thickened primary follicle epithelial lining, fewer secondary follicles, perifollicular mucin, and primitive follicles may be seen. Primitive follicles are usually composed of monomorphous palisading basaloid cells without papillae, analogous to the telogen phase of a hair follicle [7, 12]. In trichoepithelioma there is an inability to control follicular sizes and a deranged follicular cycle [7].

Trichofolliculoma is cosmetically disfiguring and patients may tend to pluck out the hair emerging from it, which sometimes may lead to an inflammatory reaction [13]. Surgical excision is the treatment of choice [1].

References

1. Calonje E. Tumors of skin appendages. In: Burns T, Breathnach S, Cox N, Griffiths C, Editors, Rook's Textbook of Dermatology. 8th edition, Oxford: Wiley-Blackwell,. 2010: 53.7
2. Peterdy GA, Huettner PC, Rajaram V, Lind AC. Trichofolliculoma of the vulva associated with vulval intraepithelial neoplasia: report of three cases and review of literature. Int J Gynecol Pathol. 2002 Jul;21(3):224-30.[PMID:12068167]
3. Nomura M, Hata S. Sebaceous trichofolliculoma on scrotum and penis. Dermatologica. 1990; 181(1):68-70. [PMID 2394307]
4. O'Mahony JJ. Trichofolliculoma of the external auditory meatus. Report of a case and review of literature. J Laryngol Otol. 1981 Jun; 95(6):623-5. [PMID 7252340]
5. Arias Palomo MD, Gutierrez Ortega MC, Hasson Nisis A, Martin Moreno L, Requena Caballero L, Barat Cascante A, Castro Torres A. Intranasal trichofolliculoma. Med Cutan Ibero Lat Am. 1990; 18(3):159-61. [PMID: 2263091]
6. Mizutani H, Senga K, Ueda M. Trichofolliculoma of the upper lip: report of a case.Int J Oral Maxillofac Surg. 1999 Apr; 28(2):135-6. [PMID:10102397]
7. Choi CM, Lew BL, Sim WY. Multiple trichofolliculomas on unusual sites: a case report and review of the literature. Int J Dermatol. 2013 Jan;52(1):87-9.[PMID: 22640019]
8. Ishii N, Kawaguchi H, Takahashi K, Nakajima H. A case of congenital trichofolliculoma. J Dermatol. Mar 1992; 19(3):195-6. [PMID1640026]
9. Howard MS, Smoller BR. Trichofolliculoma. e-Medicine Dermatology. Available from: <http://emedicine.medscape.com> [Last accessed on 2013 March 22].
10. James WD, Berger TG, Elston DM. Epidermal nevi, neoplasms, and cysts. In: James WD, Berger TG, Elston DM, Editor's, Andrews' Diseases of the Skin Clinical Dermatology. 11th edition, China:Saunders Elsevier. 2011: 620-674.
11. Alexander MP, Makhija P, Jayaseelan E. Fine needle aspiration cytology of trichofolliculoma: a case report. Indian J Pathol Microbiol. 2007 Oct; 50(4):870-2. [PMID:18306593]
12. Schulz T, Hartschuh W. The trichofolliculoma undergoes changes corresponding to the regressing normal hair follicle in its cycle. J Cutan Pathol. 1998 Aug; 25(7):341-53. [PMID: 9765019]
13. Carreras B, Lopez- Marin I, Mellado VG, Gutierrez MT. Trichofolliculoma of the eyelid. British Journal of Ophthalmology. 1981 Mar; 65(3):214-5. [PMID: 7225315]