

UC Davis

Dermatology Online Journal

Title

Atrophic dermatofibroma in an elderly male - a rarely described variant of a common lesion

Permalink

<https://escholarship.org/uc/item/45h896p8>

Journal

Dermatology Online Journal, 24(6)

Authors

Morse, Daniel C
Tschen, Jaime A
Silapunt, Sirunya

Publication Date

2018

DOI

10.5070/D3246040677

Copyright Information

Copyright 2018 by the author(s). This work is made available under the terms of a Creative Commons Attribution-NonCommercial-NoDerivatives License, available at <https://creativecommons.org/licenses/by-nc-nd/4.0/>

Peer reviewed

Atrophic dermatofibroma in an elderly male – a rarely described variant of a common lesion

Daniel C Morse¹ BS, Jaime A Tschen² MD, Sirunya Silapunt³ MD

Affiliations: ¹University of Texas McGovern Medical School at Houston, Houston, Texas, USA, ²Saint Joseph Dermatopathology, Houston, Texas, ³Department of Dermatology, University of Texas McGovern Medical School at Houston, Houston, Texas

Corresponding Author: Sirunya Silapunt MD, Associate Professor, Department of Dermatology, University of Texas McGovern Medical School at Houston, 6655 Travis Street, Suite 980, Houston, TX, USA 77030, Tel: 713-500-8334, Fax: 713-500-8323, Email: Sirunya.Silapunt@uth.tmc.edu

Abstract

Dermatofibroma frequently presents as a red-brown nodule on the extremities of the middle aged. Atrophic dermatofibroma is a rare variant that has been most commonly described as an atrophic depressed, erythematous lesion in females. The correct diagnosis of atrophic dermatofibroma is often hindered by its infrequent presentation. It has a female preponderance with an occurrence ratio of 10:1. We describe a case of an atrophic dermatofibroma on the back of an elderly man. Skin biopsy demonstrated a spindle cell proliferation in a storiform pattern, loss of elastic fibers, and substantial atrophy of both the underlying dermis and subcutaneous tissue. An aggregation of elastic fibers was found in the periphery of the tumor. These histologic features supported the diagnosis of atrophic dermatofibroma. The dermal and adipocyte atrophy was likely responsible for the retracted appearance of the lesion.

Keywords: atrophic dermatofibroma, dermatofibroma, subcutaneous atrophy, dermal atrophy, elastic fibers

Introduction

Dermatofibroma (DF), also known as cutaneous benign fibrous histiocytoma, is a common skin lesion

that most frequently presents clinically as a red-brown nodule with increased pigmentation in the periphery [1, 2]. Atrophic DF is a variant of DF first reported in 1987 by Page and Assaad [3]; it is believed to represent between 1-2% of DF [1, 4]. Atrophic DF presents as a depressed or retracted erythematous lesion [5] and it is typically asymptomatic but pruritus has been reported [6]. Both DF and atrophic DF most commonly occur on trunk and extremities in adults [2, 4, 7, 8]. However, atrophic DF has a strong female preponderance of 10:1, compared to that of 5:1 in DF [8, 9]. Herein we report an atrophic DF in an elderly man with the characteristic histopathological findings.

Case Synopsis

On cutaneous examination of a 64-year-old man, an incidental scar-like lesion on the right back was noted. The patient denied a history of trauma or injections to the area and he had no significant past medical history. Physical exam revealed a 12×8mm ill-defined border, indented erythematous plaque on right mid back (Figure 1). Dermoscopy demonstrated an ill-defined erythematous lesion with stellate white scar-like area and white-to-yellow lobules corresponding to sebaceous hyperplasia. No distinct vascular pattern was appreciated (Figure 2). A punch biopsy was performed with a differential diagnosis of scar, DF, dermatofibrosarcoma

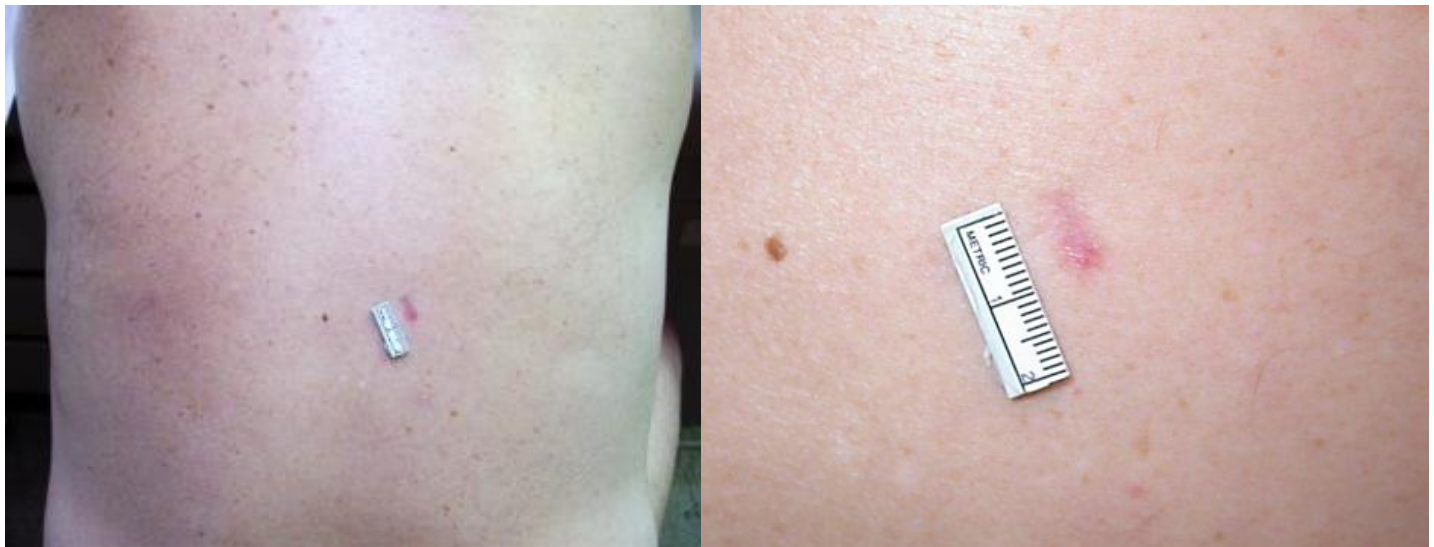

Figure 1. Erythematous atrophic plaque on right mid back.

protuberans (DFSP), morphea, atrophoderma, and sclerosing basal cell carcinoma.

Histopathology revealed epidermal acanthosis and subtle hyperpigmentation, as well as dermal atrophy related to the reduction and replacement of the involved upper dermis with sclerotic collagen bundles and sebaceous hyperplasia (Figure 3). In the dermis, a spindle cell proliferation in a storiform appearance was noted. The proliferation of fibroblasts appeared responsible for the induction of dermal adnexal structures and markedly large sebaceous glands. The underlying subcutaneous tissue showed marked atrophy, with significant

adipocyte reductions (Figure 4), whereas the deep dermis was unremarkable. Verhoeff-Van Gieson elastic staining revealed a diffuse reduction in elastic tissue and an aggregation of elastic fibers at the periphery (Figure 5). These histologic features supported the diagnosis of atrophic dermatofibroma. The patient was counseled about its benign nature, and no further treatment was undertaken.

Case Discussion

In our experience (J.T.), the incidence of atrophic DF is quite rare. Of 214 DF cases seen over one year, the least common histologic type was atrophic DF (1 case, 0.46 %), followed by DF with monster cells (2 cases, 0.93 %), and cellular variant (4 cases, 1.87 %). Literature review supports our experience on the rare incidence of atrophic DF [1, 4]. The rarity of reports of atrophic DF is likely related to the lack of biopsies performed on such lesions owing to their benign clinical appearance. Our report highlights features of atrophic DF that are rarely described, including the dermoscopic findings of the lesion and atrophy of adipose tissue on histopathological exam.

It has been suggested that atrophic dermatofibroma (DF) represents the end-stage DF. This concept is reinforced by the association of older age with atrophic DF in comparison to DF [7, 9]. Yet the etiology of atrophic DF remains to be elucidated.

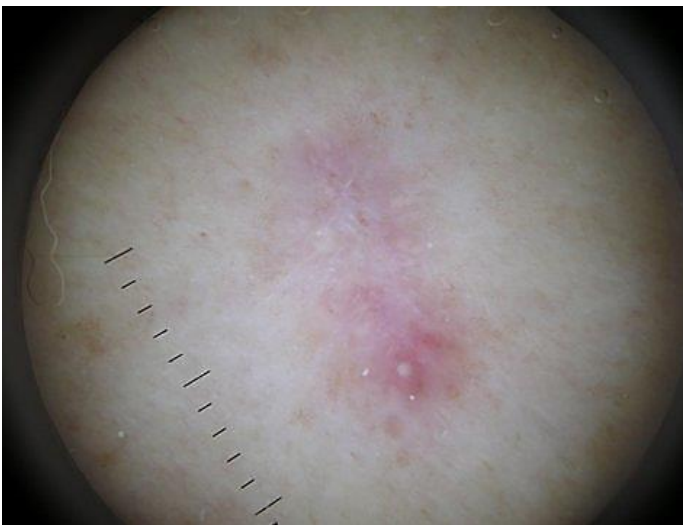


Figure 2. Dermoscopy revealed an ill-defined erythematous lesion with stellate white scar-like area and lobules corresponding to sebaceous hyperplasia. No distinct vascular pattern was appreciated.

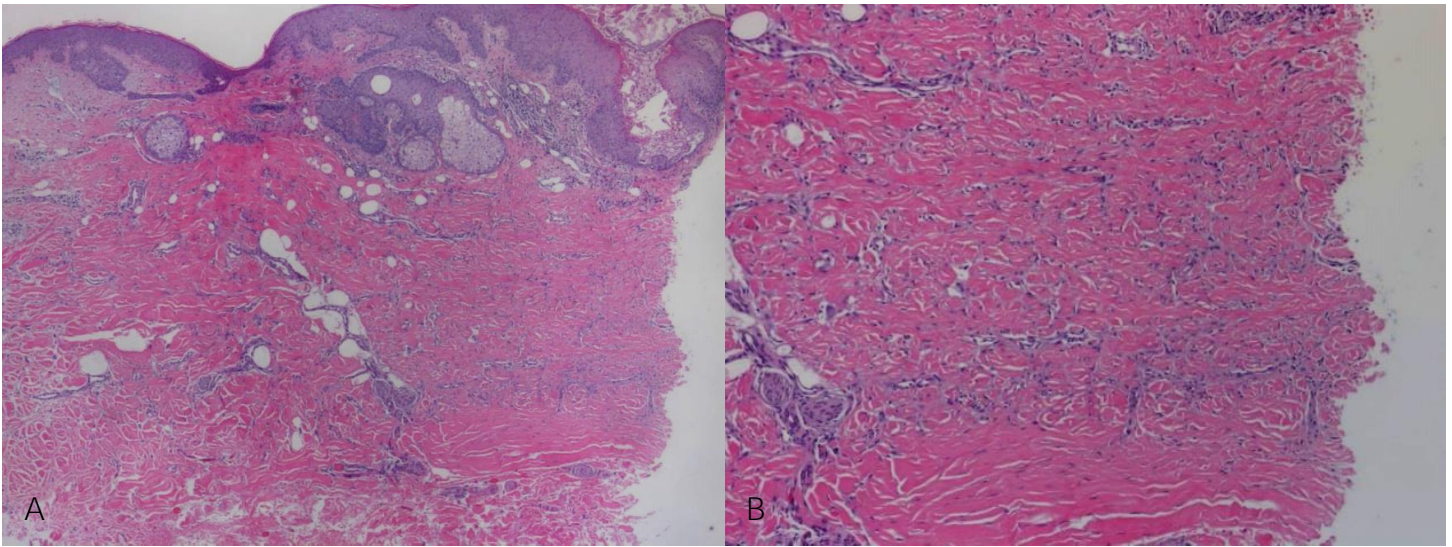


Figure 3. A) H&E stained section of the specimen revealed induction of sebaceous glands in upper dermis with epidermal hyperplasia and subtle basal layer hyperpigmentation. Compared to the adjacent normal dermis on the left, atrophy of the involved upper dermis on the right is demonstrated by the reduction and replacement of the upper dermis with sebaceous hyperplasia. Dense sclerotic collagen with marked hypercellularity is also noted in the involved dermis. 100 \times . B) On higher magnification, proliferating fibroblasts and dense sclerotic collagen bundles in the upper dermis were noted. H&E, 200 \times .

Histologically “typical” DF and atrophic DF are both characterized by variable sclerosis with young and mature collagen as well as proliferating histiocytes and fibroblast-like spindle cells [3, 5]. Other distinctive features common to DF, and appreciated in our histological examination, include epidermal hyperplasia and basal layer hyperpigmentation as well as dermal proliferation of sebaceous components and the presence of dense sclerotic collagen bundles [6, 10].

A significant reduction in the involved dermis – described as less than 50% of the adjacent dermis – is unique to atrophic DF [4]. This characteristic explains the sunken appearance and texture found in the lesion. The underlying dermal and adipocyte tissue in our specimen was markedly reduced and showed significant atrophy, as evidenced by the replacement of the upper dermis with sebaceous hyperplasia (Figure 3A) and by the collapse of the lipocyte membranes (Figure 4). We suggest that both the fat and dermal atrophy are responsible for the retracted appearance of the lesion.

Our patient’s lesion had an absence of elastic fibers (Figure 5). To our knowledge, loss of elastic tissue has only been described in two other cases of atrophic DF [9, 11]. Kiyohara et al. suggested that the etiology of the tumor could be related to this

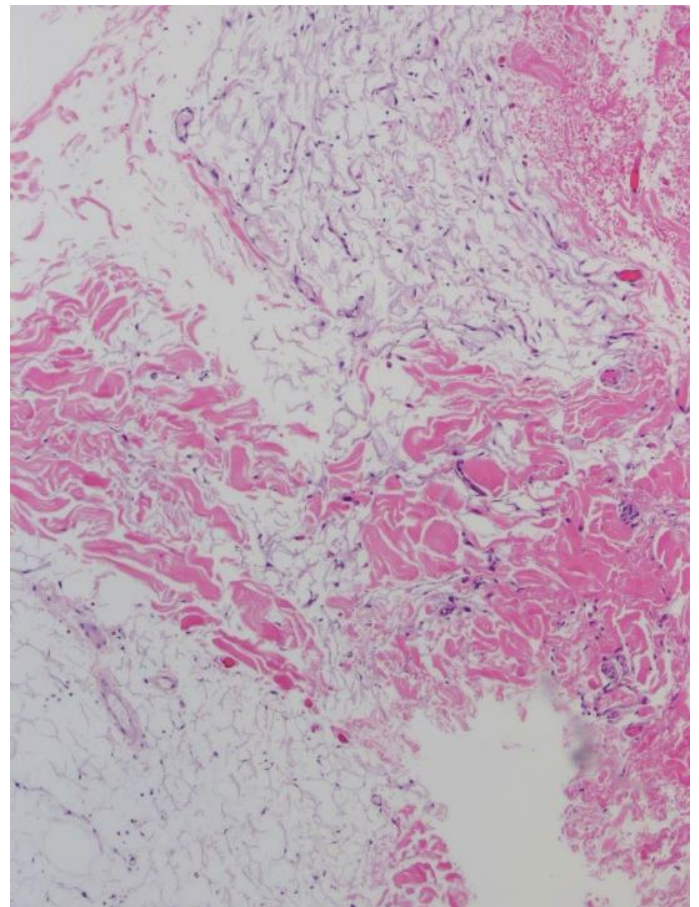


Figure 4. High power (200 \times) view of H&E stained of specimen section shows subcutaneous tissue with atrophy in upper portion showing wrinkling of lipocyte membranes.

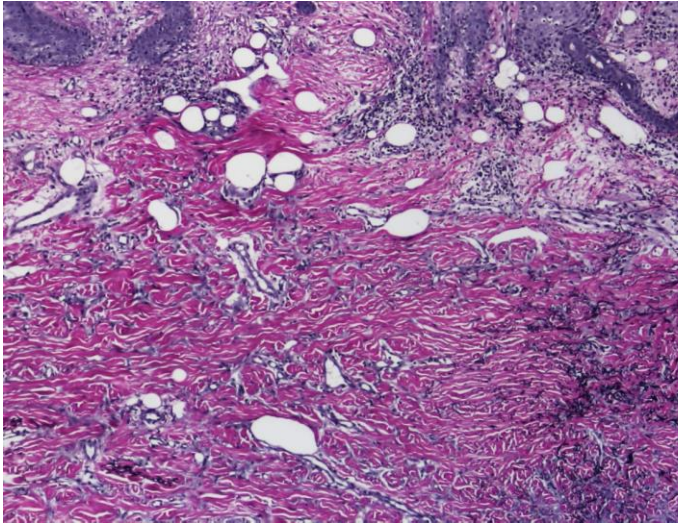


Figure 5. *Verhoeff-Van Gieson elastic staining, revealed loss of elastic fibers in the tumor with compression of normal elastic fibers at the periphery (100×). An elastic tissue aggregate was appreciated on the right side of the image.*

absence of elastic fibers, specifically a result of the process of elastophagocytosis [11]. Ohnishi et al., reported an atrophic DF with a concentrated buildup of elastic tissue around medium sized vessels. They speculated that the atrophy found in atrophic DF could be connected to elastic accumulation around vessels [9]. In our case there was no perivascular aggregation of elastic fibers; instead, a peripheral aggregation of elastic tissue was noted.

Atrophic variants of not only DF but also DFSP have been described. Both atrophic variants have been most frequently described on the upper trunk of females [4]. A study by Zelger et al. found atrophic DFSP to have significant infiltration of the subcutaneous tissue in an irregular pattern with no

dermal sclerosis or epidermal acanthosis [4]. In contrast, atrophic DF was marked by sclerosis, epidermal acanthosis, and a distinctive silhouette demarcating the lower margin of the lesion [4]. As DFSP is a malignant tumor, it is imperative that atrophic variants of DF be investigated to exclude DFSP. Immunohistochemical staining was not performed in our case as the distinctive histologic features and clear delineation of the lesion from the unaffected tissue pointed strongly to DF. Nevertheless, these distinctions should be kept in mind upon management of fibrohistiocytic lesions.

The dermoscopic appearance of atrophic DF has been reported as a patchy distribution of numerous, discreet scar-like areas with a pigment network [2]. **Dermoscopy of our patient's lesion did not fit this description, but rather revealed a homogenous erythematous area surrounding a white patch and lobules (Figure 2). The lesion corresponded more closely with the description of a central white scar-like patch with interspersed globules that is associated with "typical" DF [2].**

Conclusion

In summation we report an atrophic DF in an elderly man, which is distinctive from the established strong association of atrophic DF in women. The lesion was notable for both dermal and adipocyte atrophy as well as a loss of elastic fibers. Atrophic DF should be considered in the differential diagnosis of inwardly puckering lesions.

References

1. Alves JV, Matos DM, Barreiros HF, Bartolo EA. Variants of dermatofibroma--a histopathological study. *An Bras Dermatol*. 2014 May-Jun;89(3):472-7. [PMID: 24937822].
2. Kilinc Karaarslan I, Gencoglan G, Akalin T, Ozdemir F. Different dermoscopic faces of dermatofibromas. *J Am Acad Dermatol*. 2007 Sep;57(3):401-6. [PMID: 17560684].
3. Page EH, Assaad DM. Atrophic dermatofibroma and dermatofibrosarcoma protuberans. *J Am Acad Dermatol*. 1987 Dec;17(6):947-50. [PMID: 3429722].
4. Zelger BW, Ofner D, Zelger BG. Atrophic variants of dermatofibroma and dermatofibrosarcoma protuberans. *Histopathology*. 1995 Jun;26(6):519-27. [PMID: 7545142].
5. Hendi A, Jukic DM, Kress DW, Brodland DG. Atrophic dermatofibroma: a case report and review of the literature. *Dermatol Surg*. 2002 Nov;28(11):1085-7. [PMID: 12460310].
6. Mota AN, Tortelly VD, Obadia DL, Silva RS. Atrophic dermatofibroma. *An Bras Dermatol*. 2013 Sep-Oct;88(5):793-5. [PMID: 24173186].
7. Beer M, Eckert F, Schmoeckel C. The atrophic dermatofibroma. *J Am Acad Dermatol*. 1991 Dec;25(6 Pt 1):1081-2. [PMID: 1810988].
8. Curco N, Pagerols X, Garcia M, Tarroch X, Vives P. Atrophic dermatofibroma accompanied by aneurysmatic characteristics. *J Eur Acad Dermatol Venereol*. 2006 Mar;20(3):331-3. [PMID: 16503899].
9. Ohnishi T, Sasaki M, Nakai K, Watanabe S. Atrophic dermatofibroma. *J Eur Acad Dermatol Venereol*. 2004 Sep;18(5):580-

83. [PMID: 15324399].
11. Fuciarelli K, Cohen PR. Sebaceous hyperplasia: a clue to the diagnosis of dermatofibroma. *J Am Acad Dermatol*. 2001 Jan;44(1):94-5. [PMID: 11148483].
12. Kiyohara T, Kumakiri M, Kobayashi H, Ohkawara A, Lao LM. Atrophic dermatofibroma. Elastophagocytosis by the tumor cells. *J Cutan Pathol*. 2000 Jul;27(6):312-5. [PMID: 10885409].