

# UC Davis

## Dermatology Online Journal

### Title

Infliximab-induced amicrobial pustulosis of the folds in a patient with Crohn disease

### Permalink

<https://escholarship.org/uc/item/3z30h45r>

### Journal

Dermatology Online Journal, 30(1)

### Authors

Meyer, Summer N

Myers, Bridget

Caro-Chang, Leah Antoinette

et al.

### Publication Date

2024

### DOI

10.5070/D330163286

### Copyright Information

Copyright 2024 by the author(s). This work is made available under the terms of a Creative Commons Attribution-NonCommercial-NoDerivatives License, available at

<https://creativecommons.org/licenses/by-nc-nd/4.0/>

Peer reviewed

# Infliximab-induced amicrobial pustulosis of the folds in a patient with Crohn disease

Summer N Meyer<sup>1</sup> BS, Bridget Myers<sup>1</sup> MD, Leah Antoinette Caro-Chang<sup>1</sup> MD, Danielle M Tartar<sup>1</sup> MD PhD, Peggy Wu<sup>1</sup> MD MPH, Maija Kiuru<sup>1,2</sup> MD PhD, Atrin Toussi<sup>1</sup> MD

Affiliations: <sup>1</sup>Department of Dermatology, University of California Davis Health, Sacramento, California, USA, <sup>2</sup>Department of Pathology and Laboratory Medicine, University of California Davis Health, Sacramento, California, USA

Corresponding Author: Atrin Toussi MD, Dermatology Department, University of California Davis Health, 3301 C Street, Suite 1450, Sacramento CA 95816, Email: [amtoussi@ucdavis.edu](mailto:amtoussi@ucdavis.edu)

Abstract (<200 words): Tumor necrosis factor (TNF) inhibitors may paradoxically induce pustular eruptions, most of which are classified as pustular psoriasis. Amicrobial pustulosis of the folds is a much rarer entity that was recently recognized to occur in the setting of chronic anti-TNF therapy and inflammatory bowel disease, with 12 existing cases in the literature. Amicrobial pustulosis of the folds is a neutrophilic dermatosis characterized by aseptic pustules involving the major and minor skin folds, genital regions, and scalp. Herein, we report an additional case of paradoxical amicrobial pustulosis of the folds induced by chronic infliximab therapy in a patient with Crohn disease.

*Keywords (single words, alphabetized): Crohn disease, infliximab, inflammatory bowel disease, pustulosis, TNF inhibitor*

## Introduction

Anti-tumor necrosis factor (TNF) agents (infliximab, adalimumab, golimumab, certolizumab, and etanercept) have significantly improved the treatment of inflammatory bowel disease (IBD), psoriasis, and rheumatoid arthritis. However, they can paradoxically induce psoriasiform, eczematous, and lichenoid-like skin reactions in 0.6%-5.3% of patients, with Crohn disease (48%) being the most commonly-associated condition [1,2]. Paradoxical pustular eruptions occur in 1% of patients treated with TNF inhibitors, consisting mainly of pustular psoriasis and rarely, amicrobial pustulosis of the skin folds (APF) with only 12 cases reported in the

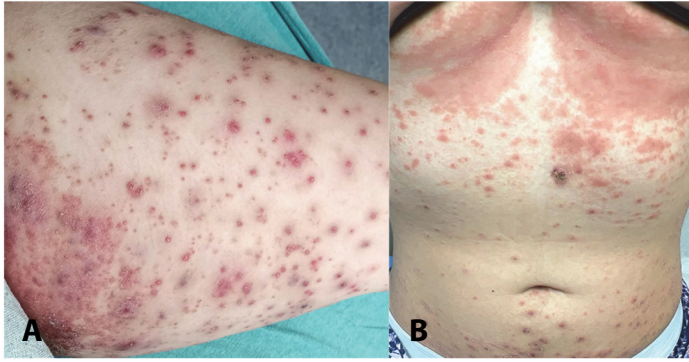
literature [3-6], to our knowledge. Interestingly, these all occurred in patients with inflammatory bowel disease.

Amicrobial pustulosis of the skin folds is a recently described entity characterized by aseptic pustules involving the major and minor skin folds, genital regions, and scalp [7]. It is considered a neutrophilic dermatosis that occurs in the setting of an autoimmune condition, frequently affecting young females. Herein, we report a unique case of infliximab-induced APF in a woman with Crohn disease that improved with topical corticosteroids and discontinuation of infliximab.

## Case Synopsis

A 19-year-old woman presented to the emergency department with three months of an intermittently pruritic and painful crusted pustular rash primarily involving the axilla, groin, retroauricular area, and gluteal and inframammary folds with isolated lesions scattered on the trunk and extremities. The patient had a history of Crohn disease that was well-controlled with infliximab infusions (5mg/kg) every six weeks for the past 3.5 years. One week prior to admission, she was seen by her primary care physician and given topical hydrocortisone and a five-day course of low dose oral corticosteroids without improvement in the eruption.

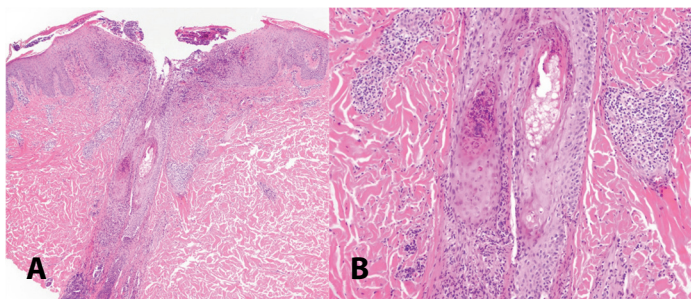
The patient reported piercing her ears and eyebrows shortly before the rash developed, which caused local skin irritation. She denied any other identifiable triggers or new exposures. Review of symptoms was



**Figure 1. A)** Erythematous crusted papules and pustules on the left leg with clustering in the inguinal fold. **B)** Erythematous papules and pustules scattered on the abdomen with clustering in the inframammary folds.

negative for fever, chills, recent illnesses, abdominal pain, or diarrhea. There was no history of extraintestinal involvement of her Crohn disease, systemic lupus erythematosus, psoriasis, or eczema.

On examination, there were numerous erythematous, weeping papules and pustules on the bilateral legs, arms, and abdomen with clustering in intertriginous areas including the retroauricular area, inguinal, inframammary, gluteal, and axillary folds (**Figure 1**). There was neither lymphadenopathy nor mucosal involvement. Laboratory testing was significant for leukocytosis (white blood cell count of  $17.6\text{K}/\text{mm}^3$ ; normal range  $4.5\text{--}11.0\text{K}/\text{mm}^3$ ) and elevated international normalized ratio, (1.33; normal  $< 1.1$ ), C-reactive protein, (5.5mg/dL; normal range 0.3-1.0 mg/dL), and erythrocyte sedimentation rate, (22mm/hr; normal  $\leq 20\text{mm}/\text{hr}$ ). HIV and hepatitis panels were negative. Infliximab levels were (18.13), which is within therapeutic range.

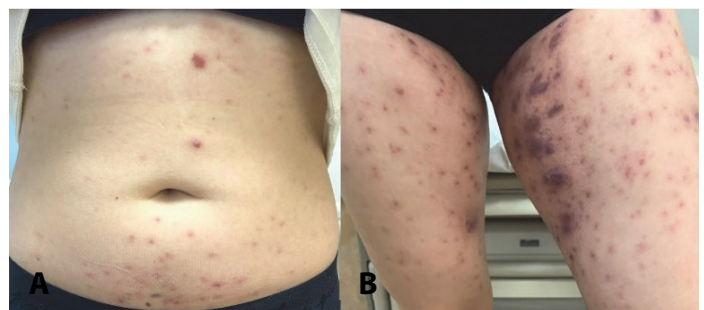


**Figure 2. H&E of biopsy from the central abdomen. A)** Low power view showing collections of neutrophils in the stratum corneum centered at a hair follicle with perivascular and perifollicular neutrophils and lymphocytes, 40 $\times$ . **B)** High power view demonstrating a hair follicle containing neutrophils with perifollicular lymphocytic and neutrophilic infiltrates, 100 $\times$ .

Ultrasound of the left groin was performed due to pain and swelling and showed small abscesses that were subsequently drained and cultured, resulting in growth of methicillin-sensitive *Staphylococcus aureus* (*S. aureus*). Varicella-zoster virus and herpes simplex virus cultures were negative.

Histopathological examination of a punch biopsy taken from the central abdomen showed features of pustular dermatitis and folliculitis with a subcorneal and follicular collection of neutrophils, as well as perivascular and perifollicular lymphocytes and neutrophils (**Figure 2**). Periodic Acid-Schiff with diastase and Gram stains were negative. Direct immunofluorescence (DIF) was nonspecific revealing scant deposition of IgM highlighting some of the superficial dermal vessels without deposition of fibrinogen, complement, or other immunoglobulins. Combined with the clinical history, the histological differential diagnosis included amicrobial pustulosis of the folds associated with infliximab, suppurative folliculitis, and less likely anti-TNF-induced pustular psoriasis or acute generalized exanthematous pustulosis (AGEP).

The patient was treated with a course of trimethoprim/sulfamethoxazole and topical clobetasol, resulting in significant improvement for the following 20 days. The patient then received an infliximab infusion and had worsening of the eruption with increased pain and multiple new draining pustules on the extremities. Given the clear temporal association of infliximab and the pustulosis, the diagnosis of infliximab-induced paradoxical APF was established and her medication was switched from infliximab to Ustekinumab, an



**Figure 3. Resolving pustulosis after receiving treatment, demonstrating erythematous to violaceous papules with post-inflammatory hyperpigmentation on the abdomen and bilateral legs.**

anti-IL12/23 monoclonal antibody, resulting in significant improvement. The patient's eruption continues to improve with oral doxycycline 100mg/day and topical clobetasol 0.05% at one month follow-up (**Figure 3**).

## Case Discussion

Herein, we report a unique case of APF in a patient with Crohn disease while on chronic infliximab therapy, highlighting the expanding spectrum of paradoxical cutaneous reactions associated with anti-TNF medications. The described case was diagnostically challenging and required clinicopathological correlation. At initial presentation, the clinical differential was broad and included extraintestinal involvement of Crohn disease such as vesiculopustular eruption of inflammatory bowel disease and pustular pyoderma gangrenosum, acute generalized exanthematous pustulosis, subcorneal pustular dermatosis (Sneddon-Wilkinson disease), suppurative folliculitis, pyodermitis vegetans, and anti-TNF-induced cutaneous reactions including paradoxical pustular psoriasis (generalized pustular psoriasis and palmoplantar pustular psoriasis), APF, and hidradenitis suppurativa. These are characterized in **Table 1**. The clinical features including the intertriginous location and temporal association with infliximab combined with the histological features were most suggestive of anti-TNF-induced APF.

Amicrobial pustulosis of the skin folds is characterized by relapsing, symmetric pustular lesions involving the major skin folds (axillary, groin, and intermammary), minor skin folds (retroauricular area, external auditory meatus, interdigital spaces, nostrils), scalp, and anogenital area [4,7]. Since its initial description in 1991 by Crickx et al. [8], APF has been reported to occur in various autoimmune conditions including systematic and cutaneous lupus erythematosus, inflammatory bowel disease, scleroderma, antiphospholipid syndrome, celiac disease, undifferentiated connective tissue disease, and Hashimoto thyroiditis among others [7,9-16]. Characteristic lesions begin as small pustules that coalesce into erosive crusted plaques [7]. Microbiological cultures from unopened pustules

are consistently negative, although older or opened pustules commonly grow *S. aureus*, as observed in our case [12]. Classic histological features include intraepidermal, subcorneal spongiform abscesses, and a mixed dermal inflammatory infiltrate consisting of neutrophils and lymphocytes [4,7]. Features of neutrophilic folliculitis and perifolliculitis are also commonly described, demonstrated by our case [4]. Direct immunofluorescence microscopy is typically negative or nonspecific [7]. Additionally, inflammatory markers may be elevated and serum autoantibodies associated with the underlying autoimmune condition can be present. Based on these characteristic features, Marzano et al. [7] proposed a set of diagnostic criteria for APF (outlined in **Table 2**), although additional validation studies are needed to confirm its diagnostic accuracy.

An increasing number of paradoxical cutaneous reactions have been identified since the introduction of anti-TNF therapy. Pustular eruptions, representing the most common paradoxical skin reactions associated with anti-TNF therapy, frequently manifest as palmoplantar pustular psoriasis, with localized pustules affecting the palms and soles. Anti-TNF-induced APF, on the other hand, is a much rarer occurrence with only 12 existing cases in the literature [3-6]. Interestingly, all cases including ours, occurred in those with Crohn disease (12/13) or ulcerative colitis (1/13) while on chronic adalimumab (7/13) or infliximab (6/13) therapy, highlighting the association between inflammatory bowel disease and anti-TNF-induced APF.

Based on the limited reports of anti-TNF-induced APF, discontinuation of the inciting TNF-inhibitor in combination with topical corticosteroids and/or oral corticosteroids often results in resolution. Further, switching to ustekinumab, like in our present case, has had good anecdotal success in keeping APF in remission while controlling the underlying IBD [3-5].

The pathogenesis of anti-TNF-induced APF is unclear. However, it is postulated that the blockade of TNF results in an upregulation of interferon-alpha from plasmacytoid dendritic cells contributing to a cytokine imbalance and ongoing immune dysregulation in genetically susceptible individuals [3,4]. This is based on studies that found higher

expression of pro-inflammatory cytokines in the lesional skin of patients with anti-TNF-induced APF compared to controls, including type 1 IFNs, interleukin-1 beta, TNF, IL17, tissue damage effector molecules, and chemokines involved in neutrophil recruitment and transendothelial migration such as IL8, CXCL 1/2/3, CXCL 16, and RANTES [3,4,17].

### Conclusion

We report an additional case of APF following infliximab therapy in a patient with Crohn disease to increase physician awareness of this rare paradoxical cutaneous reaction associated with TNF inhibitors in IBD. Additionally, we highlight the importance of clinicopathological correlation and therapeutic

**Table 1.** Clinical and histopathological features for the differential diagnoses considered in our present case.

Disease	Epidemiology	Clinical features	Histopathological features
Amicrobial pustulosis of the folds [4,7,8]	Predominately young females; associated with autoimmune conditions	Symmetric eruption of sterile pustules involving the major and minor skin folds, scalp, and anogenital area	Intraepidermal, subcorneal spongiform abscesses, neutrophilic and lymphocytic dermal infiltrate; negative DIF
Pustular psoriasiform eruptions associated with anti-TNF therapy [18,19]	2:1 female-to-male ratio	Localized pustulosis of the palms and soles (palmoplantar pustulosis); or widespread pustulosis (generalized pustular psoriasis)	Elongated rete ridges of even lengths, parakeratosis, epidermal hyperplasia, intraepidermal pustules, dilated capillaries
Vesiculopustular eruption of IBD/pustular pyoderma gangrenosum [20]	More common in UC than Crohn's disease	Papulopustules distributed on the trunk and limbs, progress into ulcerations; correlates with IBD flare	Interfollicular subcorneal and intraepidermal neutrophilic abscesses with a mixed dermal infiltrate
Acute generalized exanthematous pustulosis [21,22,23]	Caused by drugs, most commonly antibiotics, antifungals, diltiazem, and antimalarials	Nonfollicular sterile pustules on erythematous base with superficial desquamation affecting face and intertriginous areas	Intracorneal, subcorneal, and/or intraepidermal pustules, papillary dermal edema containing neutrophilic and eosinophilic infiltrates
Subcorneal pustular dermatosis (Sneddon-Wilinson disease) [24,25]	Middle-aged women (>40); 4:1 female to male ratio	Recurrent crops of superficial sterile pustules on flexural and intertriginous areas; face and mucosa are typically spared	Subcorneal pustules composed of neutrophils and occasionally eosinophiles, minimal change of epidermis beneath pustule; limited spongiosis, absence of acantholysis
Superficial pustular folliculitis [26]	Caused by <i>Staph aureus</i> ; can arise from insect bites or trauma	Pinhead-size, domed-shaped pustules usually on the scalp, limbs, and perioral area	Moderate inflammatory infiltrates in the follicular ostium and surrounding the upper regions of the follicle
Pyodermitis vegetans [27,28]	Associated with IBD, more common in UC than Crohn's disease; common in middle aged men	Large vesiculopustular, exudative, vegetating plaques in the inguinal and axillary folds, face, and scalp; mucosal lesions with "snail-track" appearance are common (Pyostomatitis vegetans)	Pseudoepitheliomatous hyperplasia, intraepidermal and subepidermal neutrophilic and/or eosinophilic microabscesses; DIF negative or weakly positive
Hidradenitis suppurativa [29,30]	Common in women aged 30-39, 3:1 female-to-male ratio; associated with inflammatory conditions	Chronic deep seeded abscesses, draining tracts, and fibrotic scars in axillary, groin, perianal, perineal, and inframammary areas	Follicular occlusion, follicular hyperkeratosis, hyperplasia of follicular epithelium, perifolliculitis, neutrophilic abscesses, sinus tracts, dense fibrosis

DIF, direct immunofluorescence; IBD, inflammatory bowel disease; TNF, tumor necrosis factor; UC, ulcerative colitis.

context in differentiating paradoxical APF from other pustular dermatoses.

## Potential conflicts of interest

The authors declare no conflicts of interest.

**Table 2.** Diagnostic criteria for amicrobial pustulosis of the folds from Marzano et al. (2008), [7].

The diagnosis of APF can be made if all obligate criteria and 1 or more minor criteria are met.

Obligate criteria	Minor criteria
1. Pustulosis involving 1 or more major folds, 1 or more minor folds, and the anogenital area	1. Presence of an underlying autoimmune or autoinflammatory disorder
2. Histological pattern showing intraepidermal spongiform pustules and a dermal inflammatory infiltrate consisting of mainly neutrophils	2. Positive ANA titer of 1/160 or higher
3. Negative culture from an unopened pustule	3. Presence of at least 1 serum autoantibody (such as, but not limited to, anti-ENA, anti-dsDNA, anti-smooth-muscle, antimitochondrial, anti-gastric-parietal-cell, antiendomysial)

ANA, antinuclear antibodies; APF, amicrobial pustulosis of the folds; dsDNA, double stranded DNA.; ENA, extractable nuclear antigens

## References

- Mazloom SE, Yan D, Hu JZ, et al. TNF- $\alpha$  inhibitor-induced psoriasis: A decade of experience at the Cleveland Clinic. *J Am Acad Dermatol.* 2020;83:1590-8. [PMID: 30576759].
- Ko JM, Gottlieb AB, Kerbleski JF. Induction and exacerbation of psoriasis with TNF-blockade therapy: A review and analysis of 127 cases. *J of Dermatol Treat.* 2009;20:100-8. [PMID: 18923992].
- Marzano AV, Tavecchio S, Berti E, et al. Paradoxical Autoinflammatory Skin Reaction to Tumor Necrosis Factor Alpha Blockers Manifesting as Amicrobial Pustulosis of the Folds in Patients with Inflammatory Bowel Diseases. *Medicine.* 2015;94:e1818. [PMID: 26559252].
- Lee HY, Pelivani N, Beltraminelli H, et al. Amicrobial pustulosis-like rash in a patient with Crohn's disease under anti-TNF-alpha blocker. *Dermatology.* 2011;222:304-10. [PMID: 21757882].
- Zirwas M, Dobkin HE, Krishnamurthy S. Amicrobial pustulosis of the folds and palmoplantar pustulosis simultaneously induced by different tumor necrosis factor- $\alpha$  inhibitors: Demonstration of a shared pathophysiology. *JAAD Case Rep.* 2017;3:401-3. [PMID: 28879224].
- Balaguer-Franch I, Hernández de la Torre-Ruiz E, Lacasta-Plasin C, et al. Pustular lesions in patients with Crohn disease and treatment with tumour necrosis factor- $\alpha$  inhibitors. *Clin Exp Dermatol.* 2022;47:453-5. [PMID: 34431537].
- Marzano AV, Ramoni S, Caputo R. Amicrobial pustulosis of the folds: Report of 6 cases and a literature review. *Dermatology.* 2008;216:305-11. [PMID: 18230977].
- Crickx B, Diego ML, Guillevin L, et al. Pustulose amicrobienne et lupus érythémateux systémique. *Journées Dermatologiques de Paris.* 1991.
- Schissler C, Velter C, Lipsker D. Amicrobial pustulosis of the folds: Where have we gone 25years after its original description? *Ann Dermatol Venereol.* 2017;144:169-75. [PMID: 28242094].
- Kerl K, Masouyé I, Lesavre P, et al. A case of amicrobial pustulosis of the folds associated with neutrophilic gastrointestinal involvement in systemic lupus erythematosus. *Dermatology.* 2005;211:356-9. [PMID: 16286747].
- Antille C, Frei M, Sorg O, et al. Amicrobial pustulosis of the folds associated with auto-immune disorders. A case report with an analysis of cytokine expression profile in skin lesions of cutaneous neutrophilic lupus. *Dermatology.* 2008;216:324-9. [PMID: 18230981].
- Lagrange S, Chosidow O, Piette JC, et al. Peculiar form of amicrobial pustulosis of the folds associated with systemic lupus erythematosus and other auto-immune diseases. *Lupus.* 1997;6:514-20. [PMID: 9256309].
- Marzano AV, Capsoni F, Berti E, et al. Amicrobial pustular dermatosis of cutaneous folds associated with autoimmune disorders: A new entity? *Dermatology.* 1996;193:88-93. [PMID: 8884141].
- Saiag P, Blanc F, Marinho E, et al. Amicrobial pustulosis associated with systemic lupus erythematosus: Report of a case. *Ann Dermatol Venereol.* 1993;120:779-81. [PMID: 8210111].
- López-Navarro N, Alcaide A, Gallego E, et al. Amicrobial pustulosis of the folds associated with Hashimoto's thyroiditis. *Clin Exp Dermatol.* 2009;34:e561-e3. [PMID: 19549241].
- Stefanidou MP, Kanavaros PE, Stefanaki KS, Tosca AD. Amicrobial pustulosis of the folds. A cutaneous manifestation associated with connective tissue disease. *Dermatology.* 1998;197:394-6. [PMID: 9873184].
- Marzano AV, Tavecchio S, Berti E, et al. Cytokine and chemokine profile in amicrobial pustulosis of the folds evidence for autoinflammation. *Medicine.* 2015;94. [PMID: 26683967].