

# UC Davis

## Dermatology Online Journal

### Title

Successful treatment of pityriasis lichenoides chronica with narrow-band ultraviolet B therapy in a patient with Keratitis-Ichthyosis-Deafness syndrome: a case report

### Permalink

<https://escholarship.org/uc/item/3sd5h1n2>

### Journal

Dermatology Online Journal, 22(5)

### Authors

Salman, Andac  
Gencosmanoglu, Dilek Seckin  
Yucelten, Ayse Deniz  
et al.

### Publication Date

2016

### DOI

10.5070/D3225030946

### Copyright Information

Copyright 2016 by the author(s). This work is made available under the terms of a Creative Commons Attribution-NonCommercial-NoDerivatives License, available at <https://creativecommons.org/licenses/by-nc-nd/4.0/>

Peer reviewed

## Case Presentation

### Successful treatment of pityriasis lichenoides chronica with narrow-band ultraviolet B therapy in a patient with Keratitis-Ichthyosis-Deafness syndrome: a case report

Andac Salman<sup>1</sup>, Dilek Seckin Gencosmanoglu<sup>1</sup>, Ayse Deniz Yucelten<sup>1</sup>, Nursel Elcioglu<sup>2</sup>, Gabriele Richard<sup>3</sup>, Cuyan Demirkesen<sup>4</sup>

Dermatology Online Journal 22 (5): 7

<sup>1</sup> Marmara University, School of Medicine, Department of Dermatology, Istanbul

<sup>2</sup> Marmara University School of Medicine, Department of Pediatrics, Subdivision of Genetics, Istanbul

<sup>3</sup> GeneDx, Gaithersburg, Maryland

<sup>4</sup> Istanbul University Cerrahpasa School of Medicine, Department of Pathology, Istanbul

#### Correspondence:

Andac Salman, MD  
Department of Dermatology  
Pendik Research and Application Hospital  
Marmara University, School of Medicine  
Fevzi Cakmak Mah, Mimar Sinan Cad. No:41  
34899 Pendik, Istanbul, Turkey  
Email: asalmanitf@gmail.com, andac.salman@marmara.edu.tr

---

## Abstract

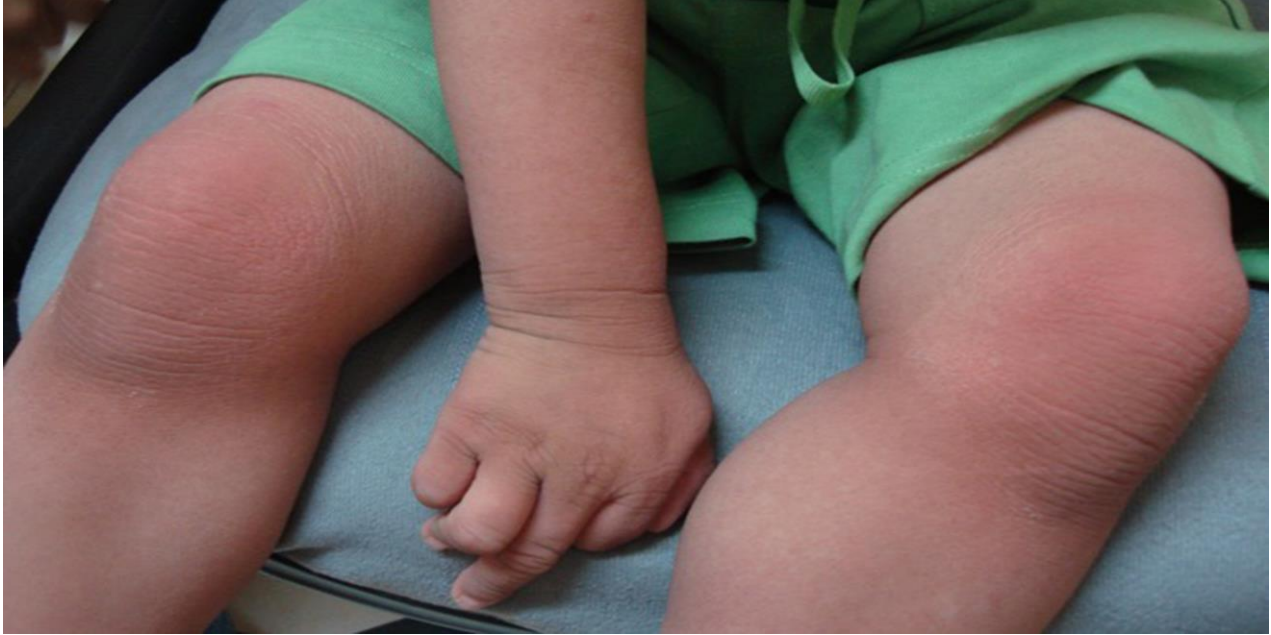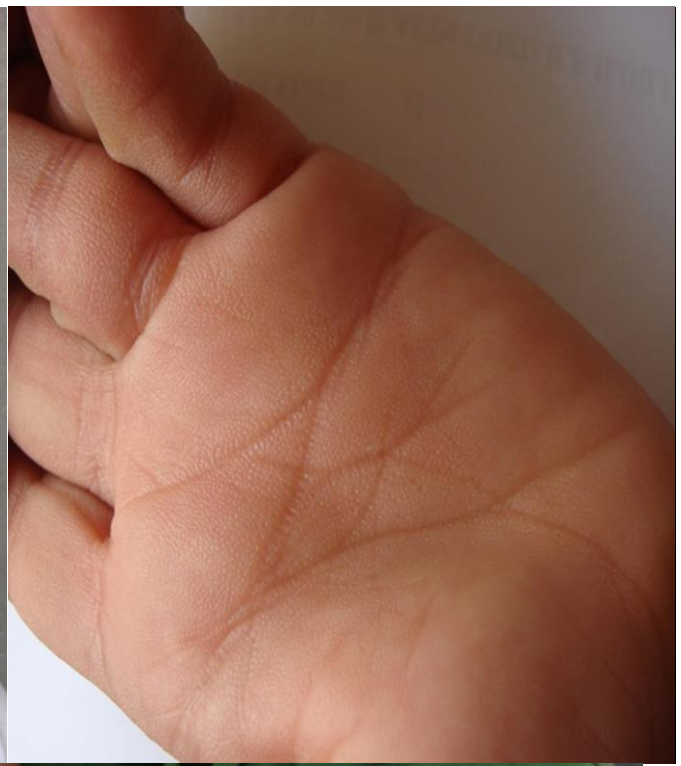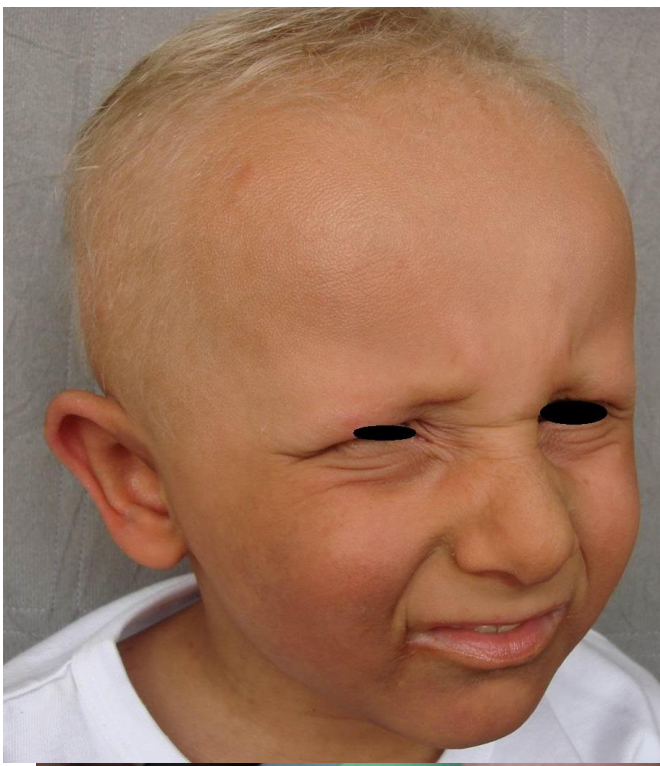
Keratitis-ichthyosis-deafness (KID) syndrome is a rare genodermatosis causing ichthyosis-like skin lesions, keratitis, and deafness. Herein, we report a patient with this rare syndrome in association with pityriasis lichenoides chronica, which was successfully treated with narrow-band ultraviolet B phototherapy despite our concerns regarding the increased risk of squamous cell carcinoma, hyperpyrexia, and keratitis.

## Introduction

Keratitis-ichthyosis-deafness (KID) syndrome is characterized by the association of ichthyotic skin lesions with vascularizing keratitis and sensorineural hearing loss. There is also an increased risk of squamous cell carcinoma [1]. Herein we present a 6-year-old boy with KID syndrome and pityriasis lichenoides chronica (PLC), which was successfully treated with narrow-band ultraviolet B phototherapy without any adverse effects.

## Case synopsis

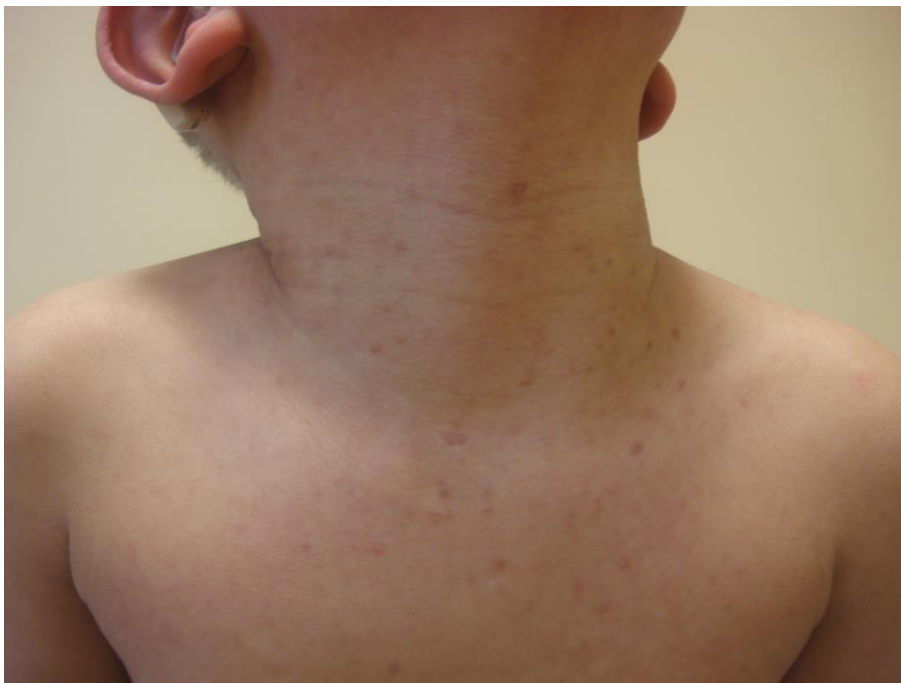A 4-year-old boy presented with generalized skin thickening with accentuation over extensor surfaces of joints, palmoplantar keratoderma with a grainy, cobblestone-like surface, fine, sparse, hair, and severe bilateral sensorineural hearing loss (Figure 1-3).



**Figure 1.** Sparse and light-colored scalp hair, sparse eyebrows, and photophobia. **Figure 2.** Palmar leathery-pebbly hyperkeratosis. **Figure 3.** Hyperpigmented and hyperkeratotic thickening of skin over extensor surfaces of joints.

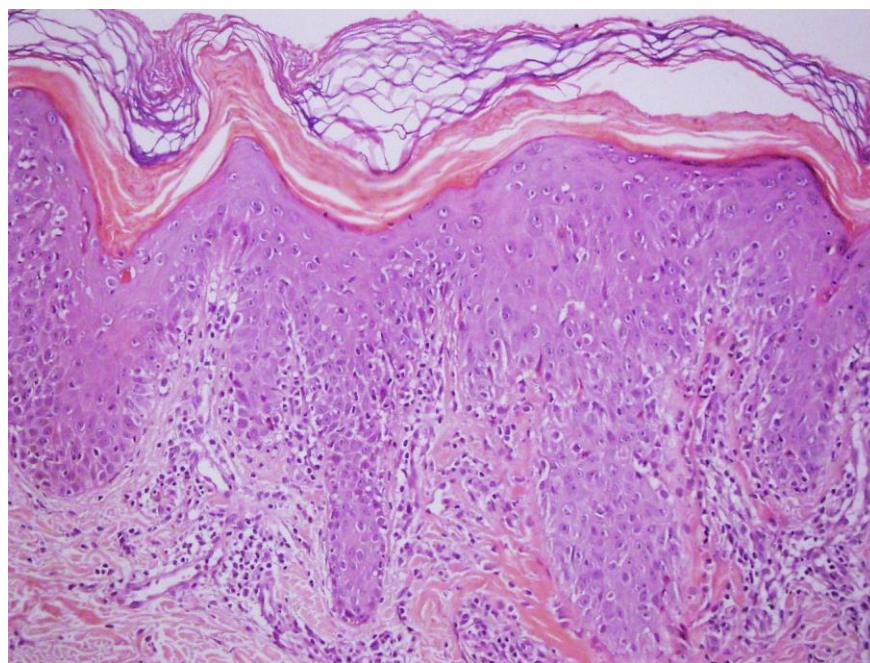
He had some photophobia but eye examination was normal. He also had bilateral achilles tendon shortening with toe walking, which was corrected with surgery at the age of 3. Although two previous skin biopsies showed the presence of sweat glands, the patient had hypohidrosis and the mother described episodes of hyperpyrexia during summer months. Genetic analysis revealed the D50N missense mutation in the connexin 26 gene, which confirmed the clinical diagnosis of keratitis-ichthyosis-deafness (KID) syndrome.

Later during the follow-up, at 6 years of age, he presented with asymptomatic scaly, red papules widely distributed over the trunk and extremities (Figure 4).



**Figure 4.** Erythematous, scaly papules over the anterior aspect of trunk and neck.

Histopathological examination of a punch biopsy revealed lichenoid dermatitis with hydropic degeneration of the basal cell layer, confluent parakeratosis, and dyskeratotic cells, confirming the diagnosis of PLC (Figure 5).



**Figure 5.** Lichenoid dermatitis with confluent parakeratosis with plasma and neutrophils, acanthosis, dyskeratotic cells, and exocytosis. Note the extravasated erythrocytes in the upper dermis with a perivascular inflammatory cell infiltration (H&E, 100x).

There were no eosinophils within the dermis. Follicular hyperkeratosis, seen in the biopsy, was interpreted as a feature of KID syndrome. Since the lesions were not responsive to a 2 month course of oral azithromycin therapy, narrow-band ultraviolet B therapy (Nb-UVB) was initiated. Treatment was performed twice a week giving an extra emphasis to ocular, facial, and genital protection. Extensive and regular use of emollients was recommended to enhance the tolerability to treatment. Treatment began with a dose of  $50\text{mJ}/\text{cm}^2$  and continued with 10% dose increments at every session depending on the erythema response. The maximum dose administered throughout the treatment was  $130\text{mJ}/\text{cm}^2$ . Lesions resolved completely after 15 sessions completed within 7 weeks with a rather low cumulative UVB dose of  $1250\text{mJ}/\text{cm}^2$ . Treatment was well-tolerated without any adverse effects

except for some milia. He remained disease-free during a 26-month-follow-up, then had a recurrence of PLC. Treatment with Nb-UVB could not be reinitiated owing to difficulties in attending the hospital. Low dose acitretin treatment (10 mg every other day) was started. Our patient's pityriasis lichenoides responded well to this therapy and went into remission. However, the skin lesions related to KID syndrome improved minimally. The patient is still being followed-up for skin cancer with regular full-body skin examinations. Although a longer follow-up is necessary, he hasn't developed any precancerous or cancerous skin lesions for 40 months after being treated with Nb-UVB.

## Discussion

Keratitis-Ichthyosis-Deafness (KID) syndrome is a rare disorder of cornification, which is characterized by vascularizing keratitis, sensorineural hearing loss, and ichthyosis-like, hyperkeratotic skin lesions [1]. KID syndrome is caused by mutations in the GJB2 gene, which encodes connexin 26. Although some familial cases were reported, most of the cases are sporadic [2].

The skin changes usually occur within the first 3 months of life. Most patients develop erythematous, well-demarcated, non-scaling, hyperkeratotic or verrucous plaques favoring the forehead, cheeks, scalp, perioral region, elbows, and knees [3]. Additional cutaneous manifestations include erythrokeratoderma, stippled palmoplantar keratoderma, predisposition to bacterial, candida, and viral mucocutaneous infections, chronically fissured lips, tongue and buccal mucosal lesions, nail dystrophy, hypohidrosis, alopecia, follicular keratosis, follicular occlusion triad, trichilemmal tumors, porokeratotic eccrine ostial and dermal duct nevus, and increased risk of squamous cell carcinomas (SCC) [1-6].

Ocular manifestations develop during childhood and are usually progressive, including vascularizing keratitis, photophobia, dry eyes, blepharitis, eye infections, corneal leukomas, and conjunctivitis [1]. Sensorineural hearing loss is congenital and non-progressive. Cochlear implantation may prevent delay in speech development [6]. Other abnormalities reported in association with KID syndrome include dental abnormalities, pes cavus, contracture of the Achilles tendons, Dandy-Walker malformation/cerebellar hypoplasia, and absence of the mammary glands [4,6,7].

Proper management of KID syndrome requires a multidisciplinary approach by dermatology, ophthalmology, and otolaryngology services. Treatment options include topical retinoids and keratolytics, which have shown limited success, and systemic retinoids with variable efficacy [8]. Close and long-term follow-up of patients for increased risk of mucocutaneous infections and malignancies is essential [6].

Pityriasis lichenoides is a papulosquamous disease of unknown etiology with acute and chronic forms. The chronic variant, PLC, is more prevalent in children and characterized by erythematous scaly papules and residual hypopigmentation. Although spontaneous resolution after weeks to months is seen, it may have a chronic relapsing course. Treatment options for PLC include topical corticosteroids, oral antibiotics such as erythromycin, and phototherapy [9]. In cases of generalized PLC in children, Nb-UVB is reported to be well-tolerated and efficacious [10,11]. To our knowledge, the coexistence of PLC and KID syndrome as in our patient has not been reported to date. It is likely that this association is incidental.

Although the exact mechanism leading to SCC development in KID syndrome remains unclear, carcinogenesis owing to chronic inflammation and impairment in epithelial growth caused by connexin mutations are possible contributing factors [6]. Ultraviolet exposure from sunlight increases the risk of SCC and basal cell carcinomas (BCC). Although psoralen ultraviolet A (PUVA) therapy is associated with an increased risk of SCC and BCC, literature data so far hasn't shown any relation between an increased risk of skin cancer and Nb-UVB treatment in psoriasis patients [12,13]. However, longer follow-up is necessary to learn more precisely about any possible effect of Nb-UVB on skin cancer development. Therefore, in our patient, the cumulative UVB dose was kept as low as possible. UV light therapy has also been used in Netherton syndrome, which is an ichthyotic syndrome with an increased risk of SCC and BCC development. Both UVA1 and Nb-UVB has been reported to successfully treat the ichthyotic and eczematous lesions in Netherton Syndrome [14-17]. Maintenance Nb-UVB treatment was given for 4 years in a patient to prevent exacerbation of atopic dermatitis lesions [14]. PLC lesions in our patient cleared after only 15 sessions. According to our own experience and the results of other investigators [10], 20-25 sessions on average is required for a satisfactory response to phototherapy in PLC patients. Our patient responded rather rapidly to UV treatment.

Widespread distribution of lesions and resistance to prior treatments led us to choose Nb-UVB as a treatment option. Apart from increased risk of SCC, increased risk of keratitis in KID patients and possible hyperpyrexia related to hypohidrosis during phototherapy sessions were our major concerns about instituting phototherapy in our patient. In addition, he was just 6 years old and had difficulty cooperating with the treatment. However, eyes, face, and genital area were carefully protected and the UVB



dose was adjusted to the lowest effective dose. Our patient completed the phototherapy with a complete response without any adverse effects.

## Conclusion

Although there are several reported associations, to our knowledge, this is the first case associated with PLC, which was successfully treated with Nb-UVB despite our concerns about some risks inherent to KID syndrome.

## References

1. Gonzalez ME, Tlougan BE, Price HN, Patel R, Kamino H, Schaffer JV. Keratitis-Ichthyosis-Deafness (KID) Syndrome. *Dermatol Online J*. 2009 Aug 15;15(8):11. [PMID: 19891919]
2. Lazic T, Li Q, Frank M, Uitto J, Zhou LH. Extending the Phenotypic Spectrum of Keratitis-Ichthyosis-Deafness Syndrome: Report of a Patient with GJB2 (G12R) Connexin 26 mutation and unusual clinical findings. *Pediatr Dermatol*. 2012 May-Jun;29(3):349-57. [PMID: 22011219]
3. Alli N, Gungor E. Keratitis, ichthyosis and deafness (KID) syndrome. *Int J Dermatol*. 1997 Jan;36(1):37-40. [PMID: 9071613]
4. Miteva L. Keratitis, Ichthyosis and Deafness (KID) Syndrome. *Pediatr Dermatol*. 2002 Nov-Dec;19(6):513-6. [PMID: 12437553]
5. Lenane P, Cammisuli S, Chitayat D, Krafchik B. What syndrome is this? KID syndrome (keratitis, ichthyosis, deafness). *Pediatr Dermatol*. 2006 Jan-Feb;23(1):81-3. [PMID: 16445421]
6. Coggshall K, Farsani T, Ruben B, McCalmont TH, Berger TH, Fox LP, Shinkai K. Keratitis, ichthyosis, and deafness (KID) syndrome: A review of infectious and neoplastic complications. *J Am Acad Dermatol*. 2013 Jul;69(1):127-34. [PMID: 23384797]
7. Karadag-Saygi E, Ustun I, Erol B, Yucelten D. KID syndrome patient with toe walking: a case report. *Dev Neurorehabil*. 2009 Jun;12(3):175-8. [PMID: 19466627]
8. Patel V, Sun G, Dickman M, Khuu P, Teng JM. Treatment of keratitis-ichthyosis-deafness (KID) syndrome in children: a case report and review of the literature. *Dermatol Ther*. 2015 Mar-Apr;28(2):89-93. [PMID: 25546246]
9. Wood GS, Reizner GT. Other papulosquamous disorders. In: Bologna JL, Jorizzo JL, Schaffer JV, editors. *Dermatology*. 3rd ed. China: Elsevier; 2012. p. 157-69.
10. Brazzelli V, Carugno A, Rivetti N, Cananzi R, Barruscotti S, Borroni G. Narrowband UVB phototherapy for pediatric generalized pityriasis lichenoides. *Photodermatol Photoimmunol Photomed*. 2013 Dec;29(6):330-3. [PMID: 24112386]
11. Ersoy-Evans S, Altaykan A, Sahin S, Kolemen F. Phototherapy in childhood. *Pediatr Dermatol*. 2008 Nov-Dec;25(6):599-605. [PMID: 19067863]
12. Hearn RMR, Kerr AC, Rahim KF, Ferguson J, Dawe RS. Incidence of skin cancers in 3687 patients treated with narrow-band ultraviolet B phototherapy. *Br J Dermatol*. 2008 Sep;159(4):931-5. [PMID: 18834483]
13. Archier E, Devaux S, Castela E, Gallini A, Aubin F, Le Maitre M, Aractingi S, Bachelez H, Cribier B, Joly P, Jullien D, Misery L, Paul C, Ortonne JP, Richard MA. Carcinogenic risks of Psoralen UV-A therapy and Narrowband UV-B therapy in chronic plaque psoriasis: a systematic literature review. *J Eur Acad Dermatol Venereol*. 2012 May;26 Suppl 3:22-31. [PMID: 22512677]
14. Kaminska ECN, Ortel B, Sharma V, Stein SL. Narrowband UVB phototherapy as a novel treatment for Netherton syndrome. *Photodermatol Photoimmunol Photomed*. 2012 Jun;28(3):162-4. [PMID: 22548400]
15. Maatouk I, Moutran R, Tomb R. Narrowband ultraviolet B phototherapy associated with improvement in Netherton syndrome. *Clin Exp Dermatol*. 2012 Jun;37(4):364-6. [PMID: 22581910]
16. Capezzer R, Venturini M, Bianchi D, Zane C, Calzavara-Pinton P. UVA1 phototherapy of Netherton syndrome. *Acta Derm Venereol*. 2004;84(1):69-70. [PMID: 15040483]
17. Natsuga K, Akiyama M, Shimizu H. Malignant skin tumours in patients with inherited ichthyosis. *Br J Dermatol*. 2011 Aug;165(2):263-8. [PMID: 21517795]