

# UC Davis

## Dermatology Online Journal

### Title

A pink enlarging plaque on the plantar foot: amelanotic acral lentiginous melanoma

### Permalink

<https://escholarship.org/uc/item/3p91j5db>

### Journal

Dermatology Online Journal, 25(1)

### Authors

Okhovat, Jean-Phillip  
Tahan, Steven R  
Kim, Caroline C

### Publication Date

2019

### DOI

10.5070/D3251042617

### Copyright Information

Copyright 2019 by the author(s). This work is made available under the terms of a Creative Commons Attribution-NonCommercial-NoDerivatives License, available at <https://creativecommons.org/licenses/by-nc-nd/4.0/>

Peer reviewed

# A pink enlarging plaque on the plantar foot: amelanotic acral lentiginous melanoma

Jean-Phillip Okhovat<sup>1</sup> MD MPH, Steven R Tahan<sup>2</sup> MD, Caroline C Kim<sup>3</sup> MD

Affiliations: <sup>1</sup>Department of Dermatology, Stanford University Medical Center, Stanford University School of Medicine, Palo Alto, California, USA, <sup>2</sup>Department of Pathology, Harvard Medical School, Beth Israel Deaconess Medical Center, Boston, Massachusetts, USA, <sup>3</sup>Department of Dermatology, Harvard Medical School, Beth Israel Deaconess Medical Center, Boston, Massachusetts, USA

Corresponding Author: Caroline C. Kim MD, Director, Pigmented Lesion Clinic, Department of Dermatology, Harvard Medical School, Beth Israel Deaconess Medical Center, 330 Brookline Avenue, Shapiro 2, Boston, MA 02215, Email: [ckim3@bidmc.harvard.edu](mailto:ckim3@bidmc.harvard.edu)

**Abstract** Acral lentiginous melanomas account for less than 5% of all melanomas, whereas amelanotic melanomas account for around 2-8% of all melanomas. Amelanotic acral lentiginous melanomas are even less common and can often be mistaken for other clinical entities, including pyogenic granulomas, non-melanoma skin cancers, and warts. We describe a man in his 50s with a twenty-year history of a skin-colored plaque on the right plantar foot; after enlargement and failure of wart treatment, a shave biopsy revealed an amelanotic melanoma. A subsequent wide local excision and sentinel lymph node biopsy revealed melanoma in 4 lymph nodes and the patient underwent an abbreviated course of interferon-alpha therapy. The patient remained stable until 2 ½ years after diagnosis, at which time he presented with in-transit metastases on the foot and right thigh; he has since been stable on nivolumab. This case represents the challenge of diagnosing amelanotic melanomas on acral surfaces and highlights the importance of considering a skin biopsy for diagnosis of any changing, atypical amelanotic lesions on the feet or hands.

*Keywords: amelanotic, melanoma, acral lentiginous melanoma*

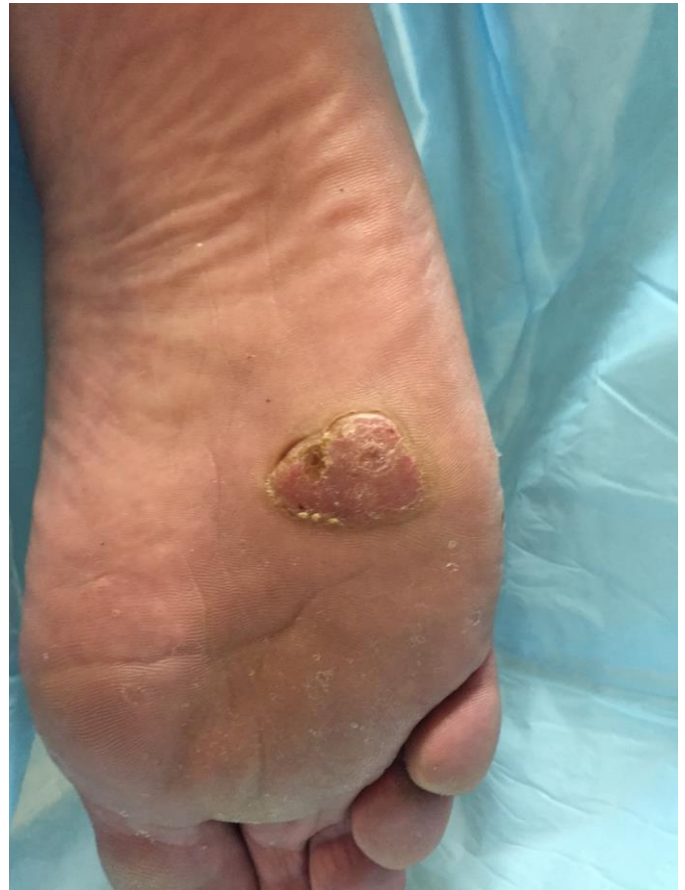## Introduction

Amelanotic acral lentiginous melanomas (ALM) account for a very small percentage of all melanomas and can be difficult to diagnose. We describe a man in his fifties with a twenty-year history of a skin-

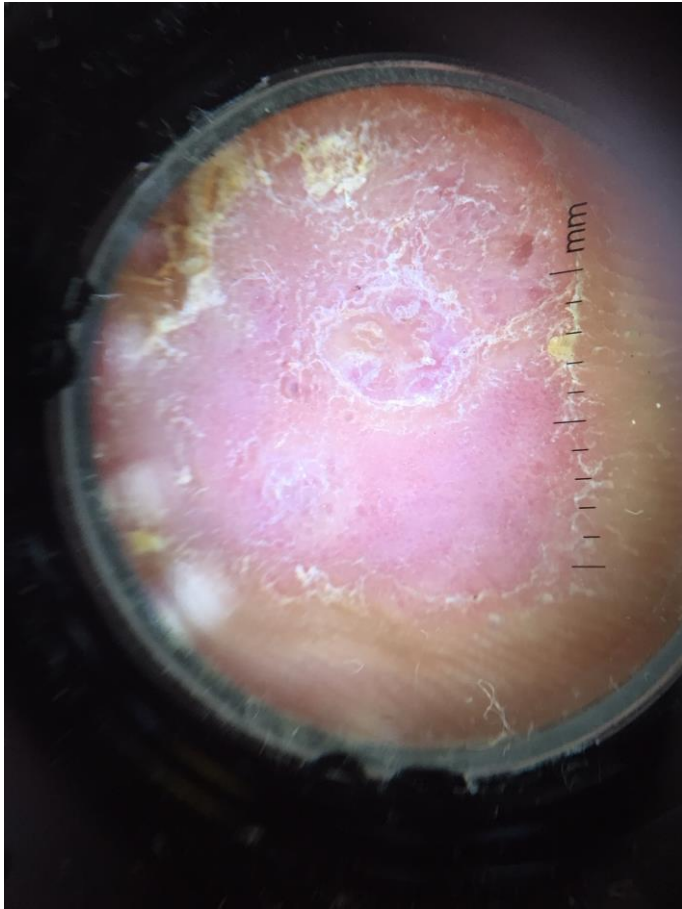
colored plaque on his foot that had enlarged and failed wart treatment prior to a biopsy diagnosis of amelanotic melanoma.

## Case Synopsis

A 50-year-old man reported the onset of a small skin-

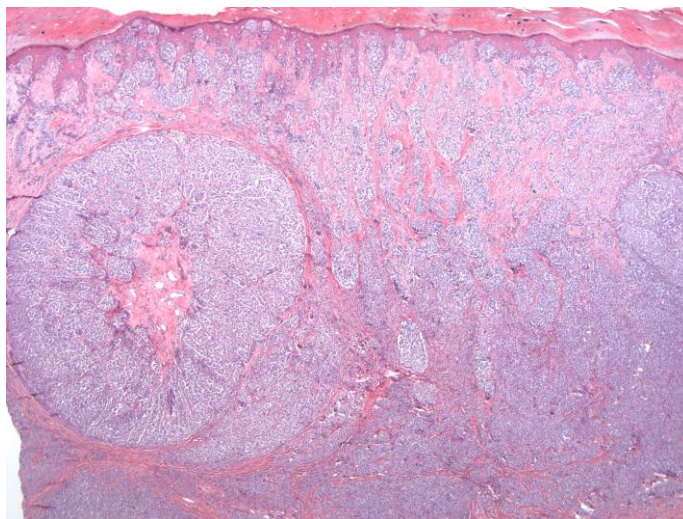


**Figure 1:** Photograph of a 2.8×1.9cm hyperkeratotic, flat-topped, light pink firm plaque within a collarette of hyperkeratotic scale on the right plantar foot.



**Figure 2:** 10× dermoscopic photograph of patient's lesion with no abnormal vasculature or pigment appreciated.

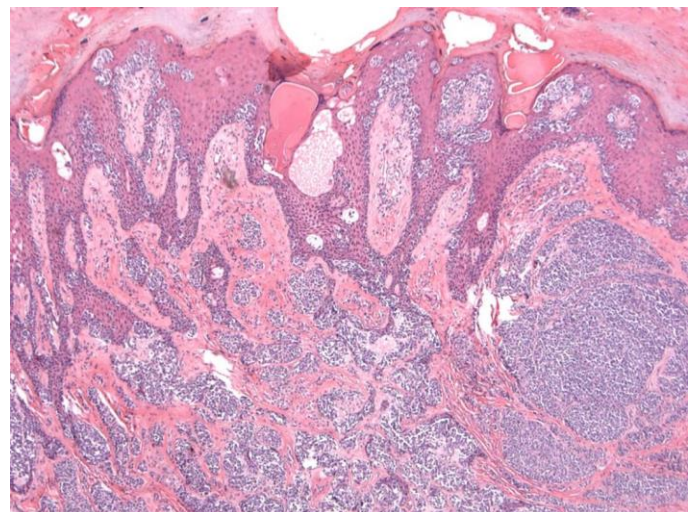
colored, plaque on the right plantar foot, which initially had remained asymptomatic and unchanged for years. He had believed that this was a callus. Five years prior to presentation, the lesion started to grow



**Figure 3:** Low power photomicrograph showing deeply invasive vertical growth phase melanoma arising in acral skin, H&E, 20×.

and turned light pink in color. It was treated as a wart with liquid nitrogen and silver nitrate by a podiatrist while he was living in Europe, and the lesion continued to grow into a larger protruding growth. The patient denied any prior trauma to the site, bleeding, pain, or pruritus of the lesion. He was otherwise in good health. He moved to the United States and was seen by another podiatrist, who performed an initial biopsy of the lesion and referred him to our dermatology department. There was no personal or family history of any skin cancers or prior skin biopsies. Physical examination revealed a well-appearing man with skin type I, red hair, and greater than 50 scattered slightly atypical nevi. On the right plantar surface there was a 2.8×1.9cm light pink firm plaque that was hyperkeratotic with a flat surface and a surrounding collarette of hyperkeratotic scale (**Figure 1**). There was a small shallow ulcer corresponding to the recent shave biopsy. No visible vascular pattern or pigment was appreciated on dermoscopic examination (**Figure 2**).

Histopathologic examination of the initial shave biopsy and subsequent wide excision with sentinel node biopsy revealed an amelanotic acral lentiginous melanoma with Breslow depth 8.3mm, Clark level V, 5 mitoses per square mm, and no ulceration (**Figures 3-4**). Of 3 sentinel lymph nodes excised, one was positive for melanoma. Completion lymphadenectomy revealed melanoma in an



**Figure 4:** Densely cellular proliferation of epithelioid melanocytes along the junctional epidermis with associated elongated "pointy" rete ridges, H&E, 40×.

additional three lymph nodes, rendering the patient to have T4aN3, stage IIIC disease. The patient underwent four months of adjuvant interferon-alpha therapy but stopped owing to the development of a new right knee nodule that was initially concerning for metastatic melanoma. However, subsequent PET imaging was negative for disease and the lesion regressed. He decided not to restart interferon therapy owing to fatigue and had been followed uneventfully for the next 2½ years, at which time he presented with three in-transit metastases on the foot and right thigh. After surgical excision of his in-transit disease, he was started on nivolumab adjuvant treatment every four weeks.

## Case Discussion

Acral lentiginous melanomas (ALM) account for less than 5% of all melanomas, with an incidence in the United States reported as 1.8 per 1,000,000 person-years [1]. The average age at diagnosis of ALM is 62.8 years, and the majority of cases (78%) present on the lower limb [1]. Amelanotic melanomas account for approximately 2-8% of all melanomas and may present clinically as pink or red macules, plaques, or nodules, which can often be mistaken for other clinical entities such as pyogenic granulomas, non-melanoma skin cancers, and warts [2].

Amelanotic ALM can be challenging to diagnose and this case exemplifies a lesion that failed traditional therapies for warts and was, eventually correctly diagnosed with a skin biopsy. Population-based studies have shown that ALMs have similar incidence in all skin types, although ALM accounts for a larger percentage of melanomas occurring in darker-skinned patients, accounting for up to 36% of cutaneous melanomas in blacks [1]. Clinicians should remain alert for amelanotic ALM in all patients and consider a biopsy for any unusual or growing amelanotic lesions.

Although certain dermoscopy patterns have been described for amelanotic melanomas, such as linear irregular vessels and milky-red areas, this case is also an example of a melanoma without clearly abnormal dermoscopic patterns, emphasizing the importance of a biopsy for diagnosis. Risk factors for ALM are

unknown and are thought to be unrelated to sun exposure. However, trauma has been suggested as a pathogenic factor, possibly related to the presence of ALM on weight-bearing areas [3].

ALMs are believed to have a distinct pathway for genesis compared to other subtypes of melanoma, with specific mutations in *KIT*, *NRAS*, and *BRAF* [4]. Early detection of ALM is important as ALM has been reported to have lower 5- and 10-year melanoma-specific survival rates of 80.3% and 67.5%, respectively, compared to all cutaneous melanomas (91.3% and 87.5%, respectively;  $P < 0.001$ ), [1].

The differential diagnosis for an amelanotic ALM is broad, and may include wart, verrucous carcinoma (VC), and eccrine porocarcinoma. Although a wart would be expected to respond to traditional therapy, VC, an uncommon variant of squamous cell carcinoma, would continue to grow as an exophytic, warty tumor, requiring a biopsy for diagnosis. VC are usually slow growing and localized prognosis is typically favorable owing to lack of distant metastases [5]. Eccrine porocarcinomas may present as red plaques or nodules most often on the lower legs or feet, although not as commonly on the soles. These also require a biopsy for diagnosis. Studies have shown the incidence of eccrine porocarcinomas to be as low as 0.005%-0.01% and they are typically found in elderly patients between 50-80 years of age [6].

## Conclusion

Amelanotic ALM can be clinically challenging to diagnose owing to their presentation mimicking other entities. ALMs represent less than 5% of all melanomas, with an average age of onset of 62.8 years; approximately 78% present on the lower limb. The 5- and 10-year melanoma-specific survival rates of ALM is lower compared to all cutaneous melanomas. Although the risk factors for ALM are not completely understood, mutations in *KIT*, *NRAS*, and *BRAF* are believed to be implicated and trauma may be a pathogenic factor. Although certain dermoscopy features have been reported for amelanotic melanoma, such as linear irregular vessels and/or milky-red areas, it is important for

clinicians to be cognizant of this diagnosis even without suspicious dermoscopy patterns. Mimics of amelanotic AML may include wart, verrucous carcinoma, and eccrine porocarcinoma.

Dermatologists should consider prompt biopsy for any irregular or growing amelanotic lesions on the hands or feet.

## References

1. Bradford PT, Goldstein AM, McMaster ML, Tucker MA. Acral lentiginous melanoma: incidence and survival patterns in the United States, 1986-2005. *Arch Dermatol.* 2009 Apr;145(4):427-34. [PMID: 19380664].
2. Pizzichetta MA, Talamini R, Stanganelli I, et al. Amelanotic/hypomelanotic melanoma: clinical and dermoscopic features. *Br J Dermatol.* 2004; 150:1117. [PMID: 15214897].
3. Phan A, Touzet S, Dalle S, Ronger-Savlé S, Balme B, Thomas L. Acral lentiginous melanoma: a clinicoprognostic study of 126 cases. *Br J Dermatol.* 2006 Sep;155(3):561-9. [PMID: 16911282].
4. Zebary A, Omholt K, Vassilaki I, Höiom V, Lindén D, Viberg L, Kanter-Lewensohn L, Johansson CH, Hansson J. KIT, NRAS, BRAF and PTEN mutations in a sample of Swedish patients with acral lentiginous melanoma. *J Dermatol Sci.* 2013 Dec;72(3):284-9. [PMID: 23993026].
5. Schwartz RA. Verrucous carcinoma of the skin and mucosa. *J Am Acad Dermatol.* 1995 Jan;32(1):1-21. [PMID: 7822496].
6. Lloyd MS, El-Muttardi N, Robson A. Eccrine porocarcinoma: A case report and review of the literature. *Can J Plast Surg.* 2003;11(3):153-156. [PMID: 24115860].