

# UC Davis

## Dermatology Online Journal

### Title

Successful treatment of pityriasis rubra pilaris with adalimumab - case report

### Permalink

<https://escholarship.org/uc/item/3nb8c3kb>

### Journal

Dermatology Online Journal, 20(4)

### Authors

Bravo, Erick A  
Carrion, Leonidas  
Paucar, Silvia M  
[et al.](#)

### Publication Date

2014

### DOI

10.5070/D3204022374

### Copyright Information

Copyright 2014 by the author(s). This work is made available under the terms of a Creative Commons Attribution-NonCommercial-NoDerivatives License, available at <https://creativecommons.org/licenses/by-nc-nd/4.0/>

Peer reviewed

## Case Presentation

### Successful treatment of pityriasis rubra pilaris with adalimumab - case report

Erick A. Bravo MD<sup>1,2</sup> Leonidas Carrion MD<sup>2</sup>, Silvia M. Paucar MD<sup>2</sup>, Rossana Mendoza MD<sup>2</sup>, Carlos Rivera MD<sup>2</sup>

Dermatology Online Journal 20 (4): 11

<sup>1</sup>Institute of Clinical Research – Universidad Nacional Mayor de San Marcos, Lima - Peru

<sup>2</sup>Department of Dermatology, Hospital Nacional “Luis N. Saenz”, Lima – Peru

#### Correspondence:

Erick A. Bravo  
erick.bravo@upch.pe

## Abstract

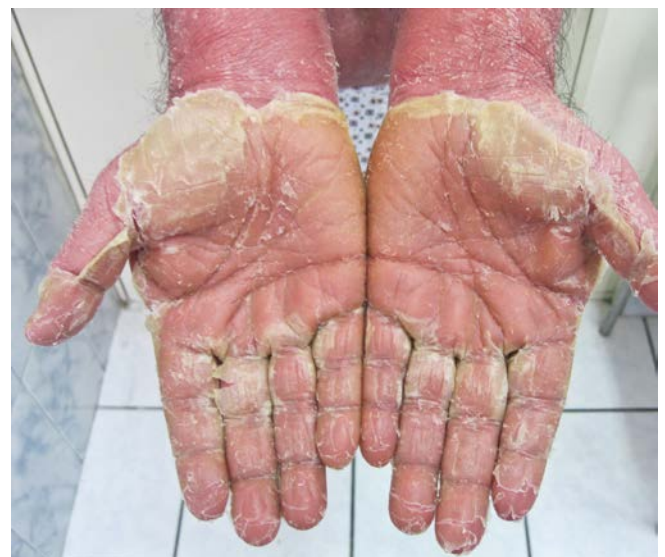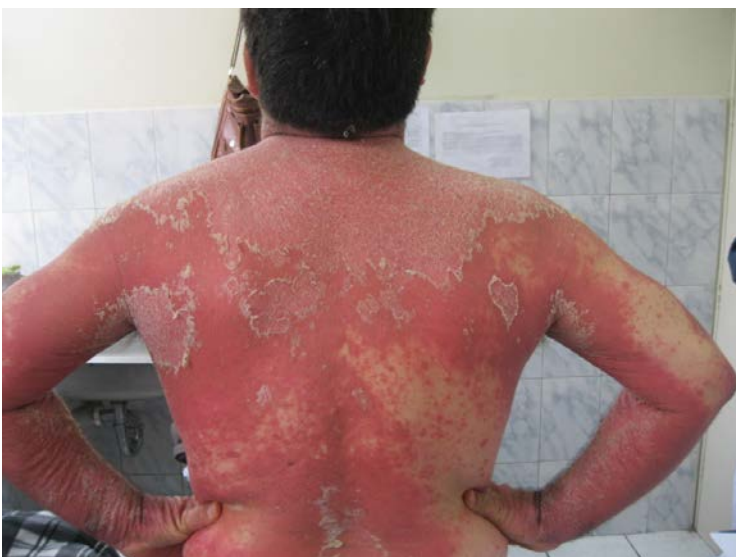Pityriasis Rubra Pilaris (PRP) is an uncommon skin disorder characterized by follicular keratosis, palmoplantar keratoderma, and erythroderma. The traditional preferred treatment is oral retinoids, but over the last decade, biologic therapy with anti-TNF agents has been used with success. We report the case of a 51 year- old man with a clinical and histopathological diagnosis of PRP. He underwent therapy with adalimumab and showed clearance of skin lesions within the fourth week of treatment.

**Key words:** Pityriasis Rubra Pilaris, Adalimumab

## Introduction

Pityriasis Rubra Pilaris (PRP) is a chronic disorder of keratinization characterized by follicular keratosis, palmoplantar keratoderma, and erythroderma. Griffiths classified PRP into 5 clinical subtypes, but later added a category associated with HIV infection [1]. It is of unknown etiology, presenting in 2.5 individuals per million; peaks of prevalence have been noted in childhood and adulthood [2].

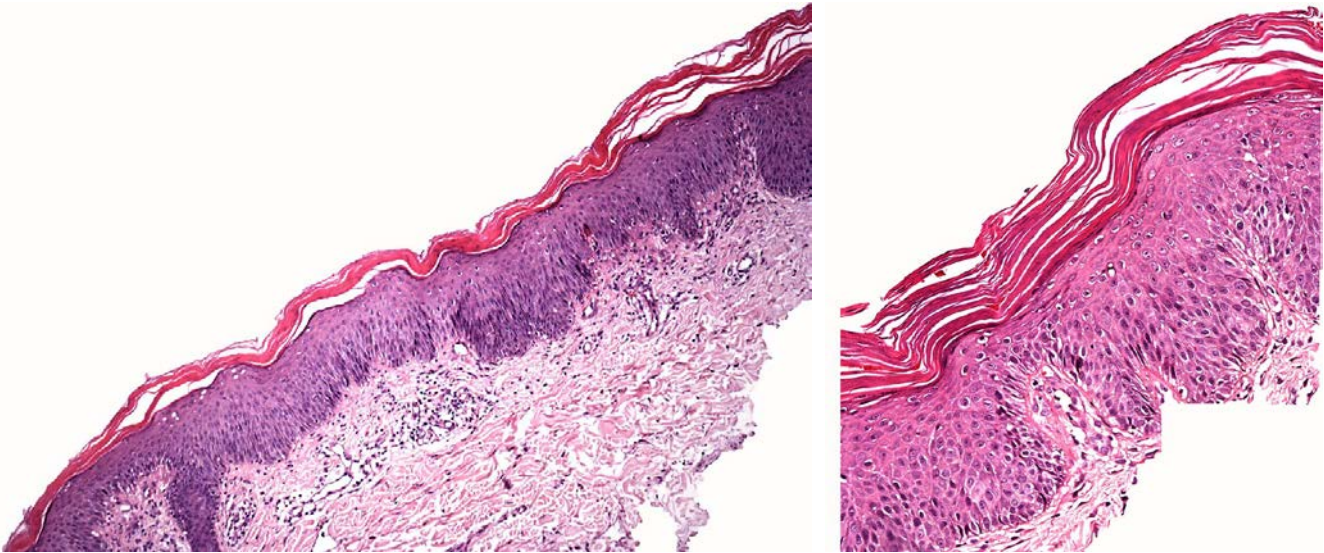
Presently, there is no uniformly agreed upon treatment for PRP. Oral retinoids are preferred to other treatments such as methotrexate, cyclosporine, UVB narrow band therapy, and topical calcipotriol [2,3]. Anti-TNF biologic therapy has been used in small numbers of patients for PRP over the last decade with success. To our knowledge, 7 cases of PRP treated with adalimumab are reported in the literature [1,4,5,6].



## Case Report

A 51-year-old man, with a past medical history of gout and benign prostatic hypertrophy, presented with a disease onset of 15 days characterized by facial and cervical redness and pruritus. The erythema and scale progressed to his chest and then to his lower extremities. He was initially treated with oral corticosteroids and antihistamines without any improvement. He was hospitalized with stable vital signs.

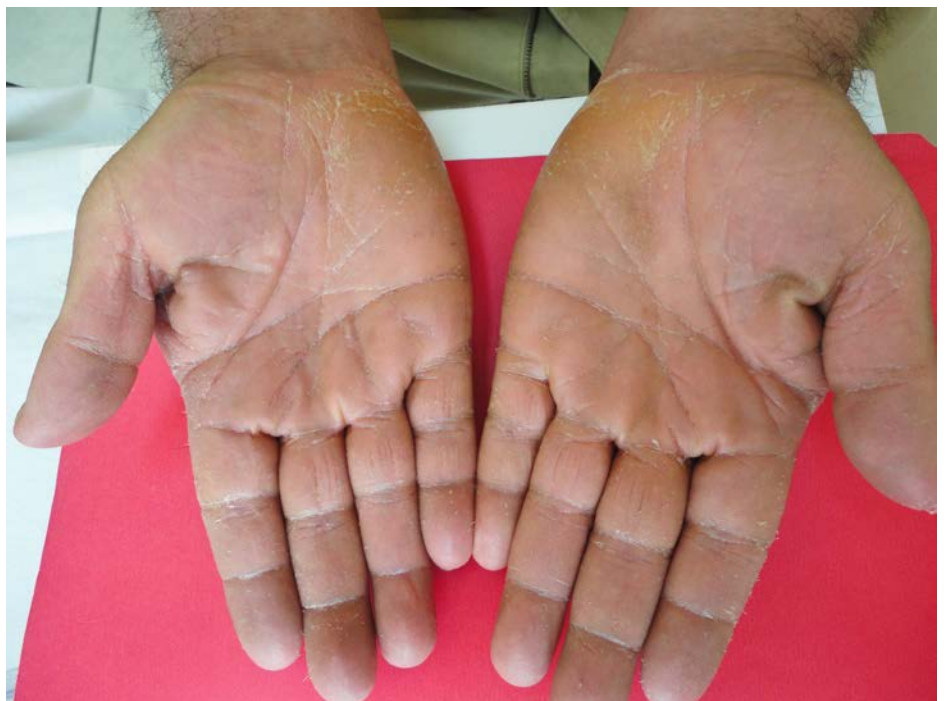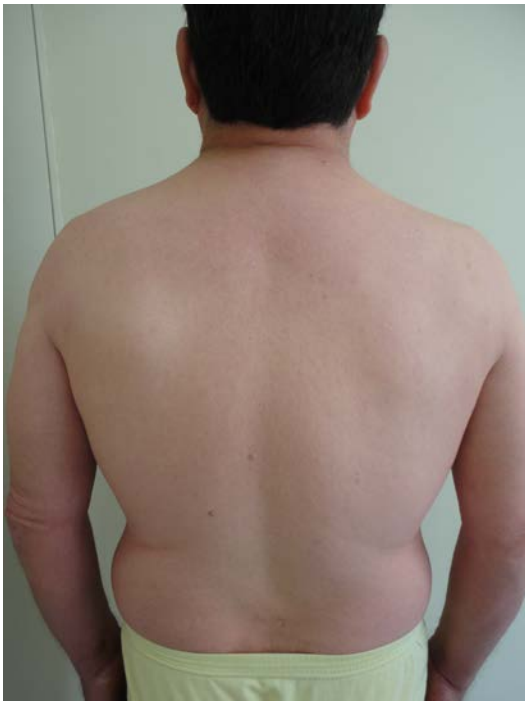The physical exam showed exfoliative erythroderma with scalp involvement, isolated areas of unaffected skin, and scaly palmoplantar keratoderma (Figure 1,2). Histopathology was consistent with PRP and showed irregular acanthosis with alternating ortho and parakeratosis, broad rete ridges, and perivascular lymphocytic infiltrate (Figure 2<sup>AB</sup>). Laboratory tests showed no alteration.



Figures 3 and 4.. Histopathology shows irregular acanthosis with alternating ortho and parakeratosis, broad rete ridges, and perivascular lymphocytic infiltrate.

The patient started acitetrin 50mg per day, urea-based moisturizers, and liquid petrolatum regularly for three months, with minimal improvement. During this period there was a suicide attempt and an increase in liver enzymes prompting us to switch to adalimumab, with an initial subcutaneous (SC) dose of 80mg, followed by 40mg every other week.

One week after the first dose, the patient showed a decrease of pruritus and on the fourth week had clearance of his erythroderma and marked improvement of his palmar-plantar keratoderma. The patient has been followed up for 7 months using adalimumab every other week as monotherapy without recurrence.



## Discussion

PRP is a rare papulosquamous disorder with variable response to treatment. Most of the patients have complete remission in 3 to 5 years [1,7]. Currently, a standard therapeutic protocol does not exist. In retrospective studies oral acitretin or oral isotretinoin used as monotherapy have showed partial to marked clinical response in 3 to 6 months [1,3,8]. Metotrexate used alone or in combination with oral retinoids has the same clinical outcome, but also more side effects, such as hepatotoxicity and myelosuppression [3,4]. Phototherapy (UVB, Uva-1, PUVA) was also used with less effectiveness. In addition, topical analogs of Vitamin D, oral and topical corticosteroids, and oral immunosuppressive drugs such as cyclosporin or azathioprine have been used with partial response [2,3,8].

Over the last decade, anti-TNF biological treatment with or without the use of combination therapy has been used for PRP and has shown notable and rapid clinical response [5-8]. Infliximab was initially used because of its safety profile, followed by Etanercept. Since 2009, adalimumab [4,7] has been added to this list. A systematic review of biological treatment in PRP has shown rapid resolution of redness and scale varying from 3 to 8 weeks in the case of monotherapy with adalimumab [1].

This class of medications has shown significant overall benefits for patients with PRP, but prospective studies will be necessary.

## References

1. Petrof G, Almaani N, Archer C, Griffiths W, Smith C. A systematic review of the literature on the treatment of pityriasis rubra pilaris type 1 with TNF-antagonists. *JEADV* 2013; 27: 131 – 5 [PMID: 22324561]
2. Sehgal VN, Srivastava G, Verma P. Pityriasis rubra pilaris: evolution of challenges in promising treatment options. *Skinmed* 2012; 10 (1):18-23. [PMID: 22324172]
3. Klein A, Landthaler M, Karrer S. Pityriasis rubra pilaris: a review of diagnosis and treatment. *Am J Clin Dermatol.* 2010; 11 (3):157- 70. [PMID: 20184391]
4. Walling HW, Swick BL. Pityriasis rubra pilaris responding rapidly to adalimumab. *Arch Dermatol* 2009; 145 (1):99-101 [PMID: 19153364]
5. Schreml S, Zeller V, Babilas P, Karrer S, Landthaler M. Pityriasis rubra pilaris successfully treated with Adalimumab. *Clinical and Experimental Dermatology* 2010; 35(1) 789–796 [PMID: 20345992]
6. Chiu HY, Tsai TF. Pityriasis rubra pilaris with polyarthritis treated with Adalimumab. *J Am Acad Dermatol.* 2013; 68(1):187-8 [PMID: 23244382]
7. Ivanova K, Itin P, Haeusermann P. Pityriasis rubra pilaris: treatment with biologics - a new promising therapy? *Dermatology.* 2012; 224(2):120-5 [PMID: 22508269]
8. Eastham AB, Femia AN, Qureshi A, Vleugels RA. Treatment options for pityriasis rubra pilaris including biologic agents: a retrospective analysis from an academic medical center. *JAMA Dermatol.* 2014 Jan 1;150(1):92-4 [PMID:23986433]