

UC Davis

Dermatology Online Journal

Title

Disseminated varicella-zoster virus in an immunocompetent adult

Permalink

<https://escholarship.org/uc/item/3cz2x99b>

Journal

Dermatology Online Journal, 21(3)

Authors

Petrún, Branden
Williams, Victoria
Brice, Sylvia

Publication Date

2015

DOI

10.5070/D3213022343

Copyright Information

Copyright 2015 by the author(s). This work is made available under the terms of a Creative Commons Attribution-NonCommercial-NoDerivatives License, available at <https://creativecommons.org/licenses/by-nc-nd/4.0/>

Peer reviewed

Case presentation

Disseminated varicella-zoster virus in an immunocompetent adult

Branden Petrun, BA¹, Victoria Williams, MD², Sylvia Brice, MD²

Dermatology Online Journal 21 (3): 10

¹University of Colorado School of Medicine

²University of Colorado Department of Dermatology

Correspondence:

Branden Petrun
1665 Aurora Court
Mail Stop F703
Aurora, CO 80045-0510

Abstract

Varicella-zoster is the virus that causes varicella (chicken pox), herpes zoster (shingles), and, rarely, severe disseminated disease including diffuse rash, encephalitis, hepatitis, and pneumonitis. Disseminated disease is most often seen in immunocompromised patients. We describe an immunocompetent patient with disseminated zoster who had previously been immune to VZV. This case is also unusual in that his clinical presentation was most consistent with varicella whereas his laboratory data was most consistent with herpes zoster. For the purpose of rapid diagnosis and initiation of appropriate therapy, clinicians should be aware of these more atypical presentations of VZV infection.

Keywords: Varicella-zoster virus, zoster, varicella, shingles, immunocompromise

Abbreviations: VZV—Varicella-Zoster virus; PCR—polymerase chain reaction

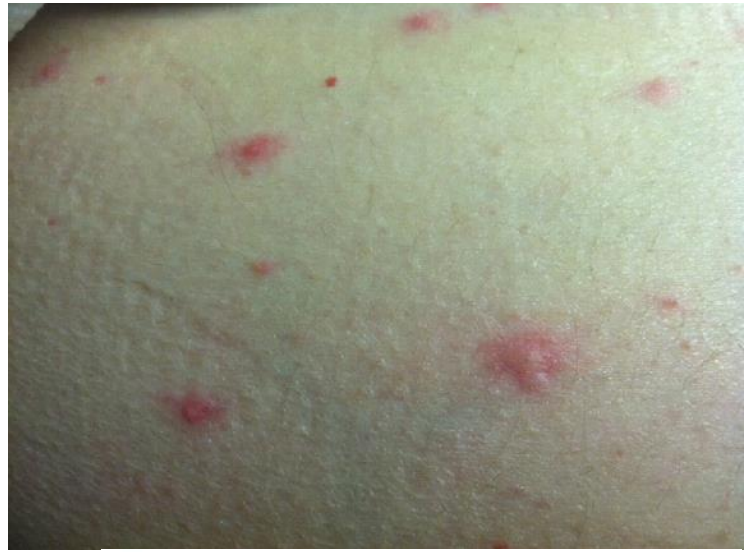Introduction

Varicella-zoster virus is a human alpha herpesvirus known to cause varicella (chicken pox) on primary infection and zoster (shingles) upon reactivation. Varicella most commonly strikes children, typically causing a self-limited pruritic, vesicular eruption. Herpes zoster characteristically presents with a prodrome of burning pain followed by an outbreak of vesicles distributed unilaterally within a single dermatome [1, 2, 3]. Varicella-zoster virus may also cause disseminated disease, including pneumonitis, hepatitis, and encephalitis, with either primary infection or with reactivation. Dissemination occurs more commonly in primary infection and almost exclusively in immunocompromised patients [1].

In herpes zoster, a few lesions (typically less than 20) can normally appear adjacent to the affected dermatome. More extensive skin involvement of several adjacent dermatomes is called multi-dermatomal zoster, whereas spread to a non-adjacent dermatome is known as zoster duplex unilateralis or bilateralis [1, 3, 4, 5, 6]. We present the rare case of an immunocompetent patient who developed what clinically appeared to be varicella, with widely disseminated skin lesions in a non-dermatomal distribution, but more likely represented reactivation of VZV infection.

Case synopsis

A 74-year-old man presented to the emergency department with a four-day history of fever, severe headache, and fatigue. His past medical history was significant for congestive heart failure, chronic obstructive pulmonary disease, and chronic renal disease. He had a temperature of 38.9 °C and mild hypoxia. Erythematous papules were uniformly scattered across the face and scalp. Complete blood count and chemistry panel were unremarkable. Chest radiograph showed emphysema in the lung bases but no acute changes. A lumbar puncture showed mixed acute and chronic inflammation thought to be consistent with an infectious or inflammatory process. He received one dose each of IV vancomycin, ceftriaxone, and ampicillin, was started on IV acyclovir 10 mg/kg IV, and admitted to the neurology service for presumed meningitis.



Over the next day his skin lesions progressed to scattered vesicles on an erythematous base distributed across his trunk and extremities (Figure 1). The skin eruption was associated with mild pain and pruritus. Skin biopsy of a representative lesion showed epidermal ulceration with necrosis, multinucleated cells, and acute and chronic inflammation consistent with VZV versus HSV (Figures 2A,B). Immunohistochemistry was positive for VZV (Figure 2C).

Figure 1. Vesicles on an erythematous base scattered across the trunk **Figure 2.** A) Ulceration centered on a hair follicle (40x magnification, H&E). B) Hair follicle epithelial cells with viral cytopathologic changes, including multinucleation and chromatin margination (400x magnification, H&E). C) Immunohistochemical study for VZV labels follicular epithelial cells (400x magnification).

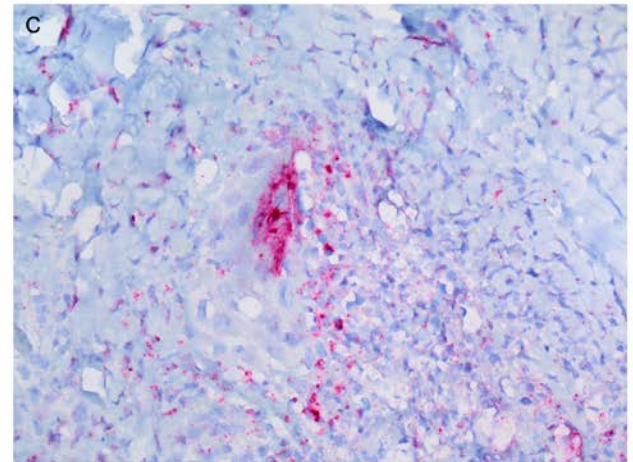
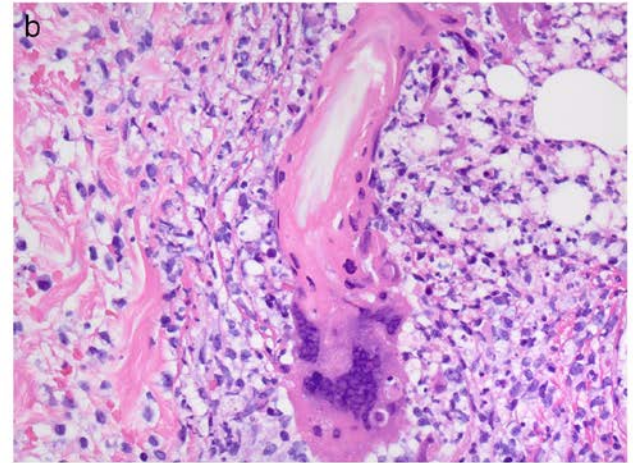
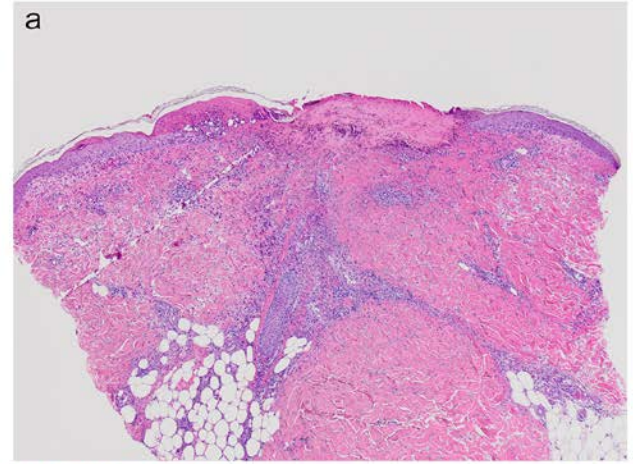
Viral culture of a vesicle and viral PCR of the blood was positive for VZV. Serology of the blood demonstrated elevated IgG but normal IgM, consistent with a reactivation of the varicella virus. The VZV serology of the CSF was negative.

The patient's skin eruption was treated symptomatically with calamine lotion and oral diphenhydramine. Over the course of five days the patient's condition improved and he was discharged with instructions to continue a 14-day course of IV acyclovir followed by four weeks of oral acyclovir.

Discussion

Primary VZV infection is generally transmitted by infectious respiratory secretions. Viral replication in lymphatic tissue and a primary viremia is then followed by a second viral replication within the liver and spleen. A secondary viremia allows access to the epidermis, whereupon the classic clinical presentation of varicella manifests: vesicles on an erythematous base. As the cutaneous infection subsides, usually over 1-2 weeks, the virus enters into quiescence within sensory neurons.

The virus is kept in this state of quiescence by a competent cell-mediated immune system. Any condition that causes immunity to fade may allow the virus to reactivate, travel down axons, and manifest as the cutaneous infection known as herpes zoster. The relative decline in immune function that occurs with age is the main risk factor for cutaneous



reactivation of VZV in the form of zoster.

For the virus to reactivate and spread outside of a single dermatome diffusely across the skin and into vital organs, most patients need a significant defect in immunity. Our patient, however, experienced generalized dissemination to the skin and possibly the central nervous system, without an apparent underlying state of immune compromise. We believe that this patient provides important evidence that the relative immune compromise of old age may be enough to allow dissemination. We are aware of fewer than 10 reported cases of disseminated zoster in immunocompetent patients, most of whom were over the age of 65 (Table 1) [7, 8, 9, 10, 11, 12, 13].

Table 1. Reported cases of disseminated zoster in immunocompetent hosts

| Age | Sex | Lesion distribution | Extracutaneous involvement | Diagnosed by | Treatment | Outcome |
|-----------|--------|--|----------------------------|--|---|---|
| 37 y [7] | Male | Left T2, then generalized | Aseptic meningitis | VZV serology, VZV Southern blot of CSF | Acyclovir 10 mg/kg, IV, q.8.h. for 7 days | Complete recovery |
| 39 y [8] | Male | Right T6, then generalized | None | VZV PCR | Acyclovir 10 mg/kg, IV t.i.d. for 7 days | Complete recovery |
| 67 y [9] | Female | Right lower extremity, trunk, and buttocks | None | Viral culture from lesion | Acyclovir 800 mg, p.o., 5 times daily for 7 days | Recovery complicated by transient motor neuropathy of right leg |
| 69 y [10] | Male | Right CN-V ₁ , then generalized | None | VZV DFA from lesion | Acyclovir 800 mg, IV, q.8.h. for 6 days, then acyclovir 800 mg, p.o., 5 times daily for 16 days | Complete recovery |
| 70 y [9] | Female | Generalized, worst at left CN-V ₂ | None | Viral culture from lesion | Acyclovir 800 mg, p.o., 5 times daily for 7 days | Complete recovery |
| 75 y [11] | Male | Left C2, then generalized | Ramsay-Hunt | Clinical | Acyclovir 1500 mg, IV, daily for 7 days | Complete recovery |
| 79 y [9] | Male | Generalized, worst at left L3 | None | Electron microscopy from skin biopsy | Acyclovir 800 mg, p.o., 5 times daily for 7 days | Complete recovery |
| 82 y [12] | Male | Dermatomal | Esophagitis | Cytology from esophagus | Acyclovir 250 mg, IV, q.8.h. for 10 days | Complete recovery |

| | | | | | | |
|--------------|--------|---|------|---------|-----------------------------------|----------------------|
| 97 y [13] | Female | Left CN-V ₃ , then generalized | None | VZV PCR | Valacyclovir, p.o., for 7 days | Complete recovery |
|--------------|--------|---|------|---------|-----------------------------------|----------------------|

Varicella zoster is most often diagnosed clinically by the classic appearance of a vesicular dermatomal eruption, although diagnostic confirmation via virologic, serologic, and histologic techniques can be used. Serology allows the added benefit of identification of a primary infection versus reactivation, as was identified in our patient. High IgM titers against VZV are associated with primary infection. IgG titers increase after primary infection and decrease steadily throughout the individual's life. These will increase again with reactivation [1]. Our patient's clinical presentation was most consistent with varicella, with no dermatomal distribution and diffuse crops of vesicles of varying ages. However, his laboratory studies suggest recurrent VZV. A visceral nerve branch could have been the initial site of occult reactivation followed by dissemination, or multiple dermatomes may have reactivated at once. Hematogenous spread would explain the diffuse nature of his disease, but it is unclear why reactivated VZV spread in this way in this patient.

Conclusion

Clinicians may already suspect severe VZV disease in patients with a clear history of immunocompromise. However, they should be aware that even immunocompetent patients, including those who have a history of immunity to VZV, can develop disseminated disease. In these cases, the classically painful dermatomal rash may not be present, but characteristic vesicular lesions may still be used to aid in the correct diagnosis and appropriate therapy.

References

1. Arvin AM. Varicella-zoster virus. *Clin Microbiol Rev.* 1996 Jul;9(3):361-81. [PMID:8809466]
2. Philip A, Thakur R. Post herpetic neuralgia. *J Palliat Med.* 2011 Apr;14(6):765-73. [PMID:21651364]
3. Gnann JW, Whitley RJ. Herpes zoster. *New Engl J Med.* 2002 Aug;347(5):340-46. [PMID:12151472]
4. Beby-Defaux A, Brabant S, Chatellier D, Bourgoin A, Robert R, Ruckes T, Agius G. Disseminated varicella with multiorgan failure in an immunocompetent adult. *J of Med Virol.* 2009 Apr;81(4):747-49. [PMID:19235868]
5. Borum ML, Zimmerman HJ. Hepatitis associated with varicella infection in an immunocompetent adult. *J Clin Gastroenterol.* 1996 Sep;23(2):165. [PMID:8877654]
6. Gnann Jr. JW. Varicella-zoster virus: atypical presentations and unusual complications. *J Infect Dis.* 2002 Oct;186(supplement 1):S91-98. [PMID:12353193]
7. Moriuchi H, Moriuchi M, Sun CCJ, Trucksis M. Disseminated cutaneous zoster and aseptic meningitis in a previously healthy patient. *J Infection.* 1997 Sep;35(2):183-185. [PMID:9354356]
8. Burdett C, Mendoza N, Arora A, Bartlett B, Gewirtzman A, Tremaine AM, Tying S. A rare case of disseminated shingles in an immunocompetent patient following a 7-day treatment with oral valacyclovir. *J Clin Virol.* 2008 Oct;43:233–235. [PMID:18771948]
9. O'Toole EA, Mooney EE, Walsh JB, Sweeney EC, Barnes L. Disseminated herpes zoster in the elderly. *Infection.* 2009 Jul-Sep;37:179–180. [PMID:9256548]
10. Gupta S, Jain A, Gardiner C, Tying SK. A rare case of disseminated cutaneous zoster in an immunocompetent patient. *BMC Fam Pract.* 2005 Dec;14(6):50. [PMID:16351732]
11. Yoon KJ, Kim SH, Lee EH, Choi JH. Disseminated herpes zoster in an immunocompetent elderly patient. *Korean J Pain.* 2013 Apr; 26(2):195-198. [PMID:23614086]
12. Castillo C, Muruaga A, Carbonell A. Disseminated herpes zoster in an immunocompetent Host. *J Am Geriatr Soc.* 2012 Jun;60(6):1170. [PMID:22690988]
13. Capron J, Steichen O. Disseminated zoster in an elderly patient. *Infection.* 2009 Apr;37(2):179-80. [PMID: 19169630]