

# UC Davis

## Dermatology Online Journal

### Title

Effective local anesthesia for onabotulinumtoxin A injections to treat hyperhidrosis associated with traumatic amputation

### Permalink

<https://escholarship.org/uc/item/38b203d0>

### Journal

Dermatology Online Journal, 22(6)

### Authors

Shi, Lucy L  
Sargen, Michael R  
Chen, Suephy C  
[et al.](#)

### Publication Date

2016

### DOI

10.5070/D3226031332

### Copyright Information

Copyright 2016 by the author(s). This work is made available under the terms of a Creative Commons Attribution-NonCommercial-NoDerivatives License, available at <https://creativecommons.org/licenses/by-nc-nd/4.0/>

Letter

**Effective local anesthesia for onabotulinumtoxin A injections to treat hyperhidrosis associated with traumatic amputation**

Lucy L. Shi BA<sup>1</sup>, Michael R. Sargen MD<sup>1</sup>, Suephy C. Chen MD, MS<sup>1,2</sup>, Jack L. Arbiser MD, PhD<sup>1,2</sup>, Brian P. Pollack MD, PhD<sup>1,2</sup>

Dermatology Online Journal 22 (6): 20

<sup>1</sup> Emory University, Department of Dermatology, Atlanta, GA United States

<sup>2</sup> Atlanta Veterans Affairs Medical Center, Decatur, GA United States

**Correspondence:**

Michael Sargen, MD  
Emory Department of Dermatology  
1525 Clifton Road NE, 3<sup>rd</sup> Floor  
Atlanta, GA 30322  
Tel. (404) 727-3669 Fax. (877) 992-8778  
Email: michael.sargen@emory.edu

---

**Abstract:**

**Background:** Botulinum toxin type A (BTX-A) injections are an effective treatment for controlling hyperhidrosis at sites of amputation. Hyperesthesia associated with amputated limbs is a major barrier to performing this procedure under local anesthesia.

**Objective:** To present a novel method for improving local anesthesia with BTX-A injections.

**Methods & Results:** A 29-year-old military veteran with a below-the-knee amputation of his right leg was suffering from amputation site hyperhidrosis, which was impeding his ability to comfortably wear a prosthesis. Prior to presenting to our clinic, the patient received one treatment of BTX-A injections to his amputation stump while under general anesthesia for surgical repair of trauma-related injuries. In our dermatology clinic, we repeated the procedure using topical lidocaine-prilocaine (30 gm total) for local anesthesia. This provided effective relief of hyperhidrosis for 6 months, but the procedure was very painful (9/10 intensity). We repeated the same procedure 6 months later, using ice in addition to topical lidocaine-prilocaine (30 gm) for local anesthesia; this resulted in reduced pain (3/10 intensity) for the patient.

**Conclusions:** We suggest using ice in combination with a topical anesthetic as an effective method for pain control that avoids general anesthesia in treating amputation-associated hyperhidrosis.

**Keywords:** Hyperhidrosis, Amputees, Topical pain control, Clinical Case Reports

**Introduction:**

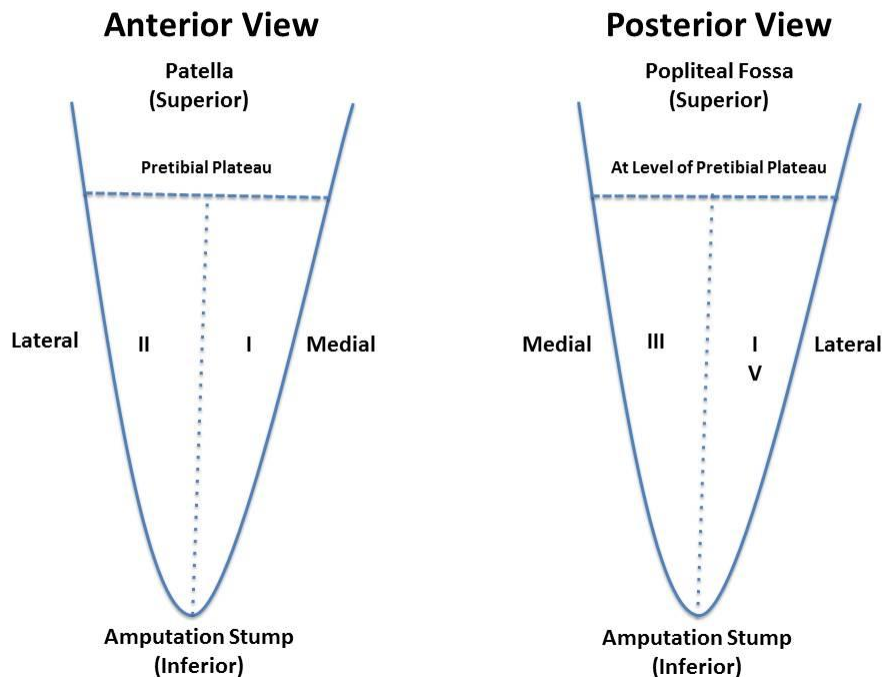
The number of U.S. service members with amputations has risen significantly in the past decade because of recent military conflicts abroad [1]. Hyperhidrosis at the amputation site with prosthesis use can cause an irritant contact dermatitis, which can severely impair mobility [2]. Amputation-site hyperhidrosis has been successfully treated with Botulinum toxin type A (BTX-A) injections, but this procedure is associated with substantial pain [3]. In this report, we describe a novel method for pain control that avoids general anesthesia when administering injections of BTX-A as a treatment for amputation-site hyperhidrosis.

## Case Report:

A 29-year-old army veteran with a below-the-knee amputation of his right leg caused by shrapnel injury from an improvised explosive device (IED) presented to the Atlanta Veterans' Affairs Medical Center (VAMC) in October 2014 for evaluation of hyperhidrosis of his amputation stump. Excessive sweating at the site of amputation made wearing his prosthesis particularly painful. The patient had previously applied barrier creams and 20% aluminum chloride hexahydrate solution to the affected skin without relief. While under general anesthesia to repair other injuries, he was concomitantly treated for hyperhidrosis with BTX-A injections circumferentially around the stump site. These injections resulted in markedly decreased sweating and irritation, which lasted for approximately 6 months.

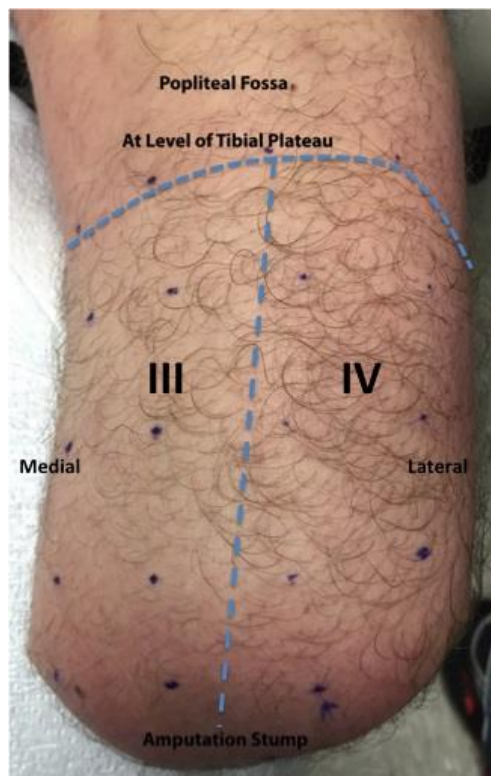
In October 2014, we performed the same procedure at the Atlanta VAMC Dermatology clinic. Topical 2.5% lidocaine-prilocaine cream (30 gm total) was applied to the amputation site and allowed to stay in place for 30 minutes. It was then removed and a grid-like pattern was drawn over the amputation stump using a gentian violet pen, with 2 cm between each injection site. One hundred units of BTX-A were injected in total, 2.5 units at each injection site. The procedure resulted in approximately 6 months of well-controlled sweating at the amputation stump, with comfortable usage of his prosthesis. However, because of the multiple injections and the hyperesthesia associated with amputated limbs, the procedure itself was very painful (9/10 intensity) [4].

The patient returned to clinic in June 2015 for a second round of injections. Topical 2.5% lidocaine-prilocaine was again (30 gm total) applied to the treatment area and allowed to sit for 30 minutes. A grid-like pattern was drawn using a gentian violet pen on the skin with 2 cm between each injection marking. The topical anesthetic was removed, and four Ziploc® freezer bags filled with ice were applied, one to each quadrant as shown in (Figure 1).



**Figure 1.** Graphic depicting the four quadrants into which the amputation site was divided. A freezer ice bag was applied to each quadrant.

After 5 minutes, the ice bags were removed and 2.5 units of BTX-A were injected at each skin marking with a total of approximately 25 units injected into each quadrant (Figure 2).



**Figure 2.** Amputation site divided into quadrant grid prior to injection. 25 units of BTX-A were injected into each quadrant.

A total of 100 units of BTX-A was used for the procedure. The combination of topical anesthetic and ice significantly reduced the pain associated with the procedure (3/10 intensity with combination analgesia).

## Discussion:

Hyperhidrosis at an amputation site occurs in up to 56% of limb amputees and is a well-documented cause for diminished quality of life [5]. Wollina et al. first described BTX-A injections as an effective treatment to control focal hyperhidrosis at an amputation site [3]. They performed BTX-A injections of a lower leg amputation stump in a diabetic patient without any local or general anesthesia. The authors did not comment on pain tolerability with the procedure, but diabetic neuropathy could have reduced the patient's ability to sense pain with injections. To date, a few case series have corroborated the successful use of BTX-A to treat amputation-associated hyperhidrosis, but none have adequately addressed methods of local anesthesia for this procedure, especially given hyperesthesia associated with amputated extremities [6-8]. Three case series chose not to use any analgesic at all prior to the procedure [3,7,8]. A fourth study used an unspecified amount of 1% lidocaine-prilocaine (EMLA) cream and cold spray [6]. We hypothesize that this procedure is not being performed widely, despite its efficacy, because of the inability of patients to tolerate the associated injection pain.

In this report, we describe our experience with a simple strategy for local pain control when administering BTX-A injections to treat amputation-associated hyperhidrosis. Prior to presentation, our patient had undergone BTX-A injections once previously, which was performed under general anesthesia. At our clinic, we used a novel approach for pain control by combining topical 2.5% lidocaine-prilocaine cream with local application of an ice-containing cold pack. Compared to using the topical anesthetic alone, this combination reduced the subjective pain associated with the procedure from 9/10 to 3/10 intensity. Moreover, local pain control enabled us to avoid general anesthesia for this patient.

Effective local anesthesia is a major barrier to treating amputation-site hyperhidrosis with BTX-A injections. Our case report provides a novel and simple method for local pain control while performing this procedure. With the growing number of amputees owing to recent military conflicts and other medical etiologies, the frequency of this procedure will undoubtedly increase. Because of their expertise with the administration of BTX-A, dermatologists will likely be more regularly called upon to perform this procedure in the office.

## References

1. Krueger CA, Wenke JC, Ficke JR. Ten years at war: comprehensive analysis of amputation trends. *J Trauma Acute Care Surg.* 2012;73(6 Suppl 5):S438-444. PMID: 23192067
2. Meulenbelt HE, Geertzen JH, Dijkstra PU, Jonkman MF. Skin problems in lower limb amputees: an overview by case reports. *J Eur Acad Dermatol Venereol.* 2007;21(2):147-155. PMID: 16716178
3. Wollina U, Konrad H, Graefe T, Thiele J. Botulinum toxin A for focal hyperhidrosis in leg amputees: a case report. *Acta Derm Venereol.* 2000;80(3):226-227. PMID: 10954228
4. Saris SC, Iacono RP, Nashold BS. Dorsal root entry zone lesions for post-amputation pain. *J Neurosurg.* 1985;62(1):72-76. PMID.
5. Glaser DA, Galperin TA. Botulinum toxin for hyperhidrosis of areas other than the axillae and palms/soles. *Dermatol Clin.* 2014;32(4):517-525. PMID: 25152345
6. Charrow A, DiFazio M, Foster L, Pasquina PF, Tsao JW. Intradermal botulinum toxin type A injection effectively reduces residual limb hyperhidrosis in amputees: a case series. *Arch Phys Med Rehabil.* 2008;89(7):1407-1409. PMID: 18586144
7. Kern U, Kohl M, Seifert U, Schlereth T. Botulinum toxin type B in the treatment of residual limb hyperhidrosis for lower limb amputees: a pilot study. *Am J Phys Med Rehabil.* 2011;90(4):321-329. PMID: 21765248
8. Garcia-Morales I, Perez-Bernal A, Camacho F. Letter: Stump hyperhidrosis in a leg amputee: treatment with botulinum toxin A. *Dermatol Surg.* 2007;33(11):1401-1402. PMID: 17958602