

UCLA

UCLA Previously Published Works

Title

Aspergillus fumigatus vegetation of a prosthetic aortic root graft with mycotic aneurysm and subarachnoid hemorrhage.

Permalink

<https://escholarship.org/uc/item/34v4q518>

Journal

International journal of infectious diseases : IJID : official publication of the International Society for Infectious Diseases, 17(9)

ISSN

1878-3511

Authors

Oyama, Jared
Zhou, Linda
Mehta, Seema A
[et al.](#)

Publication Date

2013-09-09

Peer reviewed



Case Report

Aspergillus fumigatus vegetation of a prosthetic aortic root graft with mycotic aneurysm and subarachnoid hemorrhage

Jared Oyama^a, Linda Zhou^a, Seema A. Mehta^b, Anna R. Laury^c, John S. Tsakonas^a, Hillel Laks^d, Henry M. Honda^a, Eric H. Yang^{a,*}

^a Division of Cardiology, Department of Medicine, UCLA Cardiovascular Center, University of California at Los Angeles Medical Center, 100 Medical Plaza, Suite 630, Los Angeles, CA 90095, USA

^b Division of Infectious Diseases, Department of Medicine, University of California at Los Angeles Medical Center, Los Angeles, California, USA

^c Department of Pathology and Laboratory Medicine, University of California at Los Angeles Medical Center, Los Angeles, California, USA

^d Division of Cardiothoracic Surgery, Department of Surgery, University of California at Los Angeles Medical Center, Los Angeles, California, USA

ARTICLE INFO

Article history:

Received 3 October 2012

Received in revised form 23 November 2012

Accepted 29 November 2012

Corresponding Editor: Eskild Petersen, Skejby, Denmark

Keywords:

Aortic root surgery

Bentall graft

Aspergillus

Vegetation

Thrombosis

Shock (sepsis

cardiogenic)

Extracorporeal membrane oxygenation

SUMMARY

A 58-year-old woman with a history of Bentall aortic graft and bioprosthetic aortic valve replacement 3 months prior to admission, presented with headache and fever. Imaging yielded a large obstructive filling defect in the ascending aorta, a subarachnoid hemorrhage, and a mycotic aneurysm. Intraoperative specimens grew *Aspergillus fumigatus*, and despite aggressive measures the patient died. *Aspergillus* infections of prosthetic vascular grafts are rare surgical complications and are difficult to diagnose given the low incidence of positive microbiology cultures and the long median time between surgery and diagnosis. Treatment has consisted of antifungal and surgical treatment, although mortality remains high.

© 2012 International Society for Infectious Diseases. Published by Elsevier Ltd. All rights reserved.

1. Introduction

Aspergillus vascular graft infections are devastating complications of vascular surgical procedures and have been associated with high mortality despite aggressive medical and surgical interventions. This is likely due to delays in diagnosis given its insidious nature, and the lack of effective diagnostic modalities. We present a patient who presented with neurologic and embolic manifestations of a large *Aspergillus fumigatus* vegetation of her Bentall aortic prosthetic graft.

2. Case report

A 58-year-old woman with a history of aortic regurgitation and an ascending aortic aneurysm was transferred from an outside hospital for a higher level of care after she presented with

symptoms of headache, fever, and shortness of breath, and was found to have a subarachnoid hemorrhage and an ascending aortic mass.

Three months prior, at an outside hospital, she underwent an attempted valve sparing root replacement operation using a 26-mm Hemashield graft (Maquet, Wayne, NJ) that was converted to a Bentall procedure when residual aortic regurgitation was seen with poor coaptation of the noncoronary leaflet. She then underwent placement of a 19-mm Mitroflow aortic pericardial valve (Sorin Group, Vancouver, Canada) and 24-mm Dacron prosthetic aortic root graft during the same procedure. The operation was complicated with a prolonged cardiopulmonary bypass time. Her postoperative course was complicated by complete heart block necessitating dual chamber pacemaker implantation.

Approximately 6 weeks after discharge, she was noted to have a sternal wound infection and underwent superficial debridement. Her cultures grew *Staphylococcus epidermidis*, and although there was no evidence of bony involvement, she was discharged on home intravenous vancomycin for concern of osteomyelitis.

* Corresponding author. Tel.: +1 310 825 9011; fax: +1 310 794 0011.

E-mail addresses: Datsunian@gmail.com, ehyang@mednet.ucla.edu (E.H. Yang).

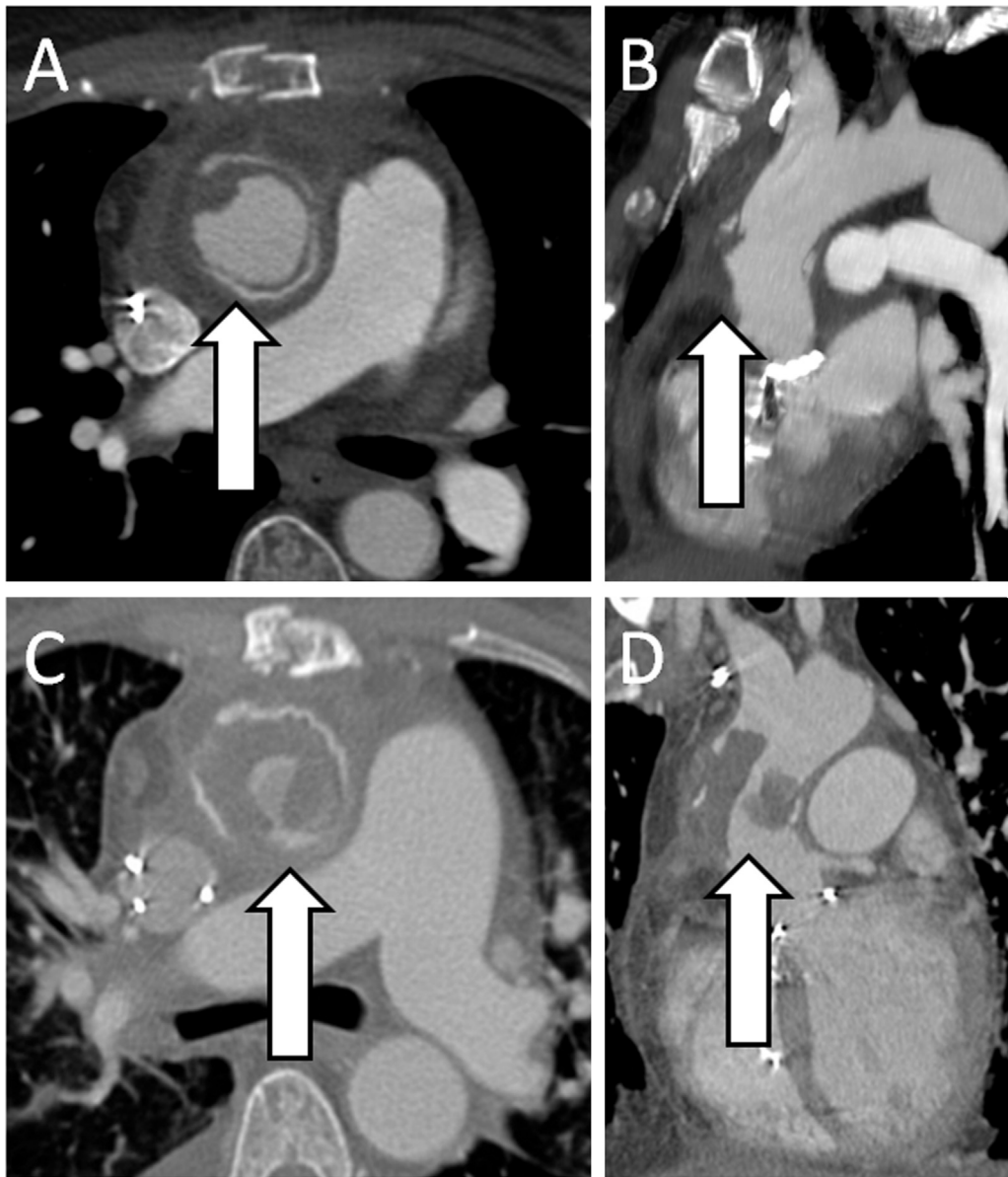


Figure 1. Sixty-four-slice contrast-enhanced computed tomography angiography (CTA) of the chest done 2 months prior to admission to rule out pulmonary embolism (A and B), and on this admission (C and D). The previous CT findings (arrows) were interpreted as postsurgical changes with a nonspecific rim of fluid in the aortic graft. Repeat CT on this admission demonstrated a large filling defect (arrows) within the Dacron aortic root graft. (A and C: axial views; B and D: sagittal views.).

Echocardiography at the time demonstrated normal left ventricular systolic function.

At the time of transfer to our institution, the patient was febrile to 38.8 °C, with a leukocytosis of $21.74 \times 10^9/l$. Echocardiography demonstrated a left ventricular ejection fraction of 45% with apical akinesis and abnormal septal motion. A computed tomography (CT) angiogram of the chest was negative for pulmonary embolism, but incidentally noted a large, obstructive filling defect in the ascending aorta consistent with thrombus, which was new in comparison with imaging done 2 months prior at an outside hospital (Figure 1). A noncontrast CT of the brain revealed a subarachnoid hemorrhage involving the right Sylvian fissure. CT angiography of the brain demonstrated findings concerning for a mycotic aneurysm of the right middle cerebral artery.

On hospital day 2, she underwent coil embolization of the cerebral aneurysm. Over the following day, the patient was noted to have increasing left- and right-sided filling pressures and declining cardiac outputs on pulmonary artery catheter

monitoring, weak peripheral pulses, and rising liver enzymes. The patient deteriorated abruptly and went into pulseless electrical activity arrest on hospital day 4. Following cardiopulmonary resuscitation, venous–arterial extracorporeal membrane oxygenation (ECMO) was initiated. Repeat CT scans demonstrated propagation of the thrombus with new filling defects in the descending thoracic and abdominal aorta, right external iliac, and right common femoral arteries with splenic infarcts. A CT of the brain demonstrated stable findings with no new bleeding.

Given her circulatory decompensation and thrombus propagation, she was taken emergently to the operating room for exploration and replacement of the aortic graft. Extensive whitish vegetations atypical for bacterial origin were noted throughout the interior of the Dacron graft. The aortic valve bioprosthesis was uninvolved. The majority of the graft was replaced with a modified CryoValve aortic allograft (CryoLife, Kennesaw, GA).

Postoperatively, the patient required sternal re-exploration for significant bleeding, as well as embolectomy of the right external

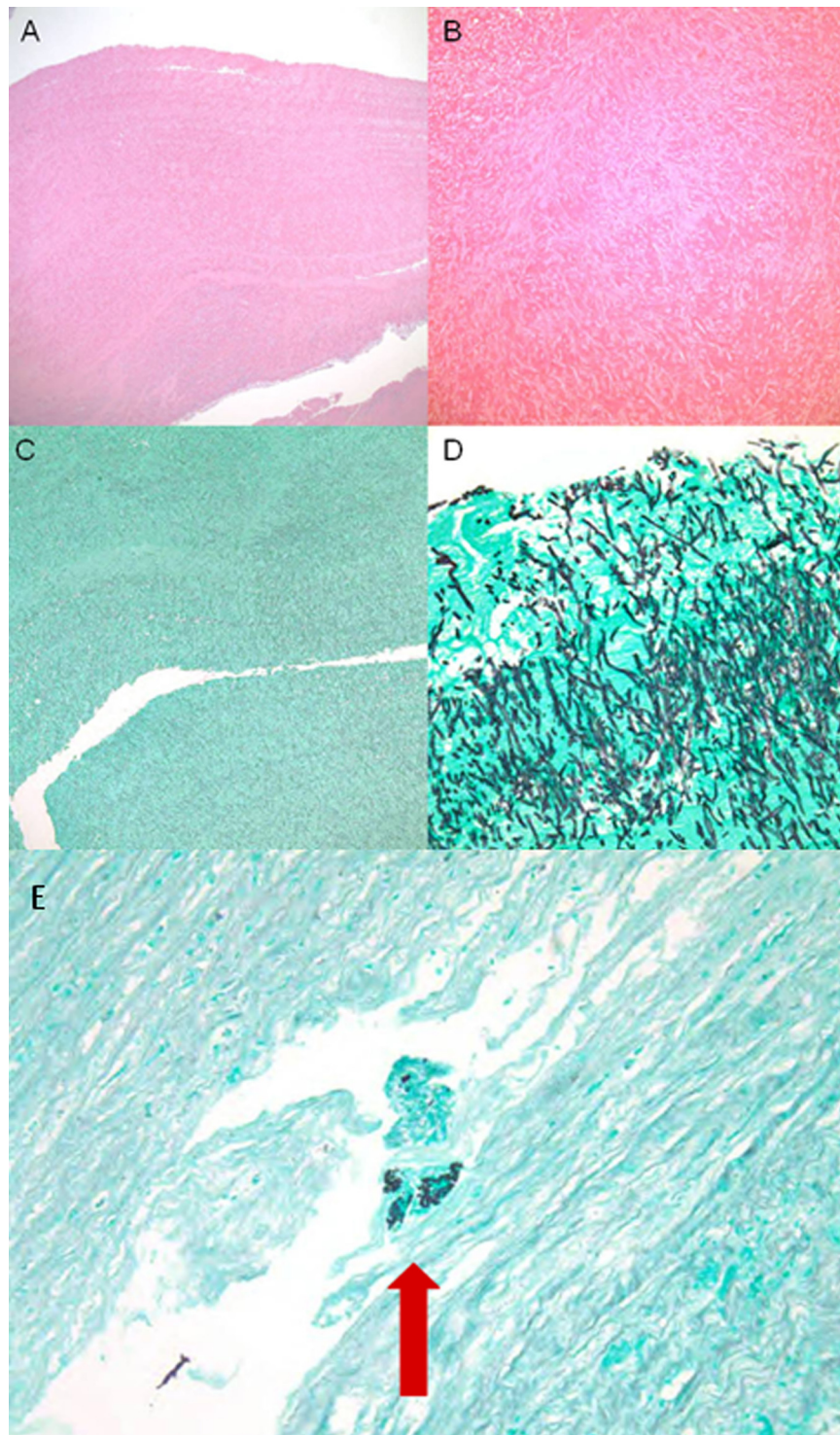


Figure 2. Microscopic examination of tissue from the aortic conduit revealed a vegetation. Sections show slender fungal hyphae with distinct septations and 45-degree branching, morphologically consistent with *Aspergillus* spp. Hematoxylin and eosin (H&E) stain at 2 × (A) and 400 × (B) magnification. Gomori methenamine silver (GMS) stain at 2 × (C) and 40 × (D) magnification. Microscopic examination of the aorta, GMS stain, 40× magnification (E), revealed rare fungal hyphae within the muscular wall (arrow).

iliac, common femoral, and profunda femoris arteries. She developed anuric renal failure and status epilepticus. Echocardiography on ECMO demonstrated severe left ventricular dysfunction with an ejection fraction of less than 20%.

On hospital day 7, pathology from the intraoperative specimens revealed that the material in the aortic graft was a vegetation composed of *Aspergillus* species (Figure 2); intraoperative cultures

subsequently grew one colony of *A. fumigatus*. All fungal and bacterial blood cultures collected during her hospitalization remained negative. She had been on broad-spectrum antibiotic therapy since admission, and with the intraoperative pathology result, she was immediately started on dual antifungal therapy with voriconazole and caspofungin. The following day, a CT of the brain demonstrated uncal herniation, and brain death was

pronounced shortly thereafter. Mechanical ventilatory and circulatory support were subsequently withdrawn and cardiac death was pronounced on hospital day 8.

3. Discussion

Aspergillus fumigatus is a ubiquitous fungus typically found in soil and decaying organic matter which can produce airborne conidia that can cause infections in immunosuppressed patients. These can consist of invasive pulmonary aspergillosis, invasive sinusitis, or disseminated aspergillosis. Extrapulmonary manifestations of the *Aspergillus* species can include primary cutaneous infections, osteomyelitis, and tracheobronchitis.¹

Twenty-four prosthetic vascular graft infections with *Aspergillus* have been reported in the literature,^{2–5} along with reported cases of aortitis following cardiac valve and coronary artery bypass surgery.² The patient population with infected vascular grafts were nearly all men and immunocompetent. Of the 17 documented case reports, the median age was 57 years (range 11 to 73 years), and the median time between surgery and diagnosis was 10 months (range 5 days to 44 months). Four patients had concurrent vertebral osteomyelitis, and approximately half had documented fevers. Seven patients had evidence of arterial embolization. Only two patients had positive blood cultures. Other species known to cause vascular graft infection include *Aspergillus flavus* and *Aspergillus terreus*. Eight patients died during their hospitalization.^{2–5}

The mechanism of infection is suspected to be through contamination of the graft in the operating room with airborne spores.^{1–4} Treatment has consisted of both aggressive antifungal and surgical treatment, including graft excision and extra-anatomic bypass, although mortality remains high. Given the

difficulty in establishing a diagnosis due to the lack of positive blood cultures in most cases, nonspecific clinical presentation, varying clinical course, and lack of definitive imaging characteristics of graft infections, there is no optimal strategy as to when to surgically intervene or conservatively treat with antifungal therapy. Of note, in the cases documented in the literature, the patients who did not undergo extra-anatomic bypass had 100% mortality. However, doing so did not ensure survival as two died after surgery, as well as our case.

In summary, *Aspergillus* vascular graft infections are insidious in nature and can be very difficult to detect until end-stage manifestations occur (i.e., arterial embolization, sepsis), which are associated with significant comorbidity and mortality. Antifungal therapy and surgical resection of the infected graft with extra-anatomic bypass appear to be optimal strategies in order to improve survival.

Conflict of interest: The authors have no conflicts of interest to disclose.

References

1. Paterson DL. New clinical presentations of invasive aspergillosis in non-conventional hosts. *Clin Microbiol Infect* 2004;**10**(Suppl 1):24–30.
2. Pasqualotto AC, Denning DW. Post-operative aspergillosis. *Clin Microbiol Infect* 2006;**12**:1060–76.
3. Rahkonen M, Hautala T, Syväniemi E, Takalo R, Kauma H. Late-presenting vascular graft infection caused by *Aspergillus* in an immunocompetent patient. *Mycoses* 2012;**55**:95–8.
4. Collazos J, Mayo J, Martinez E, Ibarra S. Prosthetic vascular graft infection due to *Aspergillus* species: case report and literature review. *Eur J Clin Microbiol Infect Dis* 2001;**20**:414–7.
5. Calcaterra D, Bashir M, Gailey MP. Ascending aortic graft thrombosis and diffuse embolization from early endoluminal *Aspergillus* infection. *Ann Thorac Surg* 2012;**94**:1337–9.