

UC Davis

Dermatology Online Journal

Title

Secondary bilateral striopallidodentate calcinosis associated with generalized pustular psoriasis (Von Zumbusch)

Permalink

<https://escholarship.org/uc/item/33n0k26j>

Journal

Dermatology Online Journal, 19(6)

Authors

Pacheco, David
Travassos, Ana Rita
Antunes, Joana
et al.

Publication Date

2013

DOI

10.5070/D3196018569

Copyright Information

Copyright 2013 by the author(s). This work is made available under the terms of a Creative Commons Attribution-NonCommercial-NoDerivatives License, available at <https://creativecommons.org/licenses/by-nc-nd/4.0/>

Peer reviewed

Case Report

Secondary bilateral striopallidodentate calcinosis associated with generalized pustular psoriasis (Von Zumbusch)

David Pacheco, Ana Rita Travassos, Joana Antunes, Manuel Sacramento Marques, Paulo Filipe, Raquel Silva

Dermatology Online Journal 19 (6): 12

Serviço de Dermatologia, Hospital de Santa Maria- Centro Hospitalar Lisboa Norte

Correspondence:

David Pacheco MD

Serviço de Dermatologia, Hospital de Santa Maria- Centro Hospitalar Lisboa Norte

Avenida Prof. Egas Moniz 1649-028 Lisboa, Portugal

Telefone: +351 969470229

E-mail address: pachecocas@hotmail.com

Abstract

Bilateral striopallidodentate calcinosis (BSPDC) mentioned in the literature as Fahr's disease (a misnomer), is characterized by symmetrical and bilateral intracerebral calcifications located in the basal ganglia with or without deposits in the dentate nucleus, thalamus, and white matter. This entity is usually asymptomatic but may be manifested by neurological symptoms. Idiopathic BSPDC can occur either as sporadic or autosomal dominant familial forms. Secondary presentations of BSPDC are associated with infections, neoplastic diseases, toxicological or traumatic factors, and metabolic disorders. We describe a case of generalized pustular psoriasis associated with secondary BSPDC owing to pseudohypoparathyroidism. Laboratory tests revealed hypocalcemia, hyperphosphatemia, and a normal serum level of parathormone. The correction of the phosphorus-calcium metabolism disorder produced clinical improvement.

Introduction

Bilateral striopallidodentate calcinosis (BSPDC) was first described by Delacour in 1850 and has been designated in the literature by 35 different terms [1]. It is commonly referred to as Fahr disease (a misnomer), which can lead to some confusion and thus must be avoided. Bilateral striopallidodentate calcinosis is a rare disorder characterized by symmetrical and bilateral intracerebral calcifications of the basal ganglia with or without deposits in the dentate nucleus, thalamus, and white matter. This entity may be entirely asymptomatic or expressed by protean neurological or neuropsychiatric manifestations [2]. The classification can be based on the anatomical involvement of calcification or on etiological criteria. Primary forms of BSPDC may be classified as either familial or sporadic, with the familial form usually being inherited in an autosomal dominant manner. Secondary forms are referred to as metabolic, infectious, toxic, and other [1]. Endocrine disorders, such as hypoparathyroidism and pseudohypoparathyroidism, are also secondary causes of BSPDC [1,3].

Pseudohypoparathyroidism is a condition associated with resistance to parathormone, which causes severe hypocalcemia and hyperphosphatemia. Generalized pustular psoriasis is an acute uncommon severe form of psoriasis, characterized by widespread pustules on an erythematous background. Hypocalcemia is one of the various precipitating factors of this acute psoriasis subtype.

Case report

Herein, we describe the case of a 34-year-old man with a history of epilepsy that was asymptomatic for the past nineteen years and not requiring medication. He was first admitted to the hospital fifteen years ago, owing to an episode of generalized pustular psoriasis. At the time, laboratory findings revealed elevated serum phosphorus (5.3 mg/dl; ref. 2.4-5.1mg/dL) and a low concentration of serum calcium (5.8 mg/dl; ref. 8.6-10mg/dL) and serum albumin (2.4 g/dl; ref. 3.2-4.9 g/dl). The patient's calcium level adjusted to the albumin values was 6.9 mg/dl and serum parathormone (PTH) levels were 113.5 pg/mL (ref. 14-72 pg/mL) leading to the diagnosis of pseudohypoparathyroidism. A cranial CT scan was performed, which demonstrated bilateral symmetrical calcifications with a cloudy pattern, involving mainly the basal ganglia, thalamic nuclei, and white matter. Dispersed cerebellar and bilateral cortical calcifications were also exhibited. Based on these findings the diagnosis of Fahr syndrome was

established. The patient was treated with acitretin 25 mg/d until achieving complete clinical remission and was discharged on this medication along with oral calcium and vitamin D.

The patient was hospitalized for the second time because of another episode of extensive generalized pustular psoriasis. Five days before the appearance of skin lesions, the patient had ingrown nail surgery and was medicated with flucloxacillin. On examination he looked ill, pallid, and depressed. His skin showed widespread sterile pustules coalescing into lakes of pus with subsequent exfoliation (the Zumbusch pattern) (Figure 1). Skin biopsies revealed: intradermal and subcorneal spongiform pustules containing neutrophils, compatible with psoriasis (Figure 2).

Laboratory investigations revealed leukocytosis $26.540 \times 10^9/L$ (ref. $4.0-11.0 \times 10^9/L$), elevated erythrocytic sedimentation rate 62 mm in the first hour; (ref. < 10 mm), C reactive protein (14.1 mg/dl; ref. < 0.5 mg/dl), serum glucose (124 mg/dl; ref. 70-110 mg/dl), aspartate aminotransferase (561 U/L; ref. < 34 U/L), alanine transaminase (763 U/L; ref. 10-49 U/L), lactate dehydrogenase (1840 U/L; ref. 208-378 U/L). Bilirubin and gamma-glutamyl transpeptidase serum levels were within normal range. Serum albumin was 2.8 g/dl (ref. 3.2-4.9 g/dl), phosphocalcic investigations revealed increased serum phosphorus (5.9 mg/dl; ref. 2.4-5.1 mg/dL) and low concentration of serum calcium (5.4 mg/dl; ref. 8.6-10 mg/dL). The patient's calcium level adjusted to the albumin values was 6.4 mg/dl. Serum parathormone (PTH) levels were normal. A new cranial CT scan was performed, which corroborated the previous CT scan carried out 15 years ago (Figure 3).

During the following days the patient had febrile spikes with increased inflammatory laboratory parameters. Methicillin-resistant *Staphylococcus aureus*, sensitive to vancomycin, was isolated in blood cultures. Transthoracic echocardiogram did not show any changes. His temperature returned to normal after a two-week course of intravenous therapy with vancomycin. Abnormal liver function tests remained unaltered during the hospital stay, but the abdominal ultrasonography was normal. Acitretin 25 mg daily was given with a progressive slow recovery of the skin lesions.

The patient was discharged medicated with acitretin 10 mg, calcium 1500 mg, and vitamin D 400 IU daily. He continued to have occasional episodes of focal pustular eruptions thereafter. Currently, his dermatosis is controlled without new outbreaks of pustular psoriasis in the last two years.

Discussion

Bilateral striopallidodentate calcinosis can be classified as primary or secondary. Idiopathic forms can be sporadic or familial with some cases presenting alterations in chromosome 14q [4]. Secondary forms are mostly associated with developmental or connective tissue disorders, toxic insults, and metabolic diseases such as hypoparathyroidism and pseudohyperparathyroidism [1,5].

Diagnostic criteria for idiopathic BSPDC are defined by:

- 1- Calcifications of the basal ganglia with or without deposits in dentate nucleus, thalamus, and white matter (assessed by imaging studies)
- 2- Progressive neurological deterioration or neuropsychiatric manifestations
- 3- Onset in fourth or fifth decades, but may be present in younger ages.
- 4- Absence of laboratory or clinical changes suggestive of metabolic disease or other systemic disorder
- 5- Absence of infectious, traumatic, or toxic etiologies
- 6- Family history consistent with autosomal dominant pattern

If the patient fulfills the last criterion and one of the first two criteria, the diagnosis can be established. If the last criterion is negative or cannot be proved, the patient must present the other five criteria for the diagnosis [1,6].

The present case is compatible with the diagnosis of secondary BSPDC: intracerebral calcifications in the basal ganglia, thalamus and cerebellum in a cloudy pattern [7,8] and pseudohyperparathyroidism.

Pseudohypoparathyroidism is one of the main etiological disorders of secondary BSPDC and is caused by resistance to the action of parathormone, accompanied essentially by hypocalcemia and a normal or a high level of parathormone [9,10]. Laboratory

testing should include blood calcium and parathormone in addition to other routine blood tests; these may help in differentiating idiopathic BSPDC (unremarkable laboratory test results) from secondary cases, especially ones related to hypoparathyroidism or pseudohyperparathyroidism. A flare of generalized pustular psoriasis had occurred fifteen years before in our patient and probably had been triggered by hypocalcemia in the context of pseudohyperparathyroidism.

Before the second flare of generalized pustular psoriasis the patient had discontinued calcium and vitamin D therapy. A few days before the second episode of generalized pustular psoriasis, he had ingrown nail surgery and was medicated with flucloxacillin. The combination of these factors, hypocalcemia, infection, and surgery, are well-known triggers of generalized pustular psoriasis

Hypocalcemia associated with disorders of the parathyroid gland may precipitate psoriasis vulgaris and pustular psoriasis (Table 1). The etiological role of calcium in psoriasis pathogenesis remains unclear. Other known precipitating factors of generalized pustular psoriasis include: topical therapies (vitamin D derivatives, tars, anthralin, application of corticosteroids under occlusion, and zinc pyrithione), drugs such as salicylates, iodine, lithium salts, phenylbutazone, oxyphenbutazone, trazodone, penicillins, antimalarials, calcipotriol, interferon-alpha, infections, and hypocalcaemia [11]. Moreover, in some severe cases, hepatitis and cholangitis have been associated with generalized pustular psoriasis [12].

Some other dermatological disorders, like Urbach-Weithe disease (lipoid proteinosis) and hydrotic-ectodermal dysplasia, have been associated with the finding of intracerebral calcifications, mainly located in the amygdala [13], but also involving the basal ganglia [14,15]. Another case report described a case of Fahr syndrome associated with hypoparathyroidism and this patient showed papular lesions in the dorsal skin of the hands with a claw-like appearance, without a precise dermatological diagnosis [16].

In the case of our patient, correction of the precipitating factors allowed for the control of both endocrinological and dermatological pathologies. The adjustment of his phosphorus-calcium metabolism disorder allowed clinical improvement as also noted in other case reports [17].

To the best of our knowledge, this is the first case with the concomitant presentation of BSPDC, pseudohyperparathyroidism, and acute generalized pustular psoriasis. From a dermatological point of view, it is important to take into consideration the diagnosis of BSPDC in patients with generalized pustular psoriasis associated with severe hypocalcemia and epilepsy.

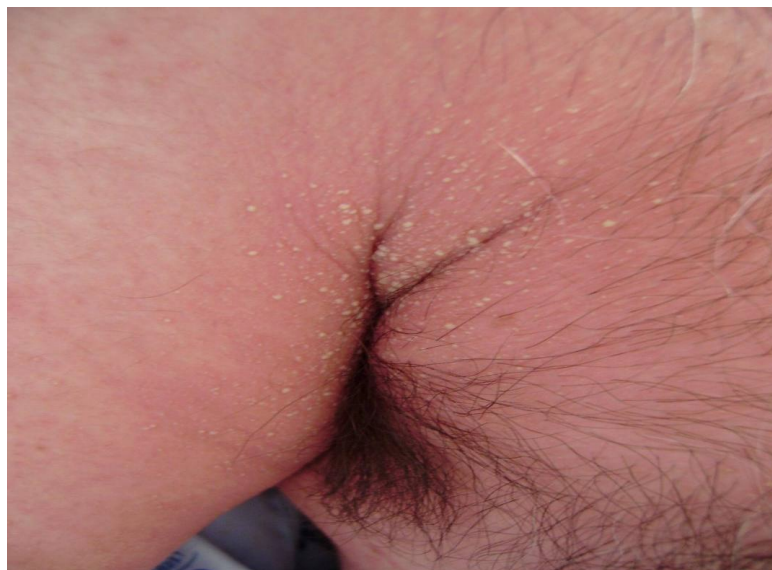

Figure 1. Raised bumps on the chest wall and arm, that are filled with pus (pustules). The skin under and around these bumps is reddish

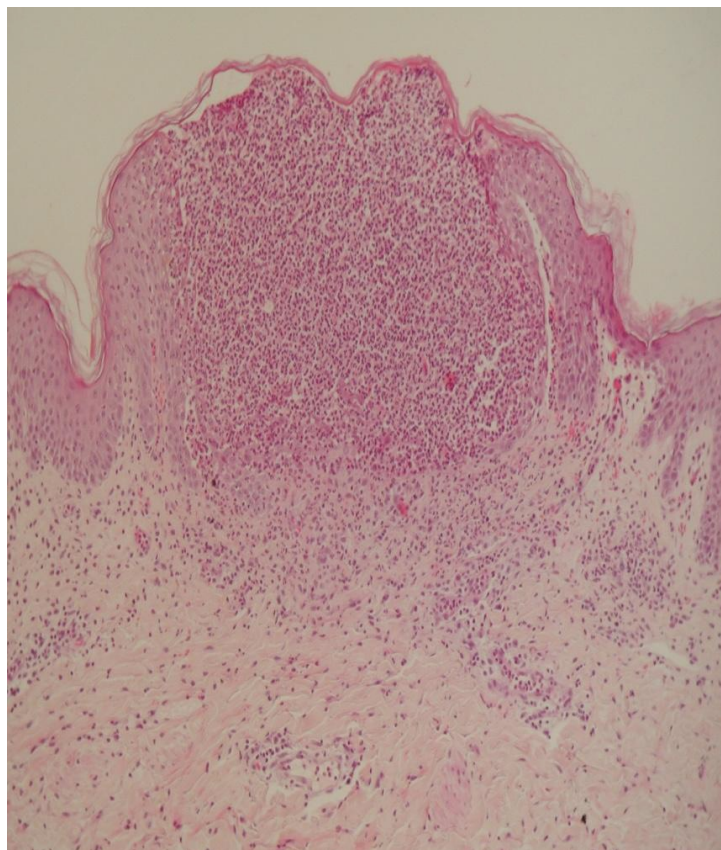


Figure 2. Intradermal and subcorneal spongiform pustules constituted by neutrophils compatible with psoriasis

Sources	BPSDC	Hypoparathyroidism	Pseudohypoparathyroidism	Plaque Psoriasis	Pustular Psoriasis
Vickers et al (1963)	-	+	-	+	-
Risum et al (1973)	-	+	-	+	-
Stewart et al (1984)	-	+	-	-	+
Tercedor et al (1991)	-	+	-	-	+
Boisseau-Garsaud et al (1993)	-	-	+	+	-
Kawamura et al (1999)	-	+	-	-	+
Renan et al (2002)	+	-	+	+	-
Ashkevari et al (2004)	-	+	-	-	+
Aksoylar et al (2004)	-	+	-	-	+

Preiss et al (2005)	-	+	-	-	+
John et al (2006)	+	+	-	-	+
Imaeda et al (2012)	+	+	-	+	-

Table 1. Reported cases of plaque-type and pustular psoriasis in hypoparathyroidism and pseudohyperparathyroidism.

References

1. [Manyam BV](#). What is and what is not 'Fahr's disease'. [Parkinsonism Relat Disord](#). 2005 Mar;11(2):73-80. [PMID: 15734663]
2. Hempel A, Henze M, Berghoff C, Garcia N, Ody R, Schroder J. PET findings and neuropsychological deficits in a case of Fahr's disease. [Psychiatry Res](#). 2001 Nov 30;108(2):133-40. [PMID: 11738547]
3. [Khammassi N](#), [Chrifi J](#), [Mohsen D](#), [Abdelhedi H](#), [Tougourt MN](#), [Hamza M](#). Fahr's syndrome: two case report. [Rev Neurol \(Paris\)](#). 2010 Apr;166(4):446-50 [PMID:19758669]
4. [Brodaty H](#), [Mitchell P](#), [Luscombe G](#), [Kwok JJ](#), [Badenhop RF](#), [McKenzie R](#), [Schofield PR](#). Familial idiopathic basal ganglia calcification (Fahr's disease) without neurological, cognitive and psychiatric symptoms is not linked to the IBGC1 locus on chromosome 14q. [Hum Genet](#). 2002 Jan;110(1):8-14. [PMID 11810290]
5. Kowdley KV, Coul BM, Orwall ES. Cognitive impairment and intracranial calcification in chronic hypoparathyroidism. [Am J Med Sci](#). 1999 May;317(5):273-7. [PMID: 10334112].
6. [Lazăr M](#), [Ion DA](#), [Streinu-Cercel A](#), [Bădărău AI](#). Fahr's syndrome: diagnosis issues in patients with unknown family history of disease. [Rom J Morphol Embryol](#). 2009;50(3):425-8. [PMID: 19690769].
7. Faria AV, Pereira IC, Nanni L. Computerized tomography findings in Fahr's syndrome. [Arq Neuropsiquiatr](#). 2004 Sep;62(3B):789-92. [PMID:15476070].
8. Packard M. G, Knowlton B. J. Learning and memory functions of Basal Ganglia. [Annu Rev Neurosci](#). 2002;25:563-93. [PMID:12052921].
9. Kalinowska-Nowak A, Garlicki A, Bociaga-Jasik M, Sobczyk-Krupiarz I, *Mach T*. Calcifications of basal ganglia and cerebellum in patient with pseudohypoparathyroidism, case report. [Przegl Lek](#). 2002;59(7):548-50. [PMID:12516248].
10. Kahloul N, Chaari W, Boughamoura L, Charfeddine L, Khammeri S, Amri F. Pseudohypoparathyroidism revealed by Fahr syndrome. [Arch Pediatr](#). 2009 May;16(5):444-8. [PMID:19339164].
11. [Tobin AM](#), [Langan SM](#), [Collins P](#), [Kirby B](#). Generalized pustular psoriasis (von Zumbusch) following the use of calcipotriol and betamethasone dipropionate ointment: a report of two cases. [Clin Exp Dermatol](#). 2009 Jul;34(5):629-30. [PMID: 19508565].
12. [Borges-Costa J](#), [Silva R](#), [Gonçalves L](#), [Filipe P](#), [Soares de Almeida L](#), [Marques Gomes M](#). Clinical and Laboratory Features in Acute Generalized Pustular Psoriasis: A Retrospective Study of 34 Patients. [Am J Clin Dermatol](#). 2011 Aug 1;12(4):271-6. [PMID:21495733].
13. Newton FH, Rosenberg RN, Lambert PW, O'Brien JS. Neurologic involvement in Urbach–Wiethe's disease (lipoid proteinosis). A clinical, ultrastructural, and chemical study. [Neurology](#). 1971 Dec;21(12):1205-13. [PMID:5002423].
14. [Dogramaci AC](#), [Celik MM](#), [Celik E](#), [Bayarogullari H](#). Lipoid proteinosis in the eastern Mediterranean region of Turkey. [Indian J Dermatol Venereol Leprol](#). 2012 May-Jun;78(3):318-22. [PMID: 22565431]
15. Copeland, DD, Lamb, WA, Klintworth, GK. Calcification of basal ganglia and cerebellar roof nuclei in mentally defective patient with hidrotic ectodermal dysplasia. Analysis of intracranial concretions by electron microprobe. [Neurology](#). 1977 Nov;27(11):1029-33. [PMID: 562997].
16. [Aditya A](#), [Lele S](#), [Aditya P](#). Fahr's disease with oral manifestations: report of a rare case. [Med Princ Pract](#). 2012;21(4):395-7. [PMID: 22472706].

17. [Abe S](#), [Tojo K](#), [Ichida K](#), [Shigematsu T](#), [Hasegawa T](#), [Morita M](#), [Sakai O](#). A rare case of idiopathic hypoparathyroidism with varied neurological manifestations. [Intern Med](#). 1996 Feb;35(2):129-34. [PMID:8680101].