

UC Davis

Dermatology Online Journal

Title

Cutaneous manifestations of disseminated gonococemia

Permalink

<https://escholarship.org/uc/item/33b24006>

Journal

Dermatology Online Journal, 23(1)

Authors

Beatrous, Surget V
Grisoli, Stratton B
Riahi, Ryan R
et al.

Publication Date

2017

DOI

10.5070/D3231033674

Copyright Information

Copyright 2017 by the author(s). This work is made available under the terms of a Creative Commons Attribution-NonCommercial-NoDerivatives License, available at <https://creativecommons.org/licenses/by-nc-nd/4.0/>

Peer reviewed

Cutaneous manifestations of disseminated gonococemia

Surget V. Beatrous¹ BS, Stratton B. Grisoli² MD, Ryan R. Riahi² MD, Gaston A. de la Bretonne, Jr² MD, Ryan J. Matherne² MD

Affiliations: ¹Medical School, Louisiana State University Health Sciences Center, New Orleans, Louisiana, ²The Department of Dermatology, Louisiana State University, New Orleans, Louisiana

Corresponding Author: Surget V. Beatrous, BS. 433 Bolivar Street New Orleans, LA 70112. Sbeat2@lsuhsc.edu

Abstract

Background: Sexually transmitted infections, including urogenital gonorrheal infection, are a growing health concern in the United States. Nearly 50% of cervical infections are asymptomatic. If left undiagnosed and untreated, there is a risk of disseminated infection. **Purpose:** To describe an 18-year-old woman presenting with disseminated gonococcal infection confirmed by blood cultures, skin biopsy, and urine gonococcal probe. We also describe the presentation, diagnosis, and treatment of disseminated gonococcal infection, including discussion of the various morphologies of cutaneous lesions that have been reported in the literature. **Materials and Methods:** The features of a woman with disseminated gonococcal infection are presented. Using PubMed, the terms cutaneous, disseminated, gonococcal, gonorrhea, infection, lesions, manifestations, pustules, skin, and systemic were searched. Relevant citations were utilized and discussed. **Results:** Hemorrhagic pustules, petechiae, and purpuric lesions developed in a young woman with fever and joint pain. Blood cultures grew beta lactamase negative *Neisseria gonorrhoeae* and the *Neisseria gonorrhoeae/Chlamydia trachomatis* probe was positive for both *N. gonorrhoeae* and *C. trachomatis*. Biopsy revealed bulla with neutrophils, extravasated erythrocytes, fibrin deposits in the vessel walls, and leukocytoclasia. **Conclusion:** Cutaneous lesions of disseminated gonococcal infection can include abscesses, cellulitis, petechiae, purpuric macules, necrotizing fasciitis, and vasculitis. It is important for the clinician to recognize the clinical signs and symptoms of disseminated gonococcal infection, particularly the various cutaneous manifestations.

Keywords: acral skin lesions, cutaneous, disseminated, gonococcal, gonococemia, gonococcus, gonorrhea,

Introduction

Neisseria gonorrhoeae is an aerobic, intracellular diplococcus responsible for approximately 700,000 new cases of sexually transmitted infection (STI) in the United States annually [1]. *N. gonorrhoeae* typically infects the genitourinary tract, but can also invade the conjunctival, oropharyngeal, and rectal mucosa [1-3]. Gonorrhea is second only to chlamydia in bacterial STI prevalence, and the highest incidence of infection occurs in patients ages 15-24 [1, 3-5]. Furthermore, diagnosis is frequently delayed in women as only 50% of cervical infections are symptomatic. From a public health perspective, this serves to further compound the challenge posed to healthcare professionals in controlling transmission [1, 6].

Disseminated gonococcal infection (DGI) is a rare, but dreaded complication of mucosal gonorrheal infection. DGI typically manifests 2-3 weeks after acquiring primary gonococcal infection and affects approximately 0.5-3% of infected individuals [3, 7-9]. The gender prevalence of DGI varies depending on the study design and population characteristics, especially the proportion of participants who are men who have sex with men. One study in France found men to be at higher risk of DGI whereas another study of indigenous Australians reports a higher prevalence of DGI in women [10, 11]. Women and men who have sex with men seem to be at higher physiologic risk of dissemination due to subclinical infection with a compounded susceptibility in women during menstruation and pregnancy [6, 9, 12].

Symptoms of DGI include chills, cutaneous lesions, fever, malaise, migratory polyarthralgia, myalgia, and tenosynovitis [13, 14]. Skin manifestations of DGI are variable; skin lesions are commonly described as nonpruritic, tender macules, papules, or pustules

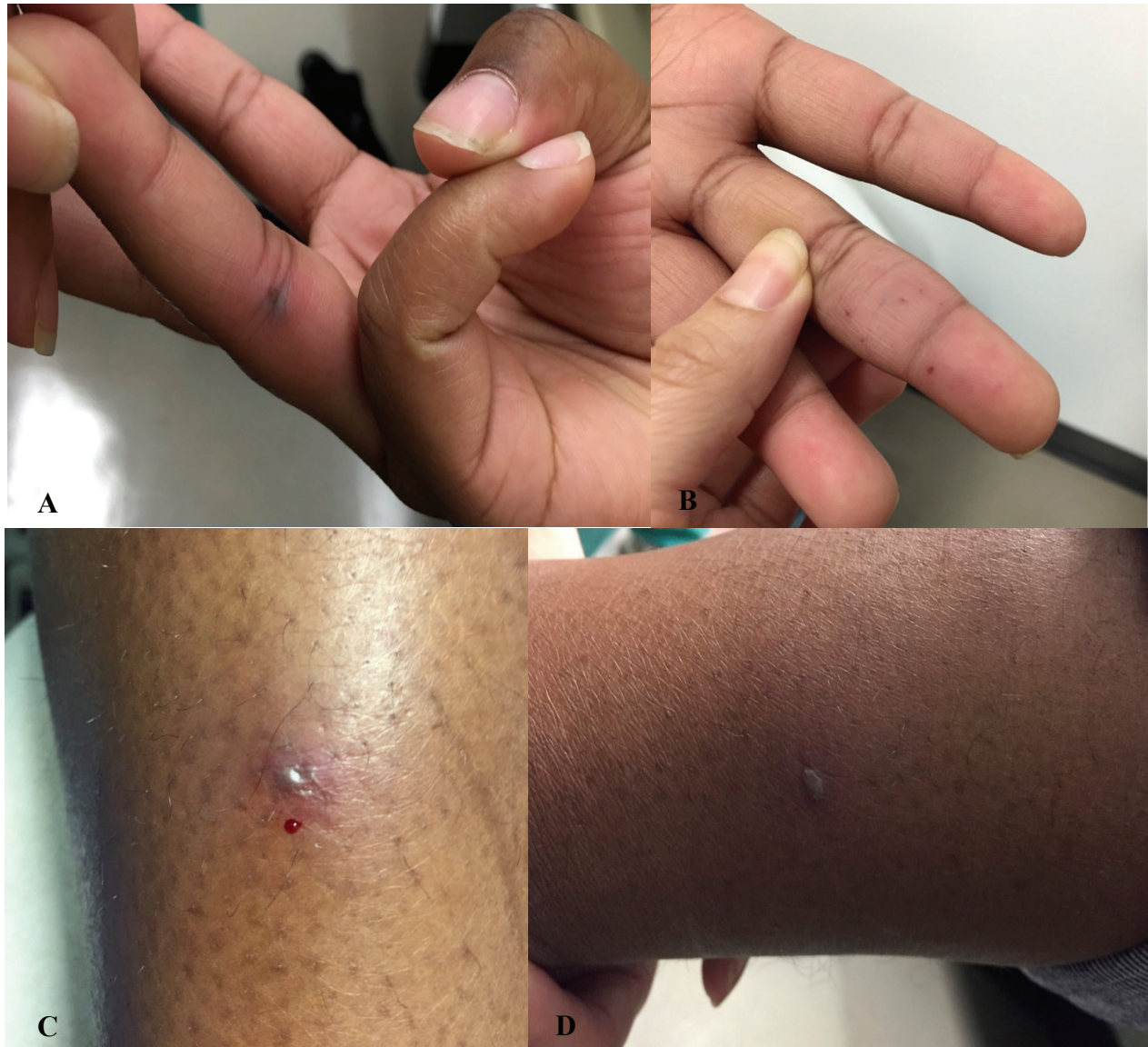

Figure 1. A) Side view of right fourth digit with purpuric papule with surrounding erythema. B) Scattered erythematous to violaceous petechial lesions on left fourth digit. C) Right lower extremity with hemorrhagic pustule with dusky center and peripheral erythema. D) Left lateral shin with hemorrhagic pustule and peripheral erythema.

on a deeply erythematous or hemorrhagic base [12, 15]. In light of the consequence of delayed diagnosis and treatment of DGI, healthcare providers should maintain an index of suspicion and recognize the clinical signs and symptoms associated with this condition. In particular, clinicians should be cognizant of the varying morphologies of cutaneous manifestations of dissemination. We present a case of an 18-year-old woman presenting with low grade fever, sparse hemorrhagic pustules, and joint pain. DGI was entertained and confirmed by blood cultures, skin biopsy, and urine *Neisseria gonorrhoeae/Chlamydia trachomatis* (GC/CT) probe. We go on to describe the clinical features, diagnosis, and treatment of DGI, including discussion of the

various possible cutaneous manifestations that have been reported in the literature.

Case Synopsis

An 18-year-old woman with no significant past medical history presented with a three day history of bilateral elbow pain, fever, painful skin lesions, and sore throat. The patient reported vaginal sexual intercourse with one partner for the past year with intermittent condom use. She denied painful urination, discharge, or genital lesions. Physical exam showed sparse hemorrhagic pustules and purpuric lesions on the palms, lower legs, and soles. Closer examination of the patient's hands revealed acral petechiae and a hemorrhagic, necrotic papule

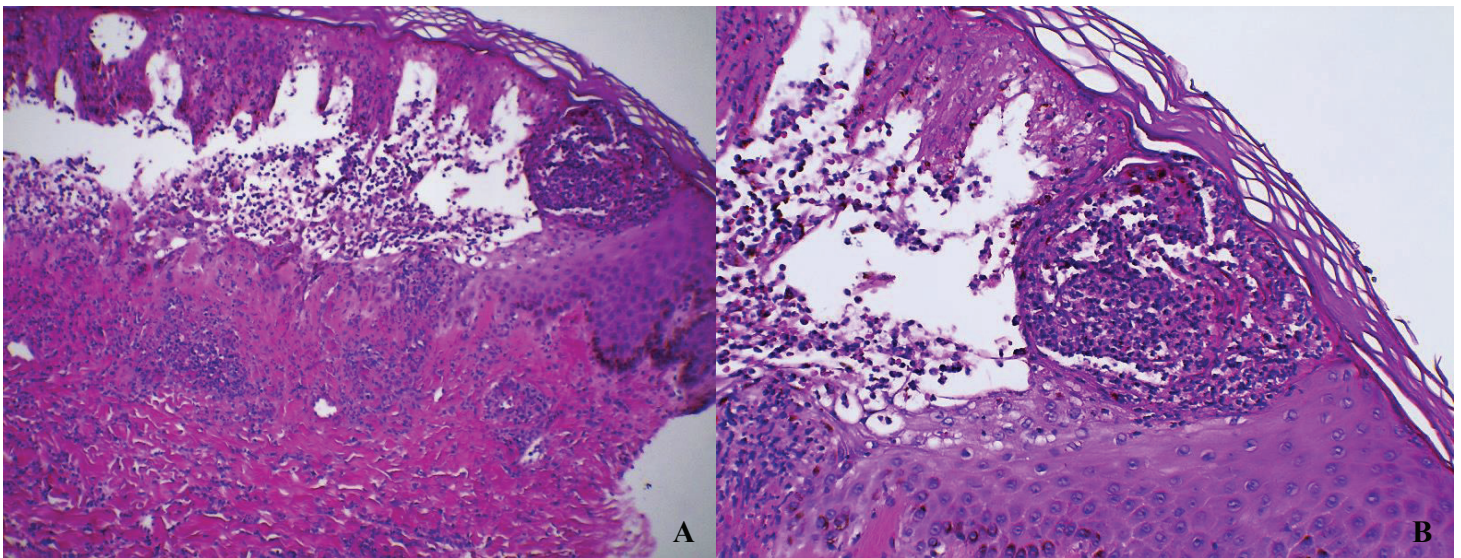


Figure 2. A) 10x magnification. Neutrophilic infiltrate of vascular walls accompanied by nuclear debris (leukocytoclasia), fibrin deposition in the vessel walls, and erythrocyte extravasation. Areas of necrotic epidermis and bulla formation also present. B) 20x. High power view of epidermal necrosis with dense neutrophilic infiltrate and bulla formation. Special stains for fungal (PAS) and bacterial (Gram) organisms were negative.

with a surrounding rim of erythema at the proximal phalangeal joint crease of the right fourth digit (**Figure 1**). Similar hemorrhagic pustules with dusky centers and peripheral erythema could also be found on the lower extremities (**Figure 1**).

The differential diagnosis included disseminated gonococemia (arthritis-dermatitis syndrome), chronic meningococemia, erythema multiforme, Rocky Mountain spotted fever, endocarditis with septic embolization, and secondary syphilis. Punch biopsy of the lower leg was performed and labs were obtained including blood cultures, urine GC/CT probe, rapid plasma reagin test, and antistreptolysin O titer test. Owing to a high suspicion of DGI, the patient was advised to go to the emergency department; however, the patient did not present to the emergency department as directed.

Blood cultures subsequently grew beta lactamase negative *Neisseria gonorrhoeae* and the GC/CT urine probe was positive for both *N. gonorrhoeae* and *C. trachomatis*. Biopsy revealed bulla with neutrophilic infiltrate surrounding blood vessels accompanied by extravasated erythrocytes, fibrin deposit in the vessel walls, and leukocytoclasia (**Figure 2**).

The patient was immediately contacted and instructed to return to the hospital for expeditious treatment of systemic infection. The patient was

treated with 1 gram of Ceftriaxone intramuscularly daily for a total of seven days as well as one dose of 1 gram of Azithromycin orally for treatment of concurrent *Chlamydia* infection. Pharyngeal and vaginal cultures were negative. However, both were obtained more than 48 hours after initiation of antibiotics. The patient made a full recovery with appropriate therapy.

Discussion

DGI is rare and usually affects young women with asymptomatic cervical infections. Young women are at risk owing to the high rate of transmission and lack of symptomology, which increases the likelihood that infections go undiagnosed and remain untreated. Transmission is most efficient from men to women, with an infection rate of 40-60% following a single unprotected sexual encounter with an affected male partner [1, 3, 16]. Fellatio and receptive anal sex can result in oropharyngeal and rectal infections, which are usually asymptomatic in both women and men [1]. Furthermore, the bacteria are capable of systemic invasion with menstruation, pregnancy, and the use of intrauterine devices (IUDs, [13, 16]). Younger patients have a higher rate of infection because of their decreased use of barrier contraceptives, greater number of sexual partners, lack of access to health care, and the physiologic ectopy of their cervical squamocolumnar junction [1]. This population remains at high risk. However, the number of new

Cutaneous Manifestation	Clinical Appearance	References
Abscesses	Submucous periurethral abscess or multiple synchronous distant abscesses (usually in immunocompromised)	[2, 22]
Cellulitis	Multifocal cellulitis that has yet to organize into distinct abscesses	[6]
Macules	Round ill-defined, pink macule with central pinpoint vesiculation	[16]
Necrotizing fasciitis	Severe DGI with associated necrotizing fasciitis requiring multiple debridements and prolonged antibiotic therapy	[20]
Purpura	Purpuric macules up to 2cm in diameter typically on palms and soles and over joints.	[13]
Vasculitis	Extensive, vesiculobullous, hemorrhagic, and necrotic cutaneous vasculitis	[21]
Vesiculopustules	Tiny erythematous macules that evolve into tender vesiculopustules on a deeply erythematous or hemorrhagic base. Usually sparse and found on extremities	[13, 16]

Table 1. Cutaneous Lesions Described in Disseminated Gonococcal Infections [2, 6, 13, 16, 20-22]

N. gonorrhoeae infections is on the rise with a disproportionate increase in other populations such as men who have sex with men [6, 17].

When *N. gonorrhoeae* infects a mucosal site, it triggers an innate immune response resulting in massive neutrophil recruitment. The bacterial surface promotes survival by varying its antigenic structures and inhibiting the binding mechanisms of complement, neutrophils, and opsonic antibodies [1]. Antimicrobial enzymes released by the immune cells disrupt the epithelial integrity, enabling the bacteria to invade the underlying tissue. It has been hypothesized that phagocytized bacteria may use neutrophils as conduits to seed infections at distant sites [1]. The specific method of immune evasion, mucosal penetration, and systemic dissemination is largely determined by the bacterial strain. Strains causing DGI usually harbor the gonococcal specific membrane protein 1A [18]. The formation of cutaneous lesions during bacteremia by any microbe is the result of four distinct pathological mechanisms: vessel wall invasion by bacteria, immune-mediated vasculitis, disseminated intravascular coagulation, and septic embolization followed by microabscess formation [19]. Any combination of these four mechanisms are possible in a single patient.

Arthritis-dermatitis syndrome, a term for the classic

findings of arthritis (present in 86% of DGI cases) and cutaneous lesions (present in 60%) occurring in unison, is primarily a clinical diagnosis [16]. Patients may present with nonspecific symptoms of chills, fever, malaise, and myalgia, but the specific triad of symptoms that characterizes this syndrome is cutaneous lesions, tenosynovitis, and joint disease consisting of migratory asymmetric polyarthralgias or oligoarticular septic arthritis. The cutaneous lesions are usually confined to the extremities and described as tender, sparse papulo-pustules on a hemorrhagic base. Other reported skin manifestations include abscesses, cellulitis, petechiae, purpuric macules, necrotizing fasciitis, and vasculitis ([2,6,13,16,20-22], **Table 1**). Immune impairment should be considered when patients present with severe skin lesions and the clinician should investigate for underlying conditions such as diabetes mellitus, chronic steroid use, and HIV infection [2]. Lesions of DGI can involve the palms and soles; the differential diagnosis can include bacterial endocarditis with septic embolization, chronic meningococemia, erythema multiforme, rat-bite or Haverhill fever, rickettsial disease, and secondary syphilis [3, 23].

Although pustules are thought to be the result of bacterial embolization, cultures tend to be negative and treatment should not be delayed while results are pending [16]. *N. gonorrhoeae* is a fragile organism

that requires unique conditions to grow including a fresh sample, high concentrations of CO₂, and blood agar or Thayer-Martin culture medium [2, 15]. Even so, when DGI is clinically suspected, cultures should be obtained from mucosal sites including the cervix, pharynx, rectum, and urethra [14]. Biopsy of cutaneous lesions reveals thrombi, erythrocyte extravasation, swelling of endothelial cells, and fibrinoid necrosis of vessel walls. Additional findings include a dense neutrophilic infiltrate with leukocytoclasia and possibly bacterial invasion [14, 19]. Another option for patients with negative cultures is the *Neisseria gonorrhoeae*/Chlamydia trachomatis nucleic acid amplification testing assay and urine polymerase chain reaction test which provide greater sensitivity [2, 5, 6, 15, 22].

Growing concern for antibiotic resistance in recent decades has presented a new challenge in treating patients with local and disseminated gonorrheal infections [5, 22]. Currently, the gold standard of treatment for DGI is one gram of ceftriaxone intravenously or intramuscularly daily. This regimen is continued for 24 to 48 hours after improvement of symptoms, at which point the patient should be transitioned to oral cefixime 400 milligrams twice daily for at least one week. Alternative treatment regimens include cefotaxime and ceftizoxime both given as one gram every eight hours. For patients allergic to beta lactams, two grams of spectinomycin intramuscularly every twelve hours provides adequate coverage [5, 13]. Chlamydia infection will exist concomitantly in 10-30% of patients with gonorrhea [24]. Patients should therefore be treated for Chlamydia synchronously with a onetime dose of one gram of azithromycin or 100 milligrams of doxycycline twice per day for seven days.

The Centers for Disease Control and Prevention (CDC) recommends that clinicians take additional precautions in order to curb the growing threat of gonorrhea and other STIs. Sexual partners of patients diagnosed with gonorrhea should be referred for treatment, and all patients diagnosed with reportable STIs should be screened for concurrent infections such as HIV and syphilis [13, 24]. The CDC currently endorses the screening of all sexually active women under the age of 25 annually for gonorrhea. Women over the age of 25 with new or multiple sexual

partners should also receive annual screening [24].

Conclusion

Sexually transmitted infections, including urogenital gonorrheal infection, are a growing health concern in the United States. One of the feared complications of gonococcal infection is systemic dissemination, the risk of which is increased in women in the setting of menstruation, pregnancy, and IUD use. We present the case of an 18-year-old woman presenting with cutaneous signs of DGI confirmed by skin biopsy, urine GC/CT probe, and blood cultures. It is imperative that healthcare providers are educated on the clinical signs and symptoms of this condition, including the various cutaneous manifestations of disseminated gonococcal infection.

References

1. Skerlev, Mihael, and Ivana Čulav-Košćak. "Gonorrhea: new challenges." *Clinics in dermatology* 32.2 (2014): 275-281. [PMID: 24559563]
2. Ho, Y. M., S. J. Sebastin, and A. Y. Lim. "Culture-negative hand abscesses in immunocompetent individuals." *Singapore medical journal* 53.2 (2012): e38-9. [PMID: 22337200]
3. Jain, Sangita, et al. "Disseminated gonococcal infection presenting as vasculitis: a case report." *Journal of clinical pathology* 60.1 (2007): 90-91. [PMID: 17213353]
4. Hook, Edward W., et al. "CDC Grand Rounds: the growing threat of multidrug-resistant gonorrhea." *Morbidity and Mortality Weekly Report* 62 (2013): 103-106. [PMID: 23407126]
5. Kidd, Sarah, and Kimberly A. Workowski. "Management of Gonorrhea in Adolescents and Adults in the United States." *Clinical Infectious Diseases* 61.suppl 8 (2015): S785-S801. [PMID: 26602618]
6. Yoshino, Yusuke, et al. "Multifocal Cellulitis due to Disseminated *Neisseria gonorrhoeae* in a Male Patient." *Journal of clinical medicine research* 6.3 (2014): 215. [PMID: 24734149]
7. Dutertre, M., et al. "Gonococemia mimicking a lupus flare in a young woman." *Lupus* 23.1 (2014): 81-83. [PMID: 24113196]
8. Hagiya, Hideharu, et al. "Disseminated gonococcal infection in an elderly Japanese man." *Internal Medicine* 52.23 (2013): 2669-2673. [PMID: 24292761]
9. Jitmuang, Anupop, et al. "Gonococcal subcutaneous abscess and pyomyositis: a case report." *Case reports in infectious diseases* 2012 (2012). [PMID: 22919521]
10. Belkacem A, et al. Changing patterns of disseminated gonococcal infection in France: cross-sectional data 2009-2011. *Sex Transm Infect.* 2013; 89(8):613-5. [PMID: 23920397]
11. Tuttle CS, et al. The epidemiology of gonococcal arthritis in an Indigenous Australian population. *Sex Transm Infect.* 2015; 91(7):497-501. [PMID: 25792538]
12. Bleich, April T., et al. "Disseminated gonococcal infection in women." *Obstetrics & Gynecology* 119.3 (2012): 597-602. [PMID: 22353959]
13. James, William D., Timothy G. Berger, Dirk M. Elston, and Richard B. Odom. *Andrews' Diseases of the Skin: Clinical Dermatology*. Philadelphia: Saunders Elsevier, 2006. Print.
14. Marks, James G., and Jeffrey J. Miller. *Lookingbill and Marks' principles of dermatology*. Elsevier Health Sciences, 2013. Print.
15. Belkacem, Anna, et al. "Changing patterns of disseminated gonococcal infection in France: cross-sectional data 2009-2011."

- Sexually transmitted infections (2013): *sextrans*-2013. [PMID: 23920397]
16. Mehrany, Khosrow, et al. "Disseminated gonococemia" *International journal of dermatology* 42.3 (2003): 208-209. [PMID: 12653917]
 17. Mendelson, J., et al. "Disseminated gonorrhoea: diagnosis through contact tracing." *Canadian Medical Association Journal* 112.7 (1975): 864. [PMID: 804347]
 18. Taspall J W, Phillips E A, Schultz T R. et al Strain characteristics and antibiotic susceptibility of isolates of *Neisseria gonorrhoea* causing disseminated gonococcal infection in Australia. *Int J STD AIDS* 1992;3:273-327. [PMID: 1504159]
 19. Delgado-Jiménez, Yolanda, et al. "Acute bacterial septic vasculopathy." *International journal of dermatology* 52.9 (2013): 1071-1080. [23231414]
 20. Kanhutu KudzaiNzenza, Spelman DenisD, Weymouth MichaelD. A case of gonococcal necrotising fasciitis. *Sexual Health* 2014; 11: 280-282. [PMID: 25054272]
 21. Mastrolonardo, M., et al. "Cutaneous vasculitis as the sole manifestation of disseminated gonococcal infection: case report." *Genitourinary medicine* 70.2 (1994): 130-131. [PMID: 8206473]
 22. Shaw, Jonathan W., Peter Flegg, and John Sweeney. "Gonococcal tenosynovitis in two HIV-infected heterosexual men: delayed diagnoses following negative urine nucleic acid amplification testing." *International journal of STD & AIDS* (2015): 0956462415585253. [PMID: 25953962]
 23. Ely, John W., and MARY SEABURY Stone. "The generalized rash: part II. Diagnostic approach." *Am Fam Physician* 81.6 (2010): 735-739. [PMID: 20229972]
 24. Miller, Karl E. "Diagnosis and treatment of *Neisseria gonorrhoeae* infections." *American family physician* 73.10 (2006). [PMID: 16734055]