

UC Davis

Dermatology Online Journal

Title

Acitretin for the management of generalized cutaneous lichen planus

Permalink

<https://escholarship.org/uc/item/2m36z4jm>

Journal

Dermatology Online Journal, 20(9)

Authors

Vazirnia, Aria
Cohen, Philip R

Publication Date

2014

DOI

10.5070/D3209023915

Copyright Information

Copyright 2014 by the author(s). This work is made available under the terms of a Creative Commons Attribution-NonCommercial-NoDerivatives License, available at <https://creativecommons.org/licenses/by-nc-nd/4.0/>

Peer reviewed

Case Report

Acitretin for the management of generalized cutaneous lichen planus

Aria Vazirnia MAS¹ and Philip R. Cohen MD²

Dermatology Online Journal 20 (9): 2

¹School of Medicine, University of California San Diego, La Jolla, CA

²Division of Dermatology, University of California San Diego, La Jolla, CA

Correspondence:

Aria Vazirnia, MAS
7218 Rockridge Terrace
West Hills, CA 91307
Email: ariavazir@gmail.com

Philip R. Cohen, MD
10991 Twinleaf Court
San Diego, CA 92131
Email: mitehead@gmail.com

Abstract

Background: Lichen planus is an inflammatory disease that affects the skin, the oral mucosa, or both. Generalized cutaneous lichen planus may pose a therapeutic challenge for clinicians if the condition persists or flares after topical or systemic corticosteroid therapy.

Purpose: Acitretin, a systemic retinoid, can be considered a potential second-line treatment for patients with generalized cutaneous lichen planus. Herein, we describe a postmenopausal woman with generalized cutaneous lichen planus who was successfully treated with acitretin.

Methods: A 58-year-old woman presented with generalized cutaneous lichen planus involving her upper and lower extremities as well as her lower back. After failing corticosteroid therapy, she was started on acitretin 20 mg/day, which was later increased to 30 mg/day. To review the literature on the use of acitretin in cutaneous lichen planus, we used the PubMed search engine and searched for the terms “acitretin” and “cutaneous lichen planus.”

Results: Our patient had complete resolution of pruritus within one week of initiating acitretin 20 mg/day. After an increase in dose to 30 mg/day, the cutaneous lesions completely resolved over a 3-month period. There was no recurrence of disease as acitretin was tapered and discontinued.

Conclusion: Generalized cutaneous lichen planus may pose a therapeutic challenge for the symptomatic relief of skin lesions. Topical and systemic corticosteroids are first-line treatments. In patients who fail corticosteroids, relapse after corticosteroid therapy, or have contraindications to corticosteroids, acitretin may be considered a potential second-line therapy.

Keywords: acitretin, lichen, planus, retinoid, treatment, cutaneous, 13-cis retinoic acid, etretinate, all-trans-retinoic acid

Introduction

Lichen planus is an inflammatory mucocutaneous dermatosis that commonly affects the skin and oral mucosa. Lesions may resolve spontaneously, but various medications can alleviate symptoms and reduce the duration of disease. The management of generalized cutaneous lichen planus usually consists of topical and/or systemic corticosteroids. A woman with recurrent generalized cutaneous lichen planus who was successfully treated with acitretin after failing corticosteroid therapy is described and the use of systemic retinoids in patients with cutaneous lichen planus is reviewed.

Case synopsis

A 58-year-old postmenopausal woman presented for the evaluation of diffuse pruritic skin lesions on her lower extremities, upper extremities, and lower back. The papules and plaques first appeared on her plantar feet one month earlier and then spread to involve her legs, lower back, hands, and wrist. She had no oral lesions and her cutaneous lesions were non-painful. Her past medical history was significant for two prior episodes of generalized cutaneous lichen planus, occurring at ages 7 years and 28 years.

Cutaneous examination was significant for erythematous-to-violaceous flat-topped papules, annular plaques with raised red borders, and hyperpigmented macular patches on the distal and (to a lesser extent) proximal arms and legs, the plantar feet, and the lower back; some of the lesions had a bullous appearance (Figures 1-4). Trachyonychia was also noted on the digits of both hands.

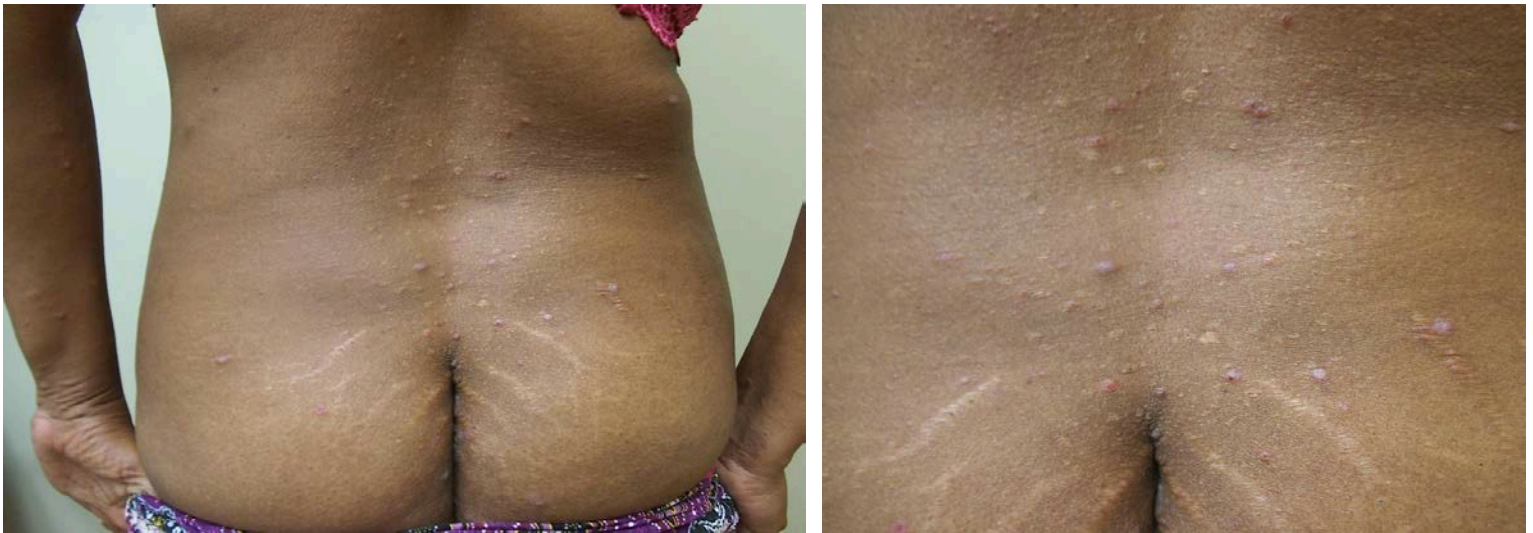

Figure 1 (a and b). Distant (a) and closer (b) views of classic-appearing lichen planus presenting as purple, polygonal, flat-topped plaques on the lower back and buttocks

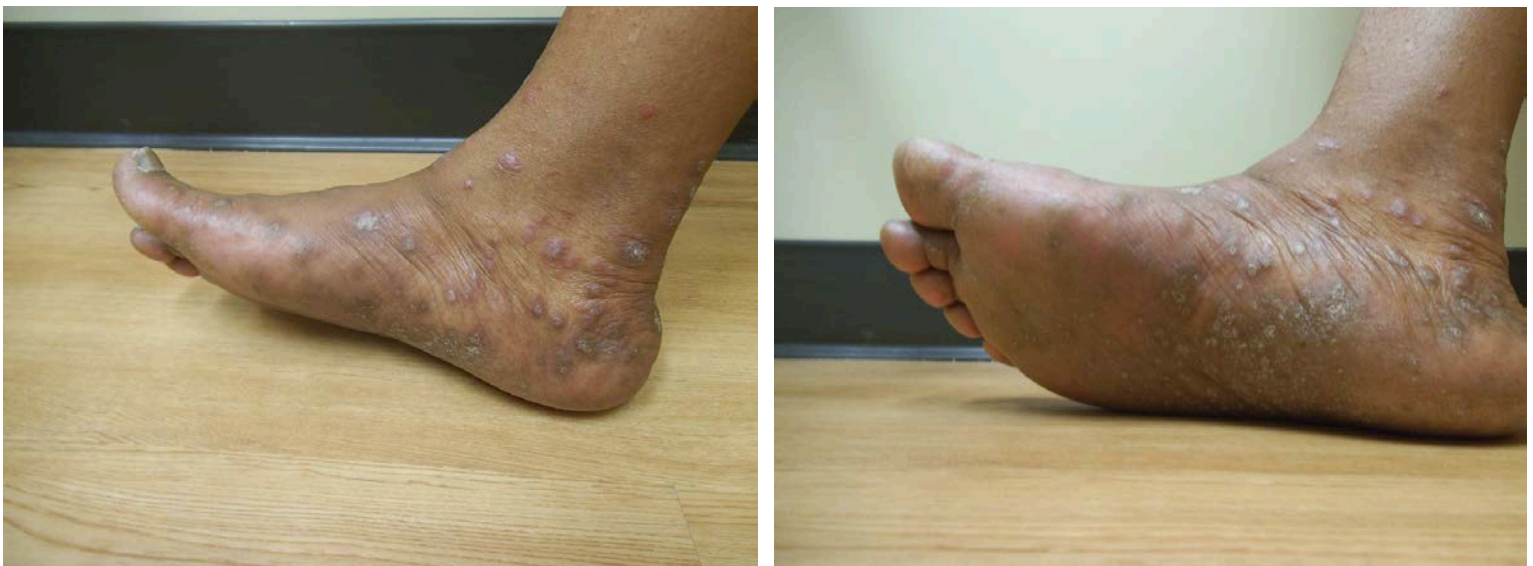

Figure 2 (a and b). Medial (a) and plantar (b) views of the right foot show individual and confluent hyperkeratotic lesions of lichen planus.

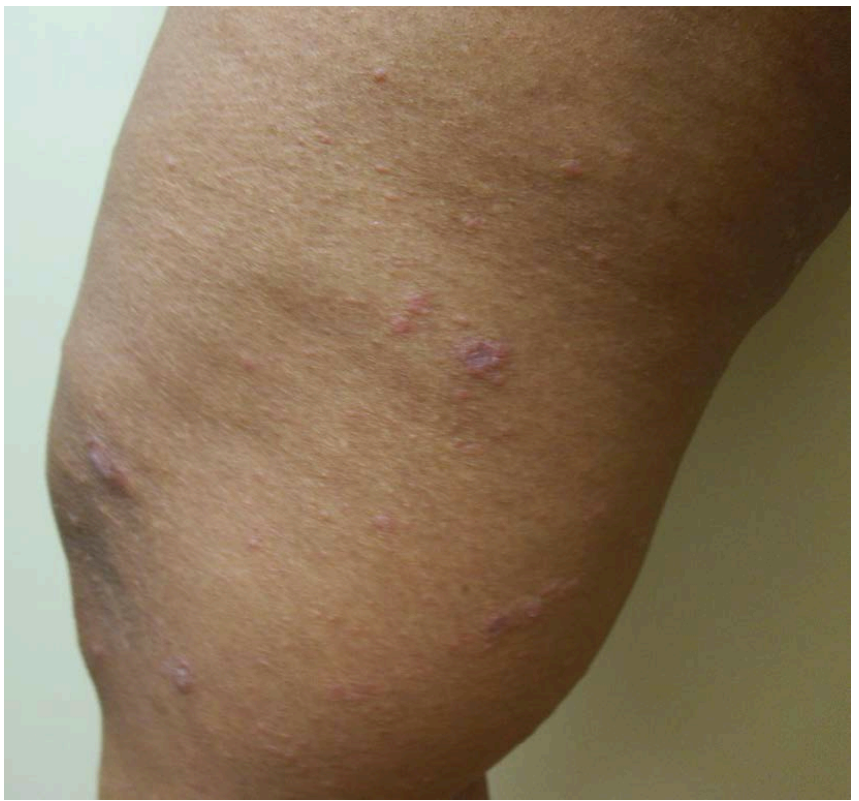
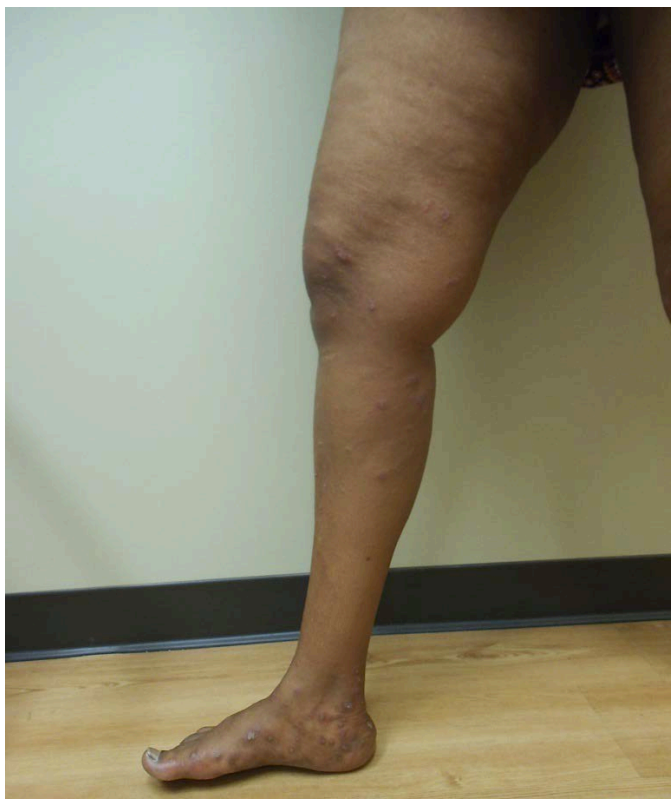
Figure 3 (a and b). Distant (a) and closer (b) views of the right medial leg show annular lesions of lichen planus.

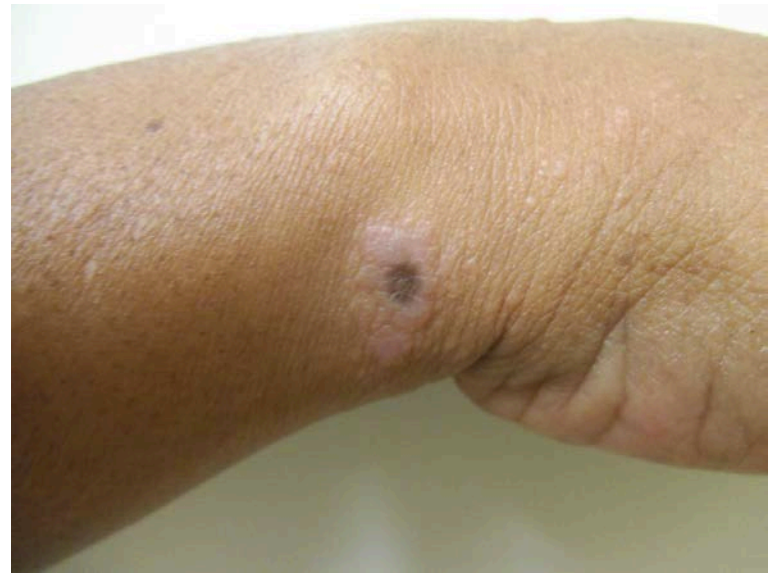
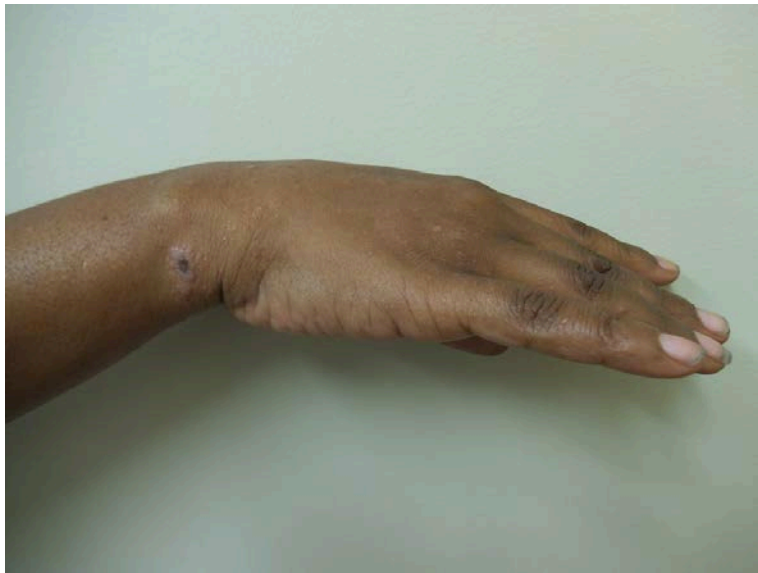
Figure 4 (a and b). Distant (a) and closer (b) views of the right lateral wrist show a bullous lesion of lichen planus with a raised peripheral ring and central necrotic flattened area.

Two lesional skin biopsies were performed. The epidermis showed acanthosis with overlying orthokeratosis, wedge-shaped hypergranulosis with ‘saw tooth-shaped’ rete ridges, and necrotic keratinocytes. A lichenoid lymphocytic infiltrate was present in the superficial dermis and pigment-laden macrophages were present within the papillary dermis (Figure 5). One of the lesions also showed a subepidermal split (Figure 6). Correlation of the clinical presentation and pathologic findings established a diagnosis of generalized cutaneous lichen planus; in addition, several of the lesions were consistent with bullous lichen planus.

A complete blood count, comprehensive metabolic panel, and lipid panel were all within normal limits. A hepatitis viral panel was performed, which was negative for an active or prior infection with the hepatitis A, B, and/or C virus.

The patient was initially treated with oral prednisone (60 mg, 40 mg, and 20 mg, each for one week, consecutively), oral antihistamines (fexofenadine 180 mg each morning and hydroxyzine 20 mg each night), and topical triamcinolone 0.1% ointment (twice and once daily for two weeks and one week, respectively). These interventions reduced the pruritus and partially flattened

the papules and plaques. However, despite corticosteroid therapy, the patient continued to have pruritic annular plaques on the extremities and typical lesions on the back; she further developed hyperkeratotic plaques on the plantar feet. Systemic corticosteroids were discontinued after three weeks because of weight gain and personality changes.

The patient was started on acitretin 20 mg/day. Prior to starting oral retinoid therapy, a pregnancy test was done and shown to be negative. The patient's pruritus completely resolved within one week of acitretin use.

However, after 3 weeks there was only a partial response of her cutaneous lesions to retinoid therapy. Acitretin was increased to 30 mg/day, which led to progressive resolution over 3 months with no relapse in symptoms. Acitretin was then tapered by 10 mg every two weeks until it was finally discontinued, with no recurrence of disease.

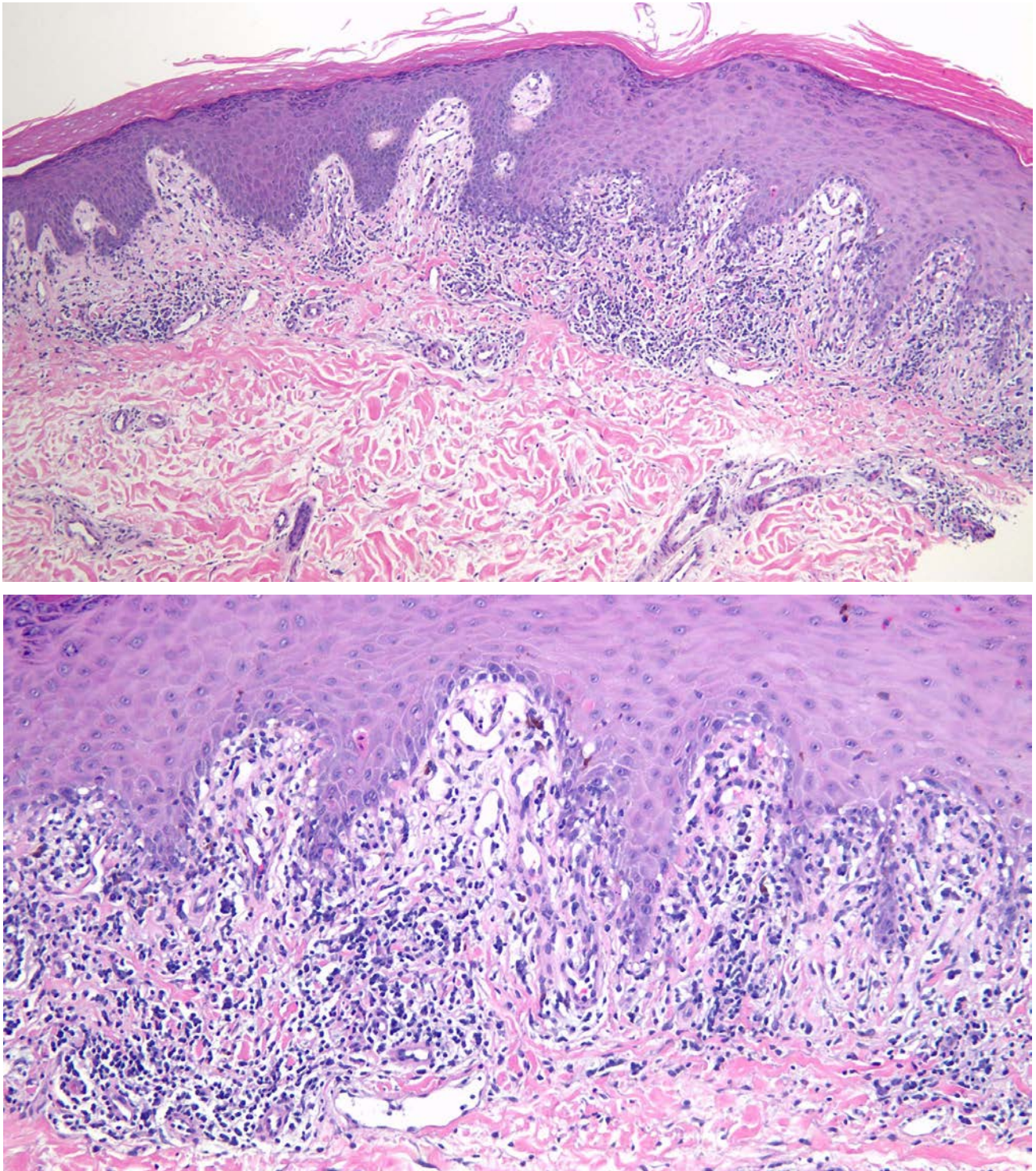


Figure 5 (a and b). Low magnification view (a) shows compact orthokeratosis overlying an acanthotic epidermis. Focally, there is wedge-shaped hypergranulosis in the upper layers of the epidermis. There is 'saw tooth-shaped' elongation of the rete ridges. There is a dense band-like lymphocytic infiltrate in the papillary dermis. Higher magnification view (b) shows necrotic keratinocytes in the lower layers of the epidermis. A dense lichenoid lymphocytic infiltrate is present in the superficial dermis. There is incontinence of pigment into the papillary dermis. (hematoxylin and eosin: a, X10; b, X20)

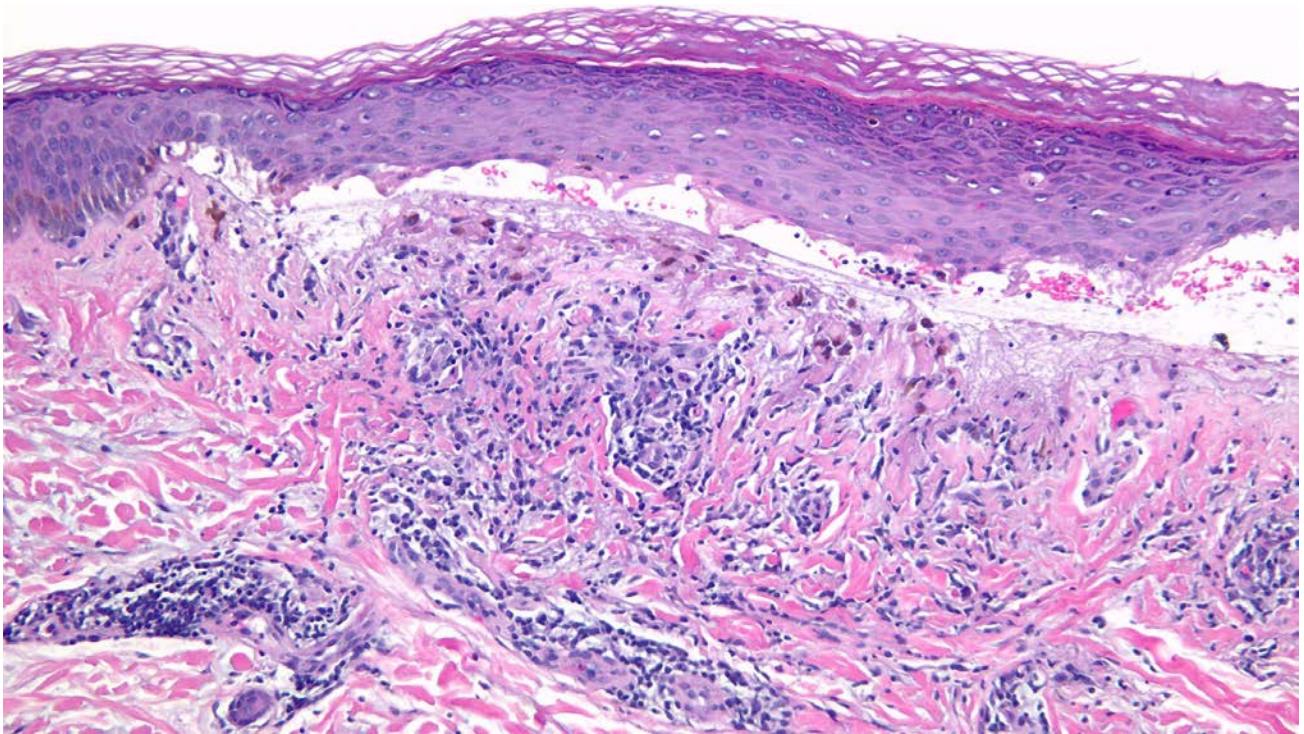
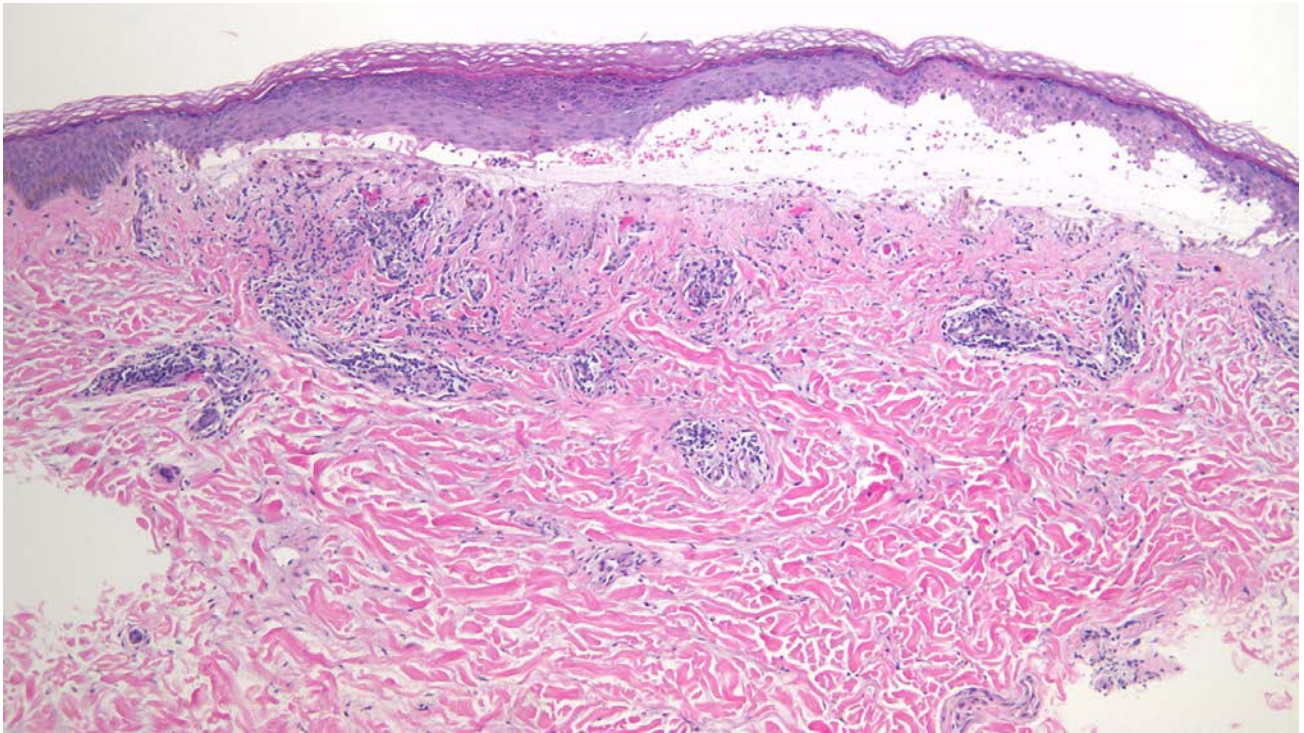


Figure 6 (a and b). Low magnification view (a) shows ‘basket weave’ orthokeratosis overlying the epidermis. There is mild acanthosis and focal hypergranulosis. There is a large cleft between the epidermis and the dermis. There is a band-like lymphocytic infiltrate in the papillary dermis and around the blood vessels in the upper dermis. High magnification view (b) shows necrotic keratinocytes in the epidermis. A prominent Max-Joseph space is present between the epidermis and the dermis; this accounts for the lesions having a bullous appearance. Pigment-laden macrophages are present in the papillary dermis. The lymphocytic infiltrate is not only lichenoid but also perivascular in the upper dermis. (hematoxylin and eosin: a, X10; b, X20)

Discussion

Cutaneous lichen planus is an inflammatory dermatosis. It classically presents as pruritic violaceous polygonal flat-topped papules and plaques [1-3]. The pathogenesis remains unclear but is thought to be an autoimmune phenomenon [2].

The diagnosis of lichen planus is usually clinical. However, microscopic examination of a lesion may be used for confirmation. Pathologic changes typically show a dense band-like lymphohistiocytic infiltrate in the papillary dermis and at the dermal-epidermal junction [3,4]. In addition, epidermal changes include irregular epidermal hyperplasia with sawtoothing of the epidermal rete ridges, orthokeratosis, wedge-shaped hypergranulosis, and liquefactive degeneration of the basal layer [2-4].

Cutaneous lichen planus may spontaneously resolve, often within a year [5,6]. However, the goals of potentially therapeutic interventions are to alleviate pruritus and reduce the duration of cutaneous disease. Management of cutaneous lichen planus often begins with topical corticosteroids; systemic corticosteroid therapy may be used as a second-line treatment. However, a combination of oral and topical corticosteroids may be the first step in patients with generalized cutaneous lichen planus [1,2]. Other topical and systemic therapeutic interventions for cutaneous lichen planus, with variable success, are summarized in Table 1.

Systemic retinoids, such as etretinate, acitretin, all-trans-retinoic acid, and 13-cis-retinoic acid, have demonstrated success in treating cutaneous lichen planus [7-13]. Etretinate is no longer available in many countries; yet its main metabolite, acitretin, has been reported to be effective in the treatment of various dermatoses with hyperkeratosis and scaling [14]. Although teratogenic, acitretin is cleared and eliminated from the body more rapidly than etretinate [15,16]. Viglioglia et al. and Geiger and Czarnetzki were among the first to report the use of acitretin for cutaneous lichen planus; later, Laurberg et al. demonstrated the efficacy of acitretin in a double-blind, randomized-controlled trial with 65 subjects [13,14,17]. Additional reports on the use of acitretin for cutaneous lichen planus are summarized in Table 2.

Based on the above studies, we initiated acitretin in our patient who not only failed corticosteroid therapy, but also developed corticosteroid-induced side effects. Because our patient was postmenopausal and had both a normal lipid panel and liver function tests, we proceeded with systemic retinoid therapy. Similar to reported studies, our patient had prompt relief of her symptoms on acitretin. However, her cutaneous lesions cleared only after the dose was increased to 30 mg/day. There was no recurrence of lichen planus while acitretin was tapered and subsequently discontinued.

Conclusion

Cutaneous lichen planus is an inflammatory disorder that may provide a therapeutic challenge for clinicians. Corticosteroids are the standard of therapy. However, systemic retinoids such as acitretin may be considered in men or postmenopausal women who fail or cannot tolerate corticosteroid therapy.

Appendices

Table 1. Treatment options for cutaneous lichen planus [1,2,4,6-13,18-34]

Drug Class	
Antiepileptics	Immunomodulatory drugs
<i>Phenytoin (p.o.)</i>	<i>Cyclosporine (topical, p.o.)</i>
Antifungals	<i>Mycophenolate mofetil (p.o.)</i>
<i>Griseofulvin (p.o.)</i>	<i>Thalidomide (p.o.)</i>
<i>Itraconazole (p.o.)</i>	Low-Molecular-Weight Heparin (LMWH)
Biologics	<i>Enoxaparin Sodium (s.c.)</i>
<i>Alefacept (I.M.)</i>	Photochemotherapy
<i>Anakinra (s.c.)</i>	<i>Narrow-band UVB therapy</i>
<i>Efalizumab (s.c.)</i>	<i>PUVA (Psoralen + UVA)</i>
Cytotoxic Agents	Retinoids
<i>Azathioprine (p.o.)</i>	<i>Acitretin (p.o.)</i>
<i>Methotrexate (p.o.)</i>	<i>All-trans-retinoic acid (p.o.)</i>
Glucocorticoids	<i>13-cis-retinoic acid (p.o.)</i>
<i>Betamethasone dipropionate (topical)</i>	<i>Etretinate (p.o.)</i>
<i>Clobetasol propionate (topical)</i>	<i>Isotretinoin lotion or gel (topical)</i>
<i>Fluocinolone acetonide (topical)</i>	<i>Retinoic acid lotion or gel (topical)</i>
<i>Prednisolone (p.o.)</i>	
<i>Triamcinolone acetonide (topical, IM)</i>	

Abbreviations: IM = intramuscular injection; mg/kg = milligram per kilogram; p.o. = oral administration; s.c.= subcutaneous injection; UVA = ultraviolet A; UVB = ultraviolet B

Table 2. Acitretin for treatment of cutaneous lichen planus.

Study Design	Year	# treated with acitretin	Dose	Follow-up	Response	Adverse effects	Ref.
Multiple trial designs (open and double-blind studies)	1988	635 subjects with psoriasis or other dermatoses enrolled; 518 subjects treated with acitretin for psoriasis or other dermatoses; 5 subjects with lichen planus treated with acitretin	20-50 mg/day	3-4 months	3 out of 5 subjects treated with acitretin had remission or marked improvement of symptoms	<i>All subjects with dermatoses treated with acitretin:</i> dry lips, cheilitis, dry mouth, dry nose, rhinitis sicca, dry skin, dry eyes, conjunctivitis, scaling, hairloss, nail changes	14
Open-label trial; 2 Tx phases	1990	11 subjects treated with acitretin; 8 completed the study	30 mg/day (1 st Tx phase) 10-20 mg/day (2 nd Tx phase)	1st Tx phase: 8 wks 2 nd Tx phase: 8 wks Total: 16 wks	Complete remission or significant improvement in 75% of patients who completed study	Acitretin stopped in 2 patients because of severe adverse reactions (not specified)	17
RCT	1991	65 subjects enrolled; 32 treated with acitretin	30 mg/day	8 wks	Significant improvement in pruritus, papulosis, and erythema in acitretin group versus placebo group	Dry lips, dry mouth, dry nose, dry eyes, dry skin, scaling, hair loss, nail fragility	13
Case report	1996	1 subject	35-50 mg/day	12 wks	Flattening of lesions	Mild cheilitis	36
Case report	2000	1 subject	25 mg/day	2 wks	All lesions flattened; pruritus significantly reduced	None	35
Case report	2014	1 subject	Initially 20 mg/day, then 30 mg/day	3 months	Pruritus reduced <1 week; skin lesions resolved in 3 months	None	CR

Abbreviations: CR = current report; mg/day = milligrams per day; N/A = not available; RCT = Randomized Controlled Trial; Ref = References; Tx = Treatment; wks = weeks

References

- Sharma A, Bialynicki-Birula R, Schwartz RA, Janniger CK: Lichen planus: an update and review. *Cutis* 2012;90:17-23.
- Le Cleach L, Chosidow O: Lichen planus. *N Engl J Med* 2012;366:723-732.
- Gorouhi F, Davari P, Fazel N: Cutaneous and mucosal lichen planus: a comprehensive review of clinical subtypes, risk factors, diagnosis, and prognosis. *ScientificWorldJournal* 2014;742826
- Lehman JS, Tollefson MM, Gibson LE: Lichen planus. *Int J Dermatol* 2009;48:682-694.
- Usatine RP, Tinitigan M: Diagnosis and treatment of lichen planus. *Am Fam Physician* 2011;84:53-60.
- Asch S, Goldenberg G: Systemic treatment of cutaneous lichen planus: an update. *Cutis* 2012;90:17-23.
- Günther S: Lichen ruber planus and lichen ruber verrucosus of the skin: therapeutic results using vitamin A acid in 98 patients. *Z Hautkr* 1975;50:59-68.
- Woo TY: Systemic isotretinoin treatment of oral and cutaneous lichen planus. *Cutis* 1985;35:385-393.
- Schuppli R: The efficacy of a new retinoid (Ro 10-9359) in lichen planus. *Dermatologica* 1978;157:60-63.

10. Ebner H: Results of systemic treatment of lichen planus with a new aromatic retinoid (RO 10-9359). *Wien Klin Wochenschr* 1979;91:161-164.
11. Viglioglia PA: Therapeutic evaluation of the oral retinoid Ro 10-9359 in several non-psoriatic dermatoses. *Br J Dermatol* 1980;103:483-487.
12. Mahrle G, Meyer-Hamme S, Ippen H: Oral treatment of keratinizing disorders of skin and mucous membranes with etretinate. Comparative study of 113 patients. *Arch Dermatol* 1982;118:97-100.
13. Laurberg G, Geiger JM, Hjorth N, Holm P, Hou-Jensen K, Jacobsen KU, Nielsen AO, Pichard J, Serup J, Sparre-Jorgensen A, Sorensen D, Thestrup-Pedersen K, Thomsen K, Unna P, Urup J: Treatment of lichen planus with acitretin. *J Am Acad Dermatol* 1991;24:434-437.
14. Geiger JM, Czarnetzki BM: Acitretin (Ro 10-1670, etretin): overall evaluation of clinical studies. *Dermatologica* 1988;176:182-190.
15. Paravicini U, Camenzind M, Gower M, Geiger JM, Saurat JH: Multiple dose pharmacokinetics of Ro 10-1670, the main metabolite of etretinate (Tigason). *Retinoids: new trends in research and therapy*. Karger 1985:189-292.
16. Brindley CJ: Overview of recent clinical pharmacokinetic studies with acitretin (Ro 10-1670, etretin). *Dermatologica* 1989;178:79-87.
17. Viglioglia PA, Villanueva CR, Martorano AD, Cahuepé AM, Traballi CA, Geiger JM: Efficacy of acitretin in severe cutaneous lichen planus. *J Am Acad Dermatol* 1990;22:852-853.
18. Sehgal VN, Abraham GJ, Malik GB: Griseofulvin therapy in lichen planus. A double-blind controlled trial. *Br J Dermatol* 1972;87:383-385.
19. Massa MC, Rogers RS 3rd: Griseofulvin therapy of lichen planus. *Acta Derm Venereol* 1981;61:547-550.
20. Büyük AY, Kavala M: Oral metronidazole treatment of lichen planus. *J Am Acad Dermatol* 2000;43:260-262.
21. Moura AK, Moure ER, Romiti R: Treatment of cutaneous lichen planus with thalidomide. *Clin Exp Dermatol* 2009;34:101-103.
22. Bogaert H, Sanchez E: Lichen planus: treatment of thirty cases with systemic and topical phenytoin. *Int J Dermatol* 1990;29:157-158.
23. Chopra A, Mittal RR, Kaur B: Dapsone versus corticosteroids in lichen planus. *Indian J Dermatol Venereol Leprol* 1999;65:66-68.
24. Lear JT, English JS: Erosive and generalized lichen planus responsive to azathioprine. *Clin Exp Dermatol* 1996;21:56-57.
25. Böhm M, Luger TA: Lichen planus responding to efalizumab. *J Am Acad Dermatol* 2007;56:S92-93.
26. Bauzá A, España A, Gil P, Lloret P, Vázquez Doval FJ: Successful treatment of lichen planus with sulfasalazine in 20 patients. *Int J Dermatol* 2005;44:158-162.
27. Higgins EM, Munro CS, Friedmann PS, Marks JM. Cyclosporin A in the treatment of lichen planus. *Arch Dermatol* 1989;125:1436.
28. Hodak E, Yosipovitch G, David M, Ingber A, Chorev L, Lider O, Cahalon L, Cohen IR: Low-dose low-molecular-weight heparin (enoxaparin) is beneficial in lichen planus: a preliminary report. *J Am Acad Dermatol* 1998;38:564-568.
29. Akdeniz S, Harman M, Atmaca S, Yaldiz M: The management of lichen planus with low-molecular-weight heparin (enoxaparin). *Int J Clin Pract* 2005;59:1268-1271.
30. Fivenson DP, Mathes B: Treatment of generalized lichen planus with alefacept. *Arch Dermatol* 2006;142:151-152.
31. Turan H, Baskan EB, Tunalı S, Yazici S, Sarıcaoglu H: Methotrexate for the treatment of generalized lichen planus. *J Am Acad Dermatol* 2009;60:164-166.
32. Libow LF, Coots NV: Treatment of lichen planus and lichen nitidus with itraconazole: reports of six cases. *Cutis* 1998;62:247-248.
33. Cohen PR, Kurzrock R: Anakinra-responsive lichen planus in a woman with Erdheim-Chester disease: a therapeutic enigma. *Dermatol Online J* 2014;20:21241.
34. Boyd AS, Cohen PR: Annular lesions in a black woman. Annular lichen planus (LP). *Arch Dermatol* 1996;132:1106-1107,1109-1110.
35. Pandhi RK, Mittal R, Khaitan KB: Lichen planus treated with acitretin (1e). *Indian J Dermatol Venereol Leprol* 2000;66:330-331.
36. De Jong EM, Van De Kerkhof PC: Coexistence of palmoplantar lichen planus and lupus erythematosus with response to treatment using acitretin. *Br J Dermatol* 1996;134:538-541.