

# UC Davis

## Dermatology Online Journal

### Title

A case of eosinophilic dermatosis of hematologic malignancy in a patient with multiple myeloma

### Permalink

<https://escholarship.org/uc/item/2872w38m>

### Journal

Dermatology Online Journal, 20(1)

### Authors

Two, Aimee M  
Li, Chao  
Hata, Tissa

### Publication Date

2014

### DOI

10.5070/D3201021256

### Copyright Information

Copyright 2014 by the author(s). This work is made available under the terms of a Creative Commons Attribution-NonCommercial-NoDerivatives License, available at <https://creativecommons.org/licenses/by-nc-nd/4.0/>

Peer reviewed

**Photo vignette**

**A case of eosinophilic dermatosis of hematologic malignancy in a patient with multiple myeloma**

**Aimee M. Two, Chao Li, Tissa Hata**

**Dermatology Online Journal 20 (1): 15**

**<sup>1</sup>Division of Dermatology, University of California San Diego, San Diego, CA**

**Correspondence:**

Tissa Hata  
University of California San Diego  
Division of Dermatology  
8899 University Center Lane  
Suite 350  
San Diego, CA 92122  
thata@mail.ucsd.edu

**Abstract**

A 50-year-old man with eosinophilic dermatosis of hematologic malignancy is presented. His dermatosis cleared after chemotherapy produced improved control of his multiple myeloma.

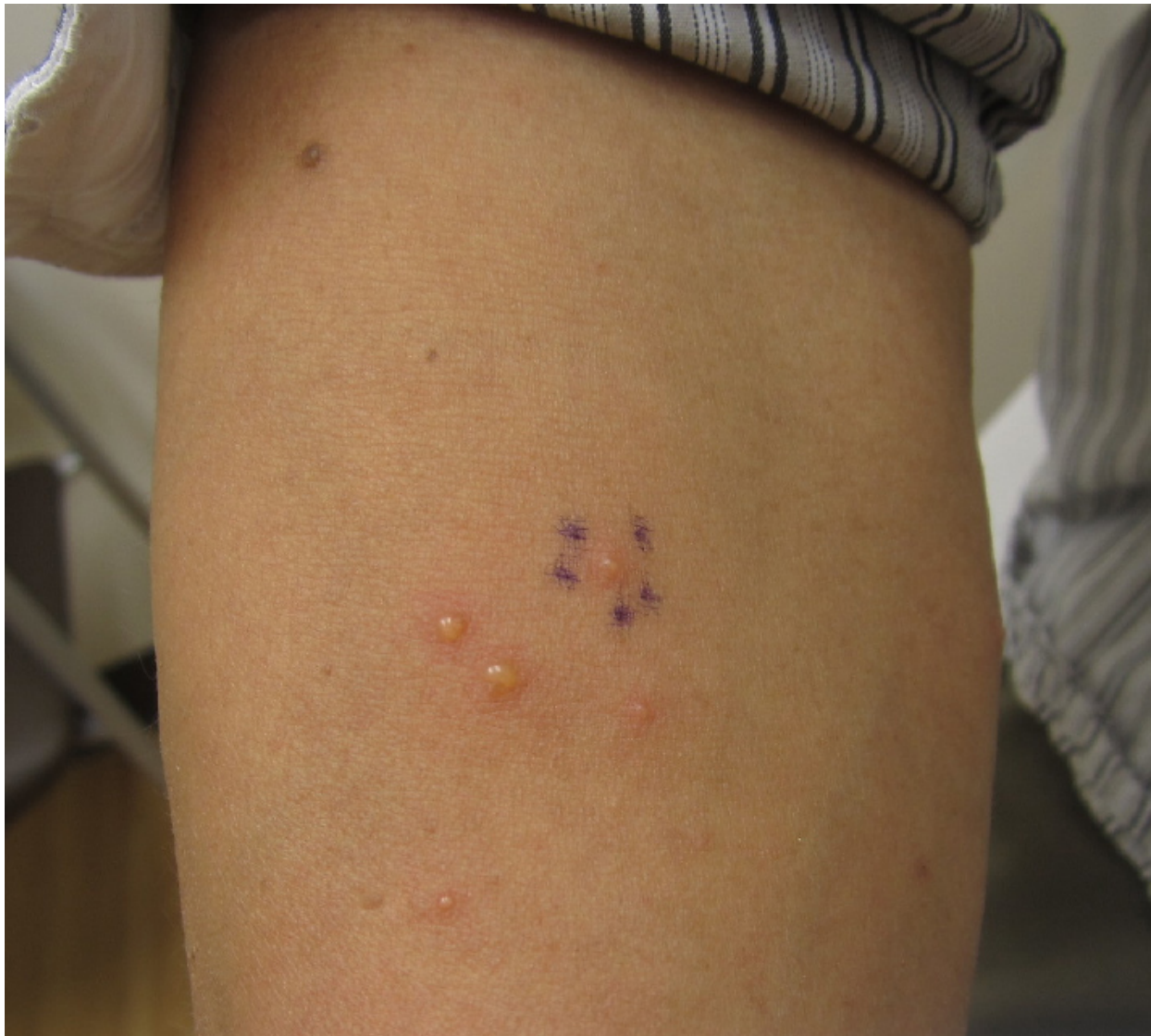
**Keywords: Eosinophilic dermatosis, Insect bite-like reaction, Hematologic malignancies**

**Introduction**

Eosinophilic dermatosis of hematologic malignancy is most common in chronic lymphocytic leukemia (CLL) patients ages 50 to 70 [1]. Since its first description in the literature in 1965, over 40 cases of this condition have been described in patients with CLL as well as with other hematologic malignancies, including acute myelocytic leukemia, acute lymphocytic leukemia, and mantle cell lymphoma, but not yet in multiple myeloma. In the following case we describe the first reported case of eosinophilic dermatosis of hematologic malignancy occurring in a patient with multiple myeloma.

**Case synopsis**

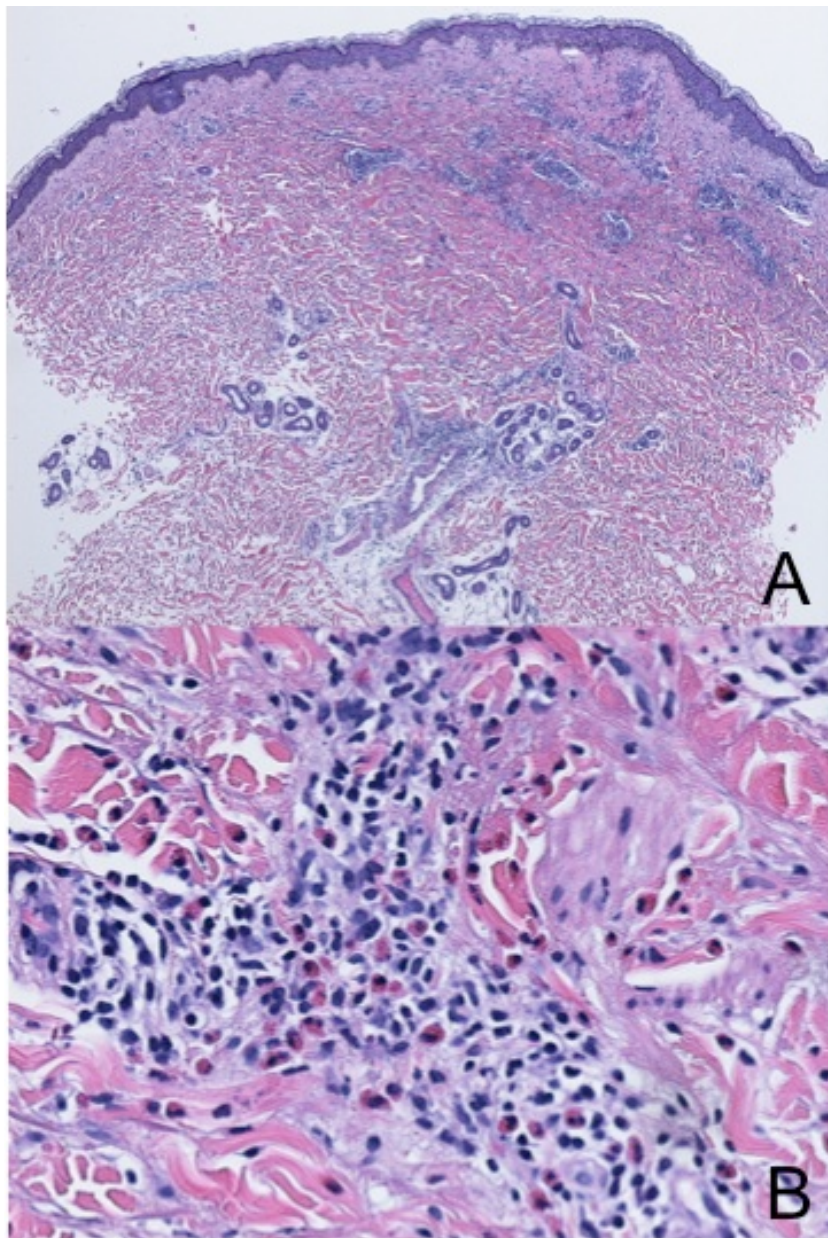
A 50 year-old man previously diagnosed with multiple myeloma presented for evaluation of multiple pruritic, grouped vesicles on his right forearm, left lower extremity and left trunk. The patient had presented three months earlier with similar-appearing lesions on his left arm that resolved over the course of a week with the application of topical fluocinonide cream twice daily. He remained free from skin lesions until the onset of his current vesicles, which he noticed 1 month prior to presentation. The vesicles had remained stable in appearance since that time. He denied any recent insect bites and had not had contact with anyone with similar lesions. In addition to his one-year history of multiple myeloma, which was treated with an autologous bone marrow transplant ten months prior, the patient's past medical history was significant for chronic hepatitis B and a herpes zoster infection. He denied any personal or family history of eczema or atopy. He remains on acyclovir as prophylaxis against future herpes virus outbreaks and was started on bimonthly infusions of bortezomib the day prior to his current presentation in response to gradually rising M-protein levels. His other medications on initial presentation included entecavir for one year and daily pyridoxine (vitamin B6), cyanocobalamin (vitamin B12), and a multivitamin.



**Figure 1.** Eosinophilic dermatosis of hematologic malignancy. Patient's right forearm showing multiple small vesicles on an erythematous base. Similar lesions were seen on patient's left leg and trunk.

Physical exam revealed a group of three vesicles on an erythematous base on his right forearm (Figure 1) and similar lesions on his left trunk and left leg. The clinical differential diagnosis at this point included arthropod assault, atypical disseminated herpes zoster, herpes simplex, and bullous pemphigoid. Varicella-zoster direct fluorescent antibody was negative and no organisms were seen on gram stain taken from one of the lesions. An enzyme-linked immunosorbent assay for the bullous pemphigoid IgG antibodies BP 180 and BP 230 was negative. A punch biopsy of a vesicle on the right forearm showed a normal basket weave stratum corneum with a superficial and deep mixed perivascular infiltrate consisting of lymphocytes and prominent eosinophils, with eosinophils in the interstitial space, consistent with acute spongiotic dermatitis (Figure 2). Given the patient's history and pathology findings, his diagnosis seems most consistent with eosinophilic dermatosis of hematologic malignancy. He was prescribed a topical steroid for symptomatic relief and the importance of continued follow-up with oncology for optimization of his chemotherapy was stressed.

On follow-up six weeks later, the patient's vesicles had disappeared. His skin showed a slight hyperpigmentation where his lesions were previously located. However no vesicles were present. He remained on bortezomib and had also started carfilzomib and dexamethasone infusions for further multiple myeloma control. Given other case reports of eosinophilic dermatosis of hematologic malignancy improving with chemotherapy and intravenous corticosteroids, these medications likely contributed to clearing his lesions. The patient had already discontinued use of his topical steroid and was told to follow-up as needed.



**Figure 2.** Eosinophilic dermatosis of hematologic malignancy. Hematoxylin and Eosin staining of a punch biopsy specimen taken from one of the patient's right forearm lesions. (A) Histology shows a normal basket weave stratum corneum with a superficial and deep mixed perivascular infiltrate. (B) A close-up of the infiltrate shows lymphocytes and eosinophils, with eosinophils also seen in the interstitial space.

## References

1. Farber MJ, La Forgia S, Sahu J, Lee JB. *Eosinophilic dermatosis of hematologic malignancy*. J Cutan Pathol. 2012; 39(7): 690-5. [PMID: 22612903]