

# UC Davis

## Dermatology Online Journal

### Title

Vestibular papillomatosis as a normal vulvar anatomical condition

### Permalink

<https://escholarship.org/uc/item/2429w0sx>

### Journal

Dermatology Online Journal, 19(10)

### Authors

Diaz Gonzales, Jose Manuel  
Martinez Luna, Eduwiges  
Pena Romero, Adriana  
et al.

### Publication Date

2013

### DOI

10.5070/D31910020032

### Copyright Information

Copyright 2013 by the author(s). This work is made available under the terms of a Creative Commons Attribution-NonCommercial-NoDerivatives License, available at <https://creativecommons.org/licenses/by-nc-nd/4.0/>

Peer reviewed

**Case Presentation**

**Vestibular papillomatosis as a normal vulvar anatomical condition**

**Jose Manuel Diaz Gonzales MD, Eduwiges Martinez Luna MD, Adriana Pena Romero, Alma Molina Hernandez, Judith Dominguez Cherit MD**

**Dermatology Online Journal 19 (10): 12**

**National Institute of Medical Sciences and Nutrition “Dr. Salvado Zubiran”**

**Correspondence:**

Jose Manuel Diaz Gonzales MD  
National Institute of Medical Sciences and Nutrition “Dr. Salvado Zubiran”  
Tlalpan, Mexico City, Mexico

**ABSTRACT**

At the beginning of the nineteen-eighties, vulvar vestibular papillomatosis (VVP) was thought to be a human papilloma virus (HPV) disease. Based upon these findings many clinicians have been treating this condition with laser ablation or by topical application of podophyllin or trichloroacetic acid.

Currently, most authors believe that VVP should be considered an anatomical variant of the vestibular mucosa and not HPV related. We present a case of VVP in which there was no histological or molecular evidence of HPV; unnecessary treatment should be avoided.

**INTRODUCTION**

The etiology and clinical significance of vulvar vestibular papillomatosis (VVP) is still controversial; in the past it was considered to be a result of human papilloma virus (HPV) infection, but actually, there are many studies that show only a rare relationship between VVP and HPV [1,2,3,4]. Currently, VVP is considered as an anatomical variant of the vulva [5]. In a prominent study done in London, only one percent of women showed vestibular papillomatosis although other authors have found a prevalence between 5.1 to 33% [6].

**CASE synopsis**

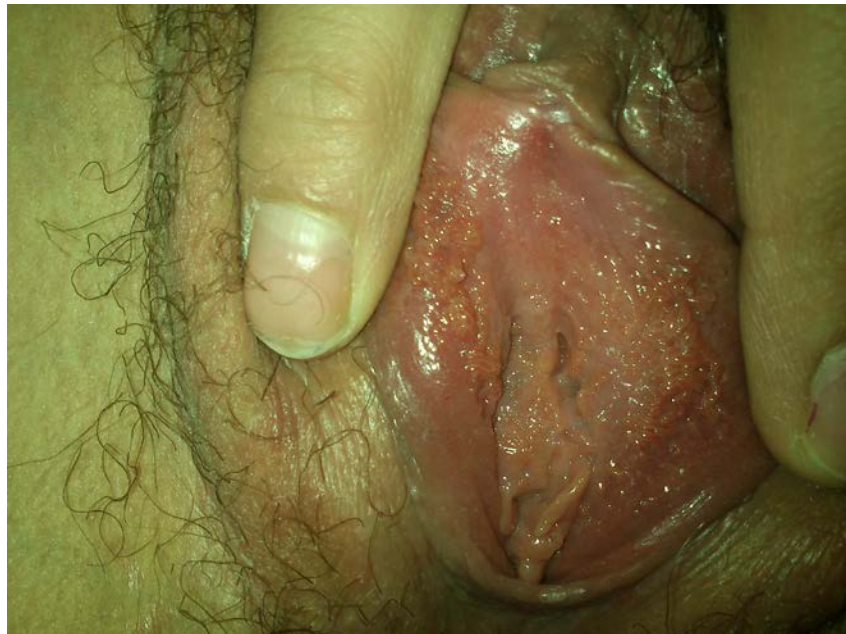

Figure 1: multiple vulvar papillomas

A 24-year-old woman presented with a one-month history of asymptomatic papules on the vulva. She noted these lesions after intercourse with her partner. She had been previously treated unsuccessfully for condylomata. Upon physical examination, we observed on the inner aspects of her labia minora many flesh-colored, soft, pearly and filiform lesions, which were 1 to 2 mm in diameter. (Figure 1)

A biopsy was performed showing multiple finger-like projections with rounded tips and individual thin bases. There is a normal epidermis overlying a central loose fibrovascular core; no koilocytes were seen and the diagnosis of vulvar vestibular papillomatosis was confirmed. Condylomata acuminatum is the most likely entity in the histological differential diagnosis. However, the keratotic pointed tips and fused bases differentiates condylomata from VVP. (Figure 2)

The PCR technique was negative for HPV.

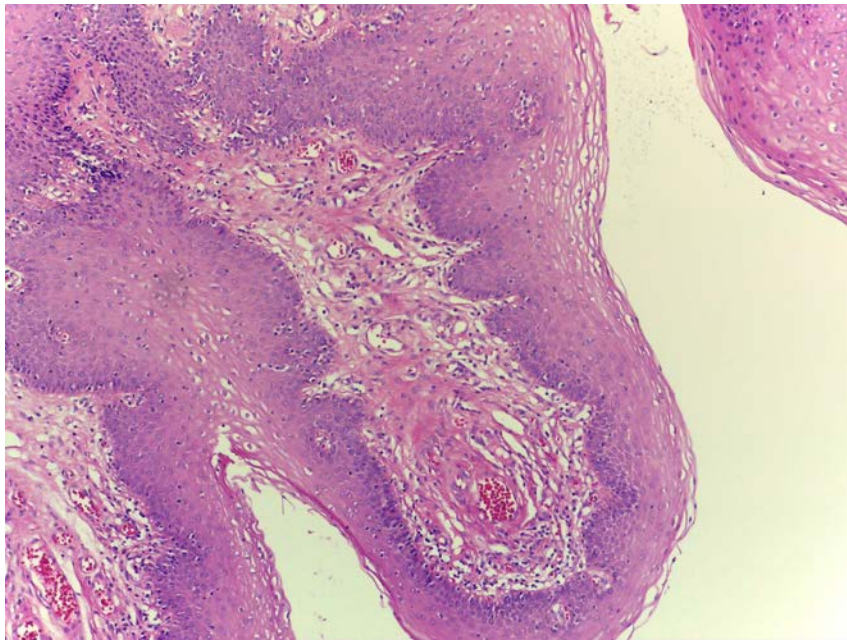


Figure 2.

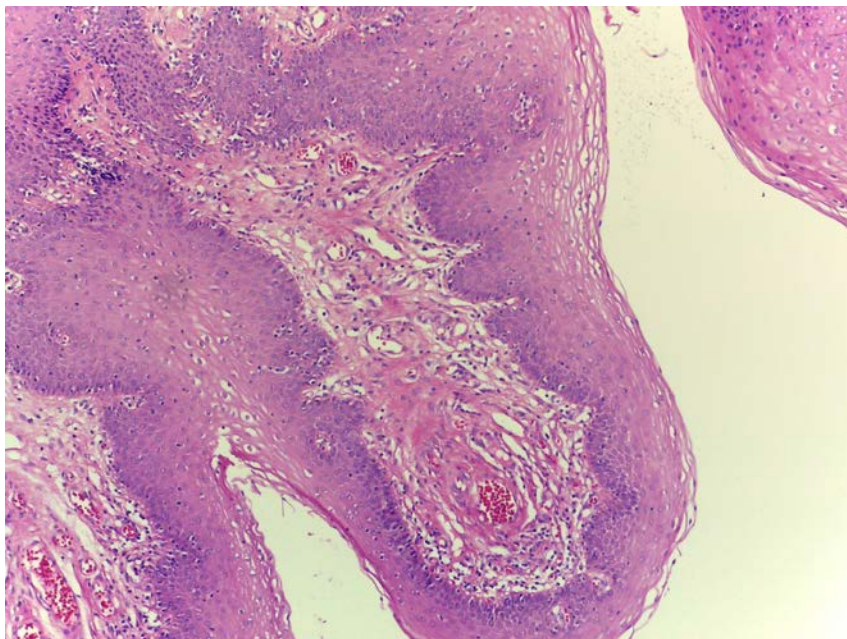


Figure 3.



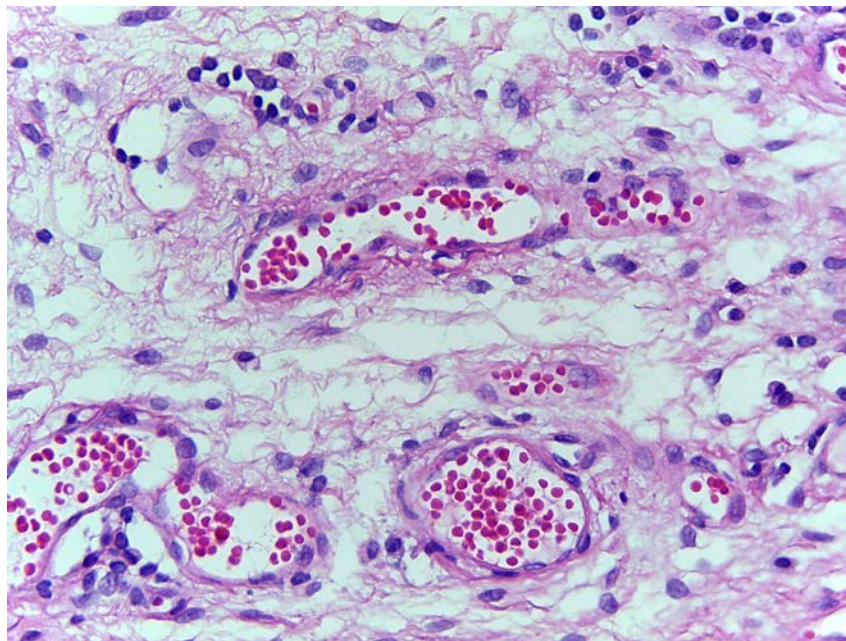


Figure 4.

Figures 2,3,4: Multiple finger-like projections with rounded tips and individual thin bases are present. There is a normal epidermis overlying a central loose fibrovascular core; no koilocytes were seen.

## DISCUSSION

VVP was first recognized in 1981. Altmeyer described these lesions as small, smooth projections of the vulvar mucosa and named them pseudocondylomata of the vulva because of the similar appearance with condyloma acuminatum [7]. In 1987 Campion [8] described three types of subclinical vulvar lesions, one of which was the vestibular papillae, thought to be associated with HPV infection. A few years later, in 1991, the report by the International Society for the Study of Vulvar Diseases (ISSVD) described papillomatosis of the vulvar vestibule as the presence of multiple papillae that may cover the mucosal surface of the labia minora [9]. Since then, VVP has been reported under a variety of names: vestibular papillae, hirsutoid papillomas of vulvae, vulvar squamous papillomatosis, micropapillomatosis labialis, and many others [10]. VVP has been seen with HPV infection, but a consistent association has not been proven. Therefore, most recent studies consider VVP as a normal variant in the vulvar vestibule architecture, not directly related to infection by HPV [11]. It is likely that this finding is a female counterpart of male pearly penile papules [12].

## CONCLUSION

In our opinion, physicians must be cautious when treating VVP. We want to call attention to this frequent, but often unrecognized, entity in order to assure the correct diagnosis and avoid repeated and unnecessary treatments of the normal genital anatomic variant.

## REFERENCES

1. Ivanov S, Khadzhilov N, Ivanov S. The relationship between vulvar micropapillomatosis and HPV infection. *Akush Ginecol (Sofia)*. 2003;42 Suppl 1:8-10. [PMID: 12858494]
2. de Deus JM, Focchi J, Stávale JN, de Lima GR. Histologic and biomolecular aspects of papillomatosis of the vulvar vestibule in relation to human papillomavirus. *Obstet Gynecol*. 1995 Nov; 86(5):758-63. [PMID: 7566844]
3. Gentile G, Formelli G, Pelusi G, Flamigni C. Is vestibular micropapillomatosis associated with human papillomavirus infection? *Eur J Gynaecol Oncol*. 1997;18(6):523-5. [PMID: 9443027]
4. Origoni M, Rossi M, Ferrari D, Lillo F, Ferrari AG. Human papillomavirus with co-existing vulvar vestibulitis syndrome and vestibular papillomatosis. *Int J Gynecol Obstet*. 1999 Mar;64(3):259-63. [PMID: 10366048]
5. Welch JM, Nayagam M, Parry G, Das R, Campbell M, Whatley J, et al. What is vestibular papillomatosis? A study of its prevalence, aetiology and natural history. *Br J Obstet Gynaecol* 1993;100:939-42. [PMID: 8217979]
6. Van Beurden M, van der Vange N, de Craen AJ, Tjong-A-Hung SP, ten Kate FJ, ter Schegget, et al. Normal findings in vulvar examination and vulvoscopy. *Br J Obstet Gynaecol* 1997;104:320-4. [PMID: 9091009]

7. Altmeyer P, Chilk GN, Holzman H. Pseudokondylome der vulva. Geburtshilfe Frauenheilkd. 1981;41: 783-786. (6914993)
8. Champion MJ. Clinical manifestations and natural history of genital human papillomavirus infection. Obstet Gynecol Clin North Am. 1987;14(2), 363-388. [PMID: 8989776]
9. McKay M, Frankman O, Horowitz BJ, Lecart C, Micheletti L, Ridley CM et al. Vulvar vestibulitis and vestibular papillomatosis: report of the ISSVD committee on vulvodynia. J Reprod Med. 1991; 36(6), 413-415. [PMID: 1650839]
10. Rodríguez Prieto MA, Vega Gutiérrez J, Sánchez Sambucety P. Vestibular papillae of the vulva. Int J of Dermatol. 2004;43: 143-144. [PMID: 15125508]
11. Beznos G, Coates V, Focchi J, Hatim AO. Biomolecular Study of the Correlation Between Papillomatosis of the Vulvar Vestibule in Adolescents and Human Papillomavirus. The Scientific World Journal. 2006 (6):628-636. [PMID: 16832565]
12. Chan CC and Chiu HC. Images in Clinical Medicine. Vestibular papillomatosis. N Engl J Med. 2008. 358-14. [PMID: 18385501]
13. Wollina U, Verma S. Vulvar vestibular papillomatosis. Indian J Dermatol Venereol Leprol 2010;76:270-2. [PMID: 20445299]