

UC Davis

Dermatology Online Journal

Title

Adult-onset porokeratotic eccrine ostial and dermal duct nevus:dermatoscopic findings and treatment with tazarotene

Permalink

<https://escholarship.org/uc/item/1tf94054>

Journal

Dermatology Online Journal, 26(2)

Authors

Alomran, Husain
Kanitakis, Jean

Publication Date

2020

DOI

10.5070/D3262047423

Copyright Information

Copyright 2020 by the author(s).This work is made available under the terms of a Creative Commons Attribution-NonCommercial-NoDerivatives License, available at <https://creativecommons.org/licenses/by-nc-nd/4.0/>

Peer reviewed

Adult-onset porokeratotic eccrine ostial and dermal duct nevus: dermatoscopic findings and treatment with tazarotene

Husain Alomran, Jean Kanitakis

Affiliations: Department of Dermatology, Ed. Herriot Hospital Group, Lyon, France and Department of Pathology, Centre Hospitalier Lyon Sud, Pierre Bénite, France

Corresponding Author: Jean Kanitakis Department of Dermatology, Ed. Herriot Hospital Group, 69437 Lyon Cedex 03, France, Tel: 33-472110301, Email: jean.kanitakis@univ-lyon1.fr

Abstract

Porokeratotic eccrine ostial and dermal duct nevus (PEODDN) is a rare dermatosis initially described as 'comedo nevus' and renamed 'PEODDN'; it has also been referred to as linear eccrine nevus with comedones, porokeratotic eccrine ostial and hair follicle nevus, and porokeratotic adnexal ostial nevus. PEODDN is usually present at birth or develops early in life. Rarely, PEODDN can develop in adults. The treatment of this puzzling condition is not standardized. We report herein a new case of adult-onset PEODDN with dermatoscopic images. Our patient responded favorably to topical tazarotene.

Keywords: porokeratotic eccrine ostial and dermal-duct nevus, porokeratosis, tazarotene

Introduction

Porokeratotic eccrine ostial and dermal duct nevus (PEODDN) is a rare dermatosis initially described in 1979 as 'comedo nevus' [1] and it was renamed 'PEODDN' in 1980 [2]. It has also been referred to as linear eccrine nevus with comedones [3], porokeratotic eccrine ostial and hair follicle nevus [4], and porokeratotic adnexal ostial nevus [5]. Most cases of PEODDN are present at birth or develop during childhood [6]. Rarely, PEODDN can develop in adults.

Case Synopsis

A 38-year-old woman was referred to us for skin lesions that had appeared three years prior on her

left upper limb. Physical examination showed an erythematous-pink, slightly hyperkeratotic, rather well-limited elongated plaque on the radial side of her left thumb, extending to the wrist (**Figure 1A**). Dermatoscopic examination showed an erythematous plaque studded with several distinct whitish pinhead-sized globules (**Figure 1B**). The patient reported mild occasional pruritus, which was unrelated to her work and showed no clear seasonal variations. She mentioned that similar lesions had appeared previously on the same extremity (forearm and arm) but had regressed spontaneously. The patient was otherwise in good condition, had no other mucocutaneous lesions, and was not taking systemic treatments. She had two healthy children (aged 8 and 10 years) and her family history was unremarkable. Her lesions had been treated by her family physician with topical corticosteroids, which

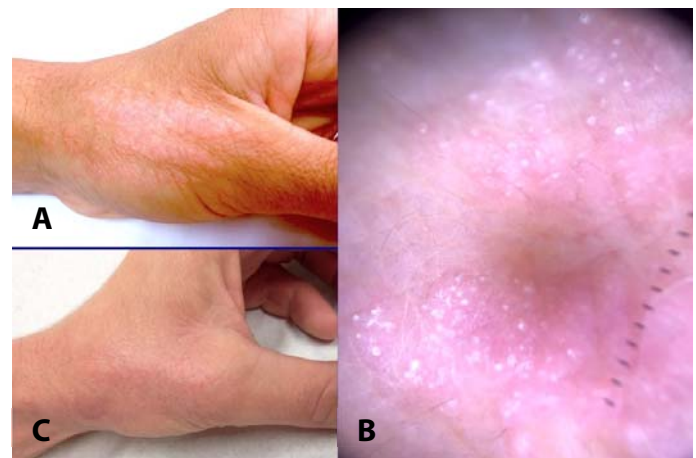


Figure 1. **A)** Clinical appearance of the lesion: erythematous-pink, slightly hyperkeratotic, well-limited elongated plaque on the radial side of the thumb, extending to the wrist. **B)** Dermatoscopic examination shows an erythematous plaque studded with several whitish pinhead-sized globules. **C)** Clinical improvement after a one-month treatment with 0.1% tazarotene gel.

alleviated pruritus, but had no obvious effect on the appearance of the plaque. Microscopic examination of a punch skin biopsy showed epidermal hyperplasia (hyperkeratosis, acanthosis, papillomatosis) and parakeratotic plugs within dilated, hyperplastic eccrine sweat-gland ostia (**Figure 2A, B**). A lymphocytic infiltrate was present in the dermis, surrounding the superficial part of the excretory eccrine sweat gland ducts and the eccrine sweat gland coil (**Figure 2C**). These findings were diagnostic of PEODDN. The patient was prescribed treatment with daily applications of tazarotene 0.1% gel. After one month, the lesions had improved, showing less erythema and surface hyperkeratosis (**Figure 1C**). The treatment was well-tolerated and the patient was advised to continue the treatment for another month.

Case Discussion

PEODDN, first described as 'comedo nevus of the palm' [1], is a rare condition of which about 70 cases have been reported in the literature. Most cases are present at birth or develop within the first two decades of life [6]. Seven cases [7-13] had their onset in adulthood, at a mean age of 31 years (range, 18-65). Our patient is therefore the 8th case of adult-onset PEODDN reported in the literature (**Table 1**).

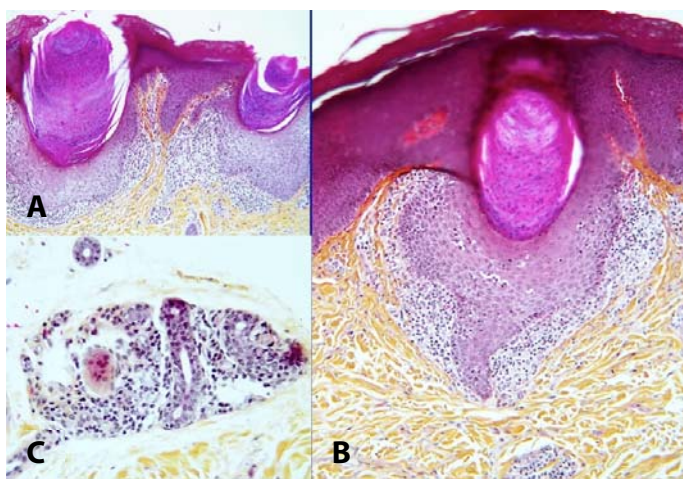


Figure 2. A, B) Microscopic examination of a skin biopsy shows two keratin parakeratotic plugs (cornoid lamellae) within dilated eccrine gland ostia. The upper dermis contains a lymphocytic infiltrate surrounding the superficial part of excretory eccrine sweat gland ducts. **C)** The infiltrate also surrounds the deep dermal eccrine sweat-gland coil. H&E, **A)** 100 \times , **B)** 200 \times , **C)** 400 \times .

PEODDN affects almost equally both genders, but the adult onset cases show a slight male predominance (5:3). It presents clinically with unilateral, verrucous or keratotic, pink, brown, or whitish pits with comedo-like plugs or papules, located primarily on the extremities, particularly the palms and soles [7-11, 13-15]. The lesions are more rarely bilateral. They may coalesce into linear plaques [8], sometimes following Blaschko lines [5, 7, 16], and have thereby been considered as a variant of linear porokeratosis by virtue of a similar pathological appearance. The lesions are usually asymptomatic [10, 13, 14] but may be mildly pruritic as in our patient [8, 9]. The clinical differential diagnosis of PEODDN includes dermatoses with linear distribution, such as epidermal nevi, linear psoriasis, linear Darier disease, linear lichen planus, and ichthyotic disorders with a Blaschkoid distribution, such as Conradi-Hünemann-Happle and CHILD syndrome [8, 13]. Dermatoscopic examination may assist the diagnosis by showing whitish pinhead-sized dots (corresponding to the surface of the cornoid lamellae embedded in eccrine ostia) over a slightly erythematous background. The definite diagnosis requires microscopic examination, which shows a variable degree of epidermal hyperplasia (hyperkeratosis, acanthosis, papillomatosis) and the presence of cornoid lamellae (narrow vertical stacks of parakeratotic corneocytes) within eccrine sweat gland ostia. A lymphocytic infiltrate may surround the eccrine gland, as in our case, and highlights the involvement of the eccrine gland in the development of this condition. The presence of cornoid lamellae confined to adnexal ostia differentiates PEODDN from other porokeratosis forms, in which the cornoid lamella is not confined to adnexal ostia [17].

The etiopathogenesis of PEODDN remains poorly known. It has been proposed that the lesions of porokeratosis result from the peripheral expansion of a clone of mutant epidermal keratinocytes located at the base of the cornoid lamella [17]. It can be speculated that the same mechanism could underlie PEODDN if the mutant keratinocytes reside within eccrine glands. Our finding of lymphocytic infiltration around eccrine glands is consistent with

Table 1. Cases of adult-onset porokeratotic eccrine ostial and dermal duct nevus published in the literature.

Case	Ref	Gender/ Age at onset	Location	Aspect of lesions	Associated conditions	Treatment/ Outcome
1	[7]	M/65	R palm	linearly-arranged yellow-grey keratotic papules	Hyperthyroidism, sensory polyneuropathy	nm/nm
2	[8]	M/18	L forearm, arm, upper chest	linearly-arranged brownish verrucous papules, nodules and plaques, punctate palmar pits	none	ablative laser therapy/nm
3	[9]	M/21	R lateral ankle	pruritic keratotic papules linearly distributed to form plaques	nm	nm/nm
4	[10]	F/27	L upper limb (index finger, hand dorsum, forearm)	multiple hyperpigmented keratotic papules discrete or coalescing to plaques	pits and groove of the nail of the index finger	nm/nm
5	[11]	F/29	L foot	Keratotic papules and pits, some with keratotic plugs	none	nm/nm
6	[12]	M/ mid 30's	R buttock	well-demarcated 2-cm plaque with multiple 3- to 4-mm-thick yellow-brown hornlike projections	poorly-controlled type II diabetes mellitus, heavy tobacco smoking	urea 40% cream: little improvement, shave removal: no recurrence 12 months later
7	[13]	M/30	L hand	punctate pits, keratotic papules and verrucous plaques	none	topical keratolytics, emollients/ nm
8	This case	F/35	L wrist	Pink, well-demarcated plaque with a keratotic surface	none	tazarotene 0.1% gel/ improvement

this hypothesis. Heredity may play a role since one familial case has been reported [18]. The distribution of PEODDN lesions along the lines of Blaschko suggests that genetic mosaicism may play a role [19]. More recently, it was found that PEODDN is caused by somatic mutations in the gene *GJB2* encoding for connexin 26 [20], a gap junction protein, which permits intercellular ion and macromolecule flux. Porokeratotic eccrine ostial and dermal duct nevus, especially when systematized or bilateral, can be associated with various conditions, including hyperthyroidism and sensory polyneuropathy [7], breast hypoplasia [21], deafness, developmental delay [22], alopecia, onychodysplasia [23], psoriasis [24], palmoplantar keratoderma [25], hemiparesis, and scoliosis [26]. Whether or not these associations are fortuitous remains speculative. The association of PEODDN with KID (keratosis, ichthyosis, deafness) syndrome [27] is interesting and seems significant since this complex genetic disease is also related to

mutations of the *GJB2* gene. It has been suggested that patients carrying *GJB2* somatic mosaicism are at risk for transmitting systemic disease to their offspring and that all individuals with PEODDN should therefore be counseled regarding the risk of having a child with KID syndrome [20].

The course of PEODDN is chronic. The lesions may remain stable over years [8, 10] or be slightly progressive [12]. Our patient experienced spontaneous regression of part of her lesions on the arm and forearm. The prognosis is as a rule benign; however, transformation of PEODDN into Bowen disease [28] and squamous cell carcinoma [29, 30] has been reported. This fact is consistent with the contention that PEODDN may be a form of linear porokeratosis, known to be at risk for malignant transformation [17].

The treatment of PEODDN is challenging as no standardized option exists. Various treatments have

Table 2. Cases of porokeratotic eccrine ostial and dermal duct nevus treated with topical tazarotene (TZT).

Case	Ref	Age/ Gender	Location of lesions	Previous treatments	Treatment with TZT	Result
1	[5]	Newborn/F	chest, legs, neck, perineum	–	TZT 0.1% cream, 5-FU 5% cream and emollients	Somewhat helpful
2	[5]	37/F	trunk & extremities along Blaschko lines	Minocycline 100mg twice/d × 2 months: slight reduction in the blistering eruption	TZT 0.05% cream	Minimal response
3	[28]	6/M	R palm & sole	Urea keratolytics: no response	TZT 0.1% gel 3 weeks	Significant improvement
4	this case	F/35	L hand	Local corticosteroids: improved pruritus	TZT 0.1% gel One month	Significant improvement

been used, but none seems to be regularly effective [6]. Topical corticosteroids (methylprednisolone and clobetasol propionate) can achieve temporary relief [31, 32]. Local tretinoin 1% cream, calcipotriene ointment [32], 5-fluorouracil [5], and various keratolytics have been used, including urea ointment or cream [12] and salicylic acid in petrolatum [15], without significant results. Systemic acitretin (50mg/d for two months) was ineffective in one case, although it improved the pruritus [15]. Partial results have been obtained with photodynamic therapy [33]. Carbon dioxide laser [6, 8, 16] alone or combined with erbium [34] have provided good results, especially for large lesions. Topical tazarotene has been tried in three patients, as 0.1% gel or 0.05% or 0.1% cream (**Table 2**). Two patients showed minimal response [5], but another patient achieved almost complete response within three weeks [28]. We decided to try this treatment in our patient since it can provide good results in various (genetic or acquired) diseases of keratinization and our patient obtained encouraging results. The systemic absorption of tazarotene after

local application to small skin areas seems to be limited, nevertheless a pregnancy test is recommended prior to the onset of treatment in women of childbearing potential. The drug is contraindicated in women who are pregnant or desire a pregnancy.

Conclusion

Porokeratotic eccrine ostial and dermal duct nevus can rarely appear in adults but should be considered in the differential diagnosis of acral keratotic lesions appearing in adulthood. The diagnosis is usually made by histological examination. Although no regularly effective standard treatment exists our observation suggests that tazarotene 0.1% gel may be a satisfactory treatment option. More cases need to be studied in order to confirm the efficacy of this treatment.

Potential conflicts of interest

The authors declare no conflicts of interests

References

- Marsden RA, Fleming K, Dawber RPR. Comedo naevus of the palm—a sweat duct naevus? *Br J Dermatol.* 1979;101:717. [PMID: 93967].
- Abell E, Read SI. Porokeratotic eccrine ostial and dermal duct naevus. *Br J Dermatol* 1980;103:435. [PMID: 7437310].
- Blanchard L, Hodge SJ, Owen LG. Linear eccrine nevus with comedones. *Arch Dermatol.* 1981;117:357. [PMID: 7247428].
- Coskey RJ, Mehregan AH, Hashimoto K. Porokeratotic eccrine duct and hair follicle nevus. *J Am Acad Dermatol.* 1982;6:940. [PMID: 709665].
- Goddard D, Rogers M, Frieden I, Krol A, White Jr CR, Jayaraman AG, Bostom LR, Bruckner AL, Ruben BS. Widespread porokeratotic adnexal ostial nevus: Clinical features and proposal of a new name unifying porokeratotic eccrine ostial and dermal duct nevus and

- porokeratotic eccrine and hair follicle nevus. *J Am Acad Dermatol*. 2009;61:1060.e1. [PMID: 19664847].
6. Llamas-Velasco M, Hilty N, Kempf W. Porokeratotic adnexal ostial naevus: review on the entity and therapeutic approach. *J Eur Acad Dermatol Venereol*. 2015;29:2032. [PMID: 25255914].
 7. Rasi A, Tajziechi L. Late-onset porokeratotic eccrine ostial and dermal duct nevus associated with sensory polyneuropathy and hyperthyroidism. *Arch Iran Med*. 2008;11:218.
 8. Bandyopadhyay D, Saha A, Das A, Das A. Porokeratotic eccrine ostial and dermal duct nevus. *Indian Dermatol Online J*. 2015; 6: 117. [PMID: 25821735].
 9. Naraghi M, Nikoo A, A. Goodarzi A. Porokeratotic Eccrine Ostial and Dermal Duct Nevus. *Case Rep Dermatol Med*. 2013;2013:953840. [PMID: 24307955].
 10. Mondal A, Kumar P, Das A, Debbarman P, Kumar Mandal R. Porokeratotic eccrine ostial and dermal duct nevus: A noteworthy presentation. *Indian Dermatol Online J*. 2015;6:130. [PMID: 25821740].
 11. Stoof TJ, Starink TM, Nieboer C. Porokeratotic eccrine ostial and dermal duct nevus. Report of a case of adult onset. *J Am Acad Dermatol*. 1989;20[5, part 2]:924. [PMID: 2715447].
 12. Arbogast M, Bax D, Paragh G, Bogner P. Late-onset solitary porokeratotic eccrine ostial and dermal duct nevus. *JAAD Case Rep*. 2018;4:434. [PMID: 29984273].
 13. Bhushan P, Thatte S, Singh A, Jayant S. Porokeratotic eccrine ostial and dermal duct nevus: A report of three cases. *Indian J Dermatol Venereol Leprol*. 2016;82:553. [PMID: 27297273].
 14. Ghiasi M, Jamshidi S, Ghasemi H, Kamyab K, Nikoo A. Porokeratotic eccrine ostial and dermal duct nevus [PEODDN]: A case report. *Iran J Dermatol*. 2011;14:106.
 15. Birol A, Erkek E, Bozdoethan O, Koçak M, Atasoy P. A case of porokeratotic eccrine ostial and dermal duct naevus of late onset. *J Eur Acad Dermatol Venereol*. 2004;18:619-621. [PMID: 15324411].
 16. Pathak D, Kubba R, Kubba A. Porokeratotic eccrine ostial and dermal duct nevus. *Indian J Dermatol Venereol Leprol*. 2011;77:174. [PMID: 21393947].
 17. Kanitakis J. Porokeratoses: an update of clinical, aetiopathogenic and therapeutic features. *Eur J Dermatol*. 2014;24:533. [PMID: 25115203].
 18. Masferrer E, Vicente M, Bassas-Vila G, Rovira C, Gonzalez-Ensenat M. Porokeratotic eccrine ostial dermal duct nevus. Report of 10 cases. *J Eur Acad Dermatol Venereol*. 2010;24:847. [PMID: 19925595].
 19. Wong J, Summers E, Taylor, Harris RM. Porokeratotic eccrine ostial and dermal duct nevus treated with a combination erbium/CO2 laser: A case and brief review. *Dermatol Online J*. 2011;17:10. [PMID: 21971275].
 20. Levinsohn J, McNiff J, Antaya R, Choate K. A somatic p.G45E GJB2 mutation causing porokeratotic eccrine ostial and dermal duct nevus. *JAMA Dermatol*. 2015;151:638. [PMID: 25692760].
 21. Jyaramn A, Robinson-Bostom L, McDonald C. Bilateral Systematized Porokeratotic Eccrine Ostial and Dermal Duct Nevus with Unilateral Breast Hypoplasia [abstr.]. *J Cutan Pathol*. 2005;32:95.
 22. Jamora MJJ, Celis MA. Generalized porokeratotic eccrine ostial and dermal duct nevus associated with deafness. *J Am Acad Dermatol*. 2008;59[2, suppl. 1]:S43. [PMID: 18625383].
 23. Hartman R, Rizzo C, Patel R, Kamino H, Shupack JL. Porokeratosis palmaris et plantaris disseminata or a disseminated late-onset variant of porokeratotic eccrine ostial and dermal ductal nevus [PEODDN] with follicular involvement. *Dermatol Online J*. 2009; 15:15:8. [PMID: 19891916].
 24. Yu HJ, Ko JY, Kwon HM, Kim JS. Linear psoriasis with porokeratotic eccrine ostial and dermal duct nevus. *J Am Acad Dermatol*. 2004;50[5 Suppl]:S81. [PMID: 15097935].
 25. Cobb MW, Vidmar DA, Dilaimy MS. Porokeratotic eccrine ostial and dermal duct nevus: a case of systematized involvement. *Cutis*. 1990;46:495. [PMID: 2269022].
 26. Solis J, Sau P, James WD. Puzzling palmar and plantar papules. Porokeratotic eccrine ostial and dermal duct nevus. *Arch Dermatol*. 1991;127:1220. [PMID: 1863085].
 27. Criscione V, Lachiewicz A, Robinson-Bostom L, Grenier N, Dill SW. Porokeratotic eccrine duct and hair follicle nevus [PEHFN] associated with keratitis-ichthyosis-deafness [KID] syndrome. *Pediatr Dermatol*. 2010;27:514. [PMID: 21182641].
 28. Coras B, Vogt T, Roesch A, Landthaler M, Hohenleutner U. Bowen's disease on porokeratotic eccrine ostial and dermal duct nevus. *Dermatol Surg*. 2007;33:496. [PMID: 17430387].
 29. Xiangang F, Huixian L, Lankai Y, Jiayou X, Xinbo W, Yunxiang Z, Zhenhua W. Metastatic squamous cell carcinoma arising from a serious widespread porokeratotic eccrine ostial and dermal duct nevus: Case report and literature review. *Dermatol Sinica* 2017;35:92. [DOI: 10.1016/j.dsi.2016.09.004].
 30. Nassiri N, Hansen J. Diffuse squamous cell carcinoma in porokeratotic eccrine ostial and dermal duct nevus. *Plast Reconstr Surg*. 2009;123:87e. [PMID: 19182594].
 31. Agulló-Pérez AD, Resano-Abarzuza MA, Córdoba-Iturriagagoitia A, Yanguas-Bayona J. Porokeratotic eccrine and hair follicle nevus: a report of two cases and review of the literature. *An Bras Dermatol*. 2017;92[5 Suppl 1]:121. [PMID: 29267468].
 32. Zade J, Jfri A, Nabatian A, Alajaji A, Geller L, Khorasani J. Porokeratotic eccrine ostial and dermal duct nevus: a unique case treated with CO₂ laser. *Clin Case Rep*. 2017;5:675. [PMID: 28469874].
 33. Kim WJ, Choi SR, Lee HJ, Kim DH, Yoon MS. Porokeratotic eccrine ostial and dermal duct nevus showing partial remission by topical photodynamic therapy. *Ann Dermatol*. 2011;23[Suppl 3]:S322. [PMID: 22346268].
 34. Del Pozo J, Martinez W, Vereá M, Yebra-Pimentel MT, Garcia-Silva J, Fonseca E. Porokeratotic eccrine ostial and dermal duct naevus: treatment with carbon dioxide laser. *Br J Dermatol*. 1999;141:1144. [PMID: 10722274].