

UC Davis

Dermatology Online Journal

Title

Cutaneous T-cell lymphoma-associated Leser-Trélat sign: report and world literature review

Permalink

<https://escholarship.org/uc/item/0w01b1t3>

Journal

Dermatology Online Journal, 23(1)

Authors

Narala, Saisindhu
Cohen, Philip R

Publication Date

2017

DOI

10.5070/D3231033672

Copyright Information

Copyright 2017 by the author(s). This work is made available under the terms of a Creative Commons Attribution-NonCommercial-NoDerivatives License, available at <https://creativecommons.org/licenses/by-nc-nd/4.0/>

Peer reviewed

Cutaneous T-cell lymphoma-associated Leser-Trélat sign: report and world literature review

Saisindhu Narala¹ BS, Philip R. Cohen² MD

Affiliations: ¹School of Medicine, University of California San Diego, La Jolla, California, ²Department of Dermatology, University of California San Diego, La Jolla, California

Corresponding Author: Saisindhu Narala, BS, sindhunarala@gmail.com; Philip R. Cohen, MD, mitehead@gmail.com

Abstract

Background: The sign of Leser-Trélat is characterized by the sudden appearance of seborrheic keratoses associated with an underlying malignancy. **Objectives:** An elderly man who developed multiple new-onset seborrheic keratoses temporally associated with a diagnosis of mycosis fungoides is described and lymphoma-associated Leser-Trélat sign is reviewed. **Methods:** Pubmed was used to search the following terms: cutaneous T-cell lymphoma, Leser-Trélat, leukemia, lymphoma, mycosis fungoides, and Sézary syndrome. Papers with these terms and references cited within these papers were reviewed. **Results:** An 84-year-old man developed multiple seborrheic keratoses temporally associated with a diagnosis of mycosis fungoides is presented. He was treated with bexarotene and achieved clinical remission; the number of seborrheic keratoses also decreased. Lymphoma-associated Leser-Trélat sign has been observed not only with mycosis fungoides but also other lymphomas and leukemias. **Conclusions:** The sign of Leser-Trélat is predominantly associated with solid organ adenocarcinomas. Albeit less common, an eruptive onset of seborrheic keratoses can also occur in association with hematopoietic malignancies.

Keywords: cutaneous, fungoides, Leser-Trélat, lymphoma, mycosis, seborrheic keratosis, Sézary syndrome, T-cell

Introduction

The Leser-Trélat sign is characterized by the eruptive onset of multiple seborrheic keratoses in a patient with underlying malignancy. It is most commonly associated with adenocarcinomas of the gastrointestinal tract, but has also—albeit less often—been associated with hematopoietic malignancies such as mycosis fungoides, a cutaneous T-cell lymphoma (CTCL). A man with new-onset seborrheic keratoses who was concurrently diagnosed with mycosis fungoides is described, and patients whose lymphomas were associated with Leser-Trélat sign are summarized.

Case Synopsis

An 84-year-old man presented with a 1-year history of a red, scaly rash on his entire body. He also noted several new brown skin lesions that had concurrently developed on his chest, back, and arms. The lesions were accompanied by extreme pruritus. He denied any constitutional symptoms (fever, weight loss, and night sweats) and review of systems was otherwise negative.

Cutaneous examination revealed diffuse erythroderma with scaling on approximately 95% of the body surface (**Figure 1**). Multiple brown plaques, 1 to 2 centimeters in greatest diameter, were present on his chest, back, and arms, consistent with seborrheic keratoses (**Figure 1**). There was no evidence of acanthosis nigricans or palpable lymph nodes.

Punch biopsy of a plaque on his right arm revealed orthokeratosis, acanthosis with elongation and anastomosis of the rete ridges, and pigment-laden keratinocytes with horn-cyst formation, establishing a diagnosis of seborrheic keratosis (**Figure 2**).

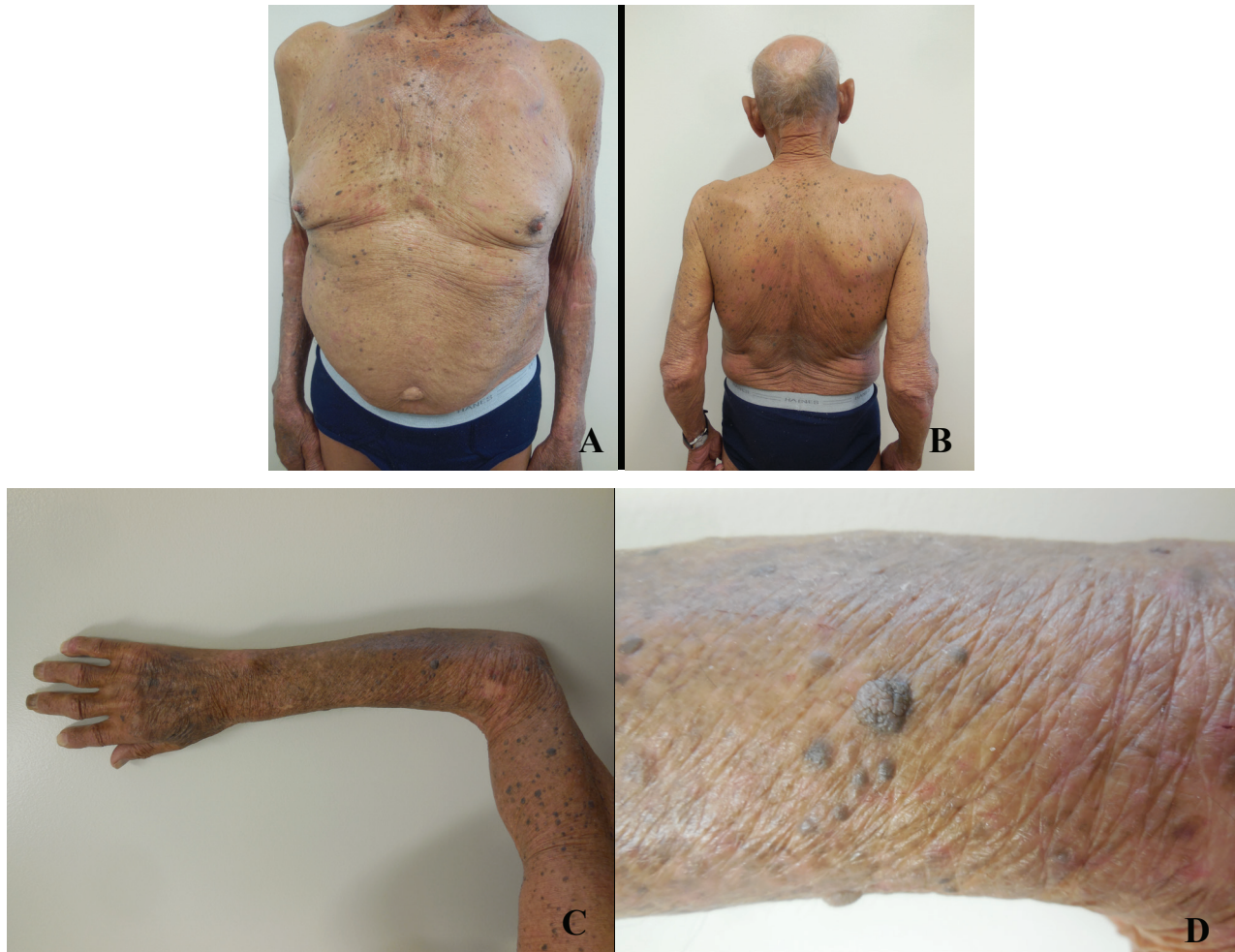


Figure 1. The concurrent appearance of erythroderma and eruptive onset of seborrheic keratoses on the chest (A), back (B), and arms (C and D); distant (C) and closer (D) views of the plaque biopsied on the right arm.

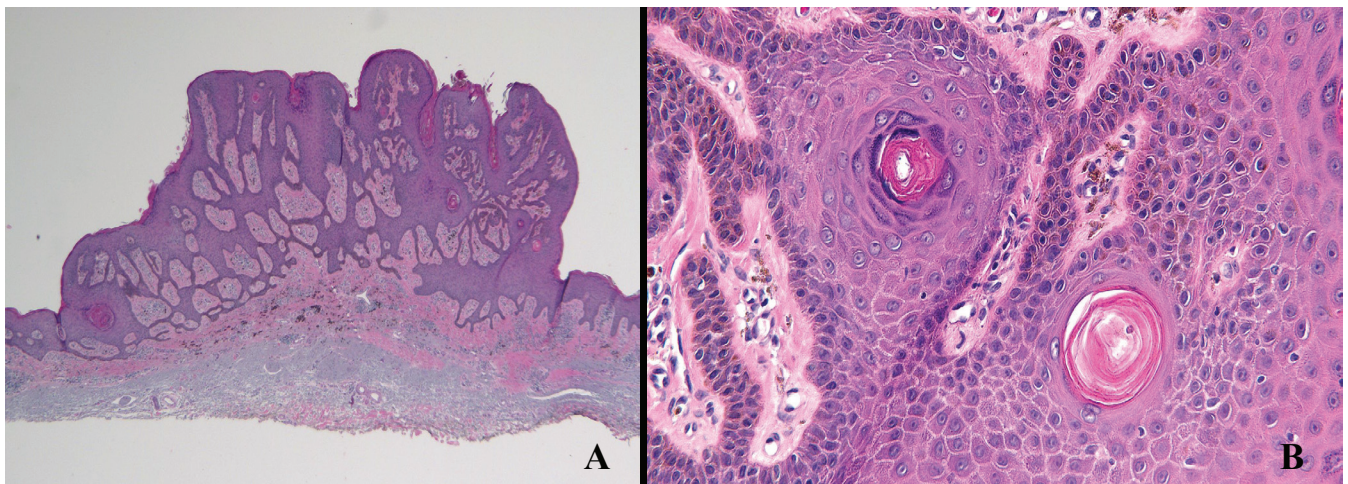


Figure 2. (A) Low magnification view and higher (B) magnification view (of the right side of panel A) of a plaque on the right arm showed hyperkeratosis, acanthosis, and keratin-filled pseudocyst, establishing a diagnosis of seborrheic keratosis (hematoxylin and eosin stain: A, x4, B, x40).

Punch biopsies from the right and left chest showed similar findings: epidermal spongiosis with infiltration of the epidermis by atypical lymphocytes. The papillary dermis showed a dense infiltrate of similar appearing lymphocytes (**Figure 3**).

Immunohistochemistry studies revealed an elevated CD4:CD8 ratio of 5:1. These findings confirmed the diagnosis of mycosis fungoides (**Figure 4**). Complete blood cell counts were within normal limits and no circulating Sézary cells were present. Further work-

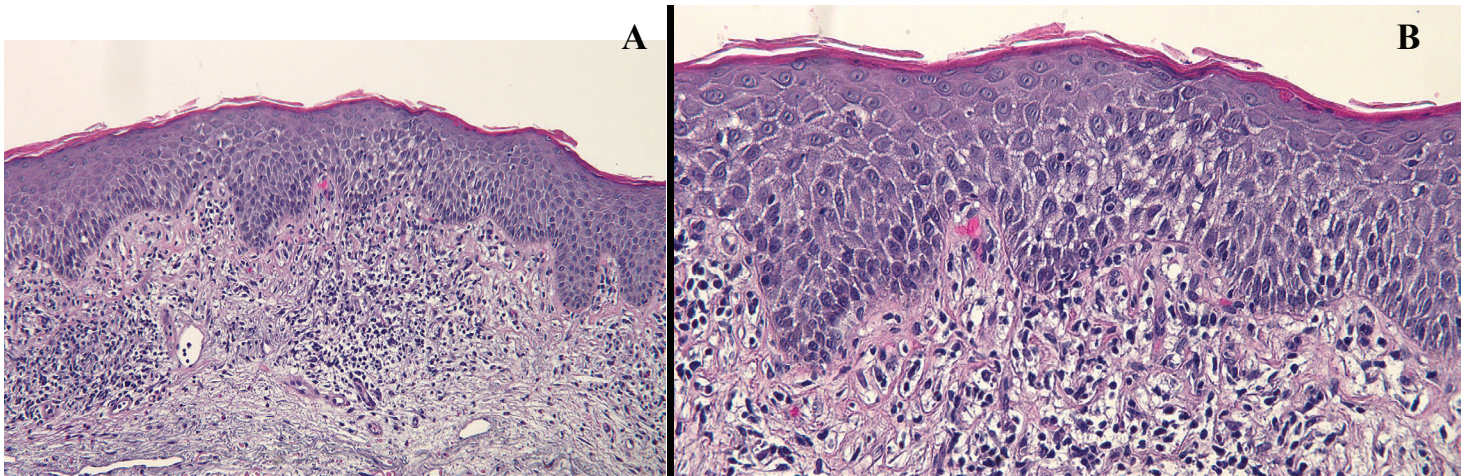


Figure 3. Low (A) and higher power (B) magnification views of the biopsy from the right chest shows atypical lymphocytes in the papillary dermis with exocytosis of the cells into the overlying epidermis, establishing a diagnosis of mycosis fungoides (hematoxylin and eosin stain: A, 10x, B, 20x).

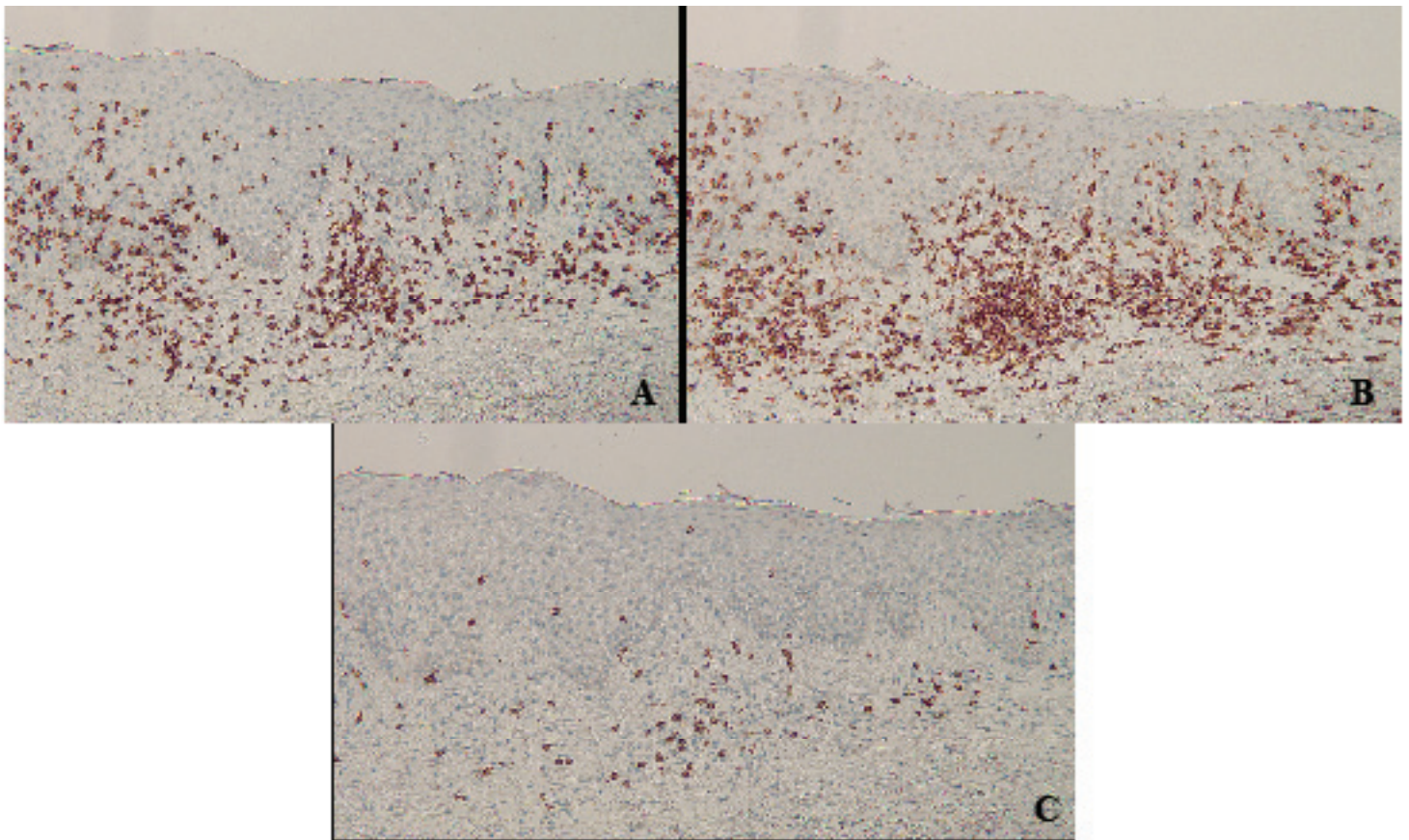


Figure 4. Immunohistochemistry of mycosis fungoides skin lesions showing CD3 positive T cells in the epidermis and dermis (A). High CD4 (helper T cells) positivity (B) and low CD8 (suppressor T cells) positivity (C) are present, demonstrating the characteristic high CD4:CD8 ratio in mycosis fungoides (immunoperoxidase stain: A, 10x, B, 10x, C, 10x).

up included PET/CT scan of the chest and abdomen, which revealed mediastinal lymphadenopathy.

Correlation of clinical examination and pathology findings established a diagnosis of Stage IIIa mycosis fungoides associated with the sign of Leser-Trélat. Initial management consisted of high-potency topical

corticosteroid application (clobetasol propionate 0.05% cream twice daily) and systemic antihistamines (fexofenadine 180 mg daily, ranitidine 150 mg daily, and hydroxyzine 10 mg daily). These interventions resulted in partial diminution of erythroderma and partial relief of pruritus; however, they did not alter the course of mycosis fungoides.

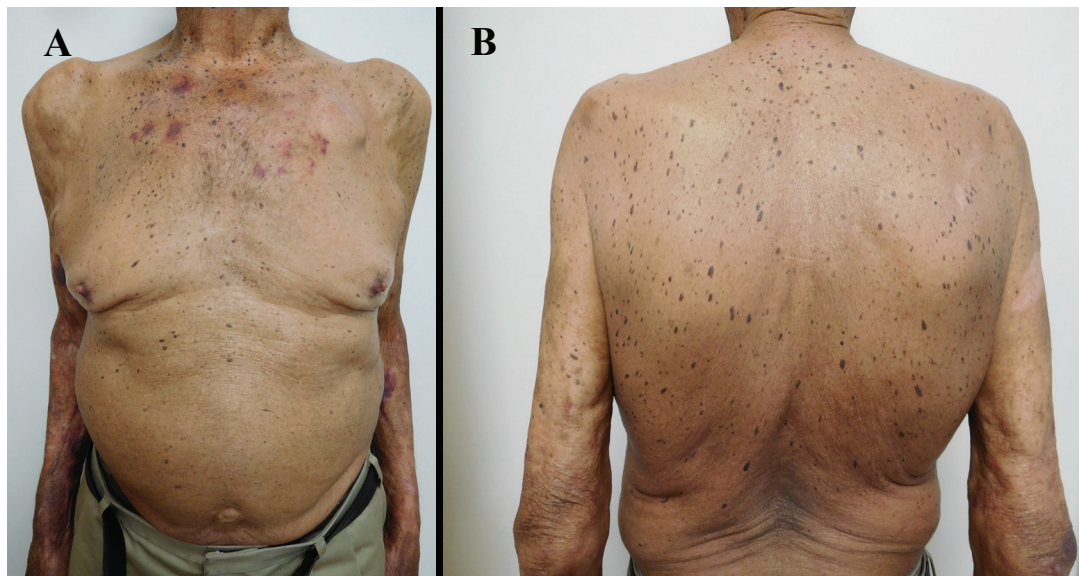


Figure 5. Reduction of seborrheic keratoses on chest (A) and back (B) after successful treatment of mycosis fungoides with bexarotene.

Treatment with bexarotene 300 mg per day was initiated. Within two months, there was complete resolution of not only the pruritus, but also the erythroderma. Follow-up examination also showed a reduction in the number of seborrheic keratoses (**Figure 5**).

Case Discussion

The discovery of the sign of Leser-Trélat is attributed to two European surgeons, Edmund Leser (1827-1916) and Ulysse Trélat (1827-1890), who independently described the eruption of cutaneous lesions in patients with cancer. However, retrospective review indicated that the lesions they identified were actually cherry angiomas [1]. Hollander was the first

physician to accurately describe the association of multiple eruptive seborrheic keratoses with internal malignancy in 1900 [2]. Since then, numerous case reports documenting the eruption of multiple seborrheic keratoses and its association with cancer have been published [1].

Leser-Trélat sign is most commonly associated with adenocarcinomas of the gastrointestinal tract, such as stomach, liver, pancreas, and colorectal [1]. Lymphoproliferative disorders are the second most common type of associated malignancy [4]. We identified 28 individuals with Leser-Trélat sign-associated lymphoma and leukemia (**Table 1**, [3-28]) and summarized the characteristics of 15 patients—

| Malignancy | Number of Patients | Percent | Reference(s) |
|-------------------|--------------------|---------|--------------|
| Lymphoma (N = 22) | | | |
| CTCL | 15 | 68.2 | 3-16, CR |
| Lymphocytic | 2 | 9.1 | 17, 18 |
| Primary CNS | 1 | 4.5 | 19 |
| Unspecified | 4 | 18.2 | 5, 20-22 |
| Leukemia (N = 6) | | | |
| Acute myelogenous | 4 | 66.7 | 23-26 |
| Acute lymphocytic | 1 | 16.7 | 27 |
| Unspecified | 1 | 16.6 | 28 |

Table 1. Lymphomas and Leukemias Associated with Leser-Trélat sign. Abbreviations: CNS, central nervous system; CR, current report; CTCL, cutaneous T-cell lymphoma; N, number of patients

including the man described in this report—with cutaneous T-cell lymphoma-associated sign of Leser-Trélat (**Table 2**, [3-16]).

CTCL is characterized by the presence of neoplastic T lymphocytes in the skin. Mycosis fungoides is a type of CTCL with indolent behavior that can advance to an aggressive variant called Sézary syndrome [29]. Of the identified patients with CTCL-associated Leser-Trélat sign, 8 patients (53%) had mycosis fungoides while 7 patients (47%) had Sézary syndrome (**Table 2**).

Conclusion

The sign of Leser-Trélat is the sudden appearance of multiple seborrheic keratoses in a patient with underlying malignancy. Although classically associated with adenocarcinomas, it has also been reported in patients with lymphoproliferative disorders. We summarize 15 cases of Leser-Trélat sign associated with CTCL. Leser-Trélat sign either preceded (5 patients), was concurrent with (5 patients), or followed (5 patients) the diagnosis of CTCL. Associated pruritus was noted in 85% of the individuals. Lymphoma-directed treatment was

| Case | CTCL Type | A R/S | TA[^a] | Pr | SK Site | SK Bx | Treatment | SK Response to Tx | Ref |
|------|-----------|-------------|--------------------|----|--------------|-------|-----------------------------|-------------------|-----|
| 1 | MF | 61 Ca/M | F [2] | - | Ba, Ch, Face | - | NS | NS | 4 |
| 2 | MF (Pl) | 63 Ca/M | Con | + | Tr | + | Bleomycin chemotherapy | Res | 5 |
| 3 | MF (T) | 71 AA, M | F [9] | + | Neck, Tr, UE | - | NS | NS | 6 |
| 4 | MF | 83 H/M | Con | + | Ba, Ch, UE | + | Bexarotene | Red | CR |
| 5 | MF | 87 NS/M | Con | NS | Ba, Ch | NS | Electron beam irradiation | Res | 7 |
| 6 | MF (Pl) | 35 As/W | Con | NS | Ch, Neck | NS | PUVA, Etr, IL-1 | Red | 8 |
| 7 | MF | 61 NS/W | P [2] | + | Ba, Ch | - | PUVA | Res | 9 |
| 8 | MF | 76 Ca/W | F [24] | + | NS | + | Mustard gas, Plasmapheresis | NR | 10 |
| 9 | SS | 55 Ca/M | Con | + | Ba, Ch, Sh | + | NS | NS | 11 |
| 10 | SS | 57 Ca/M | F [60] | + | Tr | + | Photopheresis IFN alpha | Res | 12 |
| 11 | SS | 58 NS/M | F [7] | + | Fa, LE, Tr | + | Electron beam irradiation | Res | 3 |
| 12 | SS | 74 As/M | P [3] | - | Entire body | + | Chemotherapy | Red | 13 |
| 13 | SS | 82 H/M | P [6] | + | Tr | + | PUVA, IFN alpha | Red | 14 |

Table 2. Characteristics of Patients with CTCL-associated Leser-Trélat sign. Abbreviations: A, age; AA, African-American; As, Asian; Ba, back; Bx, biopsy; Ca, Caucasian; Ch, chest; Con, concurrent; CR, current report; CTCL, cutaneous T-cell lymphoma; Etr, Etrinate; F, followed; H, Hispanic; IFN, interferon; IL-1, interleukin-1 (intravenous); LE, lower extremity; M, man; MF, mycosis fungoides; NR, no response; NS, not stated; P, preceded; Pl, plaque stage; Pr, pruritus; PUVA, psoralen and ultraviolet A; R, race; Red, reduction; Ref, reference; Res, resolution; S, sex; Sh, shoulder; SK, seborrheic keratosis; SS, Sézary syndrome; T, tumor stage; TA[^a], temporal association [duration in months]; Tr, trunk; Tx, treatment; UE, upper extremity; W, woman; +, positive; -, negative

a. The diagnosis of CTCL either preceded, was concurrent (within 1 month), or followed the onset of seborrheic keratoses.

associated with a reduction of seborrheic keratoses in 92% of these patients.

References

- Schwartz RA. Sign of Leser-Trélat. *J Am Acad Dermatol*. 1996 Jul;35:88-95. [PMID:8682971]
- Hollander E. V. Beitrage zur Fruhdiagnose des Darmcarcinomas (Hereditatsverhältnisse und Hautveränderungen. *Deutsche Medicinische Wochenschrift* 1900;26:483-485.
- Wieselthier JS, Bhawan K, Koh HK. Transformation of Sézary syndrome and the sign of Leser-Trélat: a histopathologic study. *J Am Acad Dermatol*. 1990 Sep;23(3 Pt 1):520-522. [PMID:2145329]
- Safai B, Grant J, Good R. Cutaneous manifestation of internal malignancies (II): the sign of Leser-Trélat. *Int J Dermatol* 1978 Jul-Aug;17:494-495. [PMID:150408]
- Martínez-Morán C, Sanz-Muñoz C, Miranda-Romero A. Leser-Trélat sign associated with Sézary syndrome and transitional cell carcinoma of the bladder. *Actas Dermosifiliogr*. 2007 Apr;98:213-218. [PMID:17504710]
- Rowe B, Shevchenko A, Yosipovitch G. Leser-Trélat in Tumor-Stage Mycosis Fungoides. *Dermatology Online Journal* 2016;22(4):8. [PMID: 27617461]
- Lambert D, Fort M, Legoux A, Chapuis JL. The signe de Leser-Trélat: a propos de 2 observation. *Ann Dermatol Venereol*. 1980;107:1035-1041. [PMID:6453550]
- Miyako F, Dekio S, Tamura H, Yamada Y, Miyata N, Jidoi J, Tohgi K. Mycosis fungoides with Leser-Trélat sign: the first report of a patient from Japan. *J Dermatol*. 1994 Mar;21(3):189-193. [PMID:8014273]
- Toonstra J, Ramselaar CG, Van der Putte SCJ, Leser-Trélat sign in mycosis fungoides. A further case report. *Dermatologica*. 1985;171:247-249. [PMID:2934280]
- McCrary ML, Davis LS. Sign of Leser-Trélat and mycosis fungoides. *J Am Acad Dermatol*. 1998 Apr;38(4):644. [PMID:9555814]
- Dantzig PI. Sign of Leser-Trélat. *Arch Dermatol*. 1973 Nov;108:700-701. [PMID:4270762]
- Cohen JH, Lessin SR, Vowels BR, Benoit B, Witmer WK, Rook AH. The sign of Leser-Trélat in association with Sézary syndrome: simultaneous disappearance of seborrheic keratoses and malignant T-cell clone during combined therapy with photopheresis and interferon alfa. *Arch Dermatol*. 1993 Sep;129(9):1213-1215. [PMID:8395792]
- Ikari Y, Ohkura M, Morita M, Seki K, Kubota Y, Mizoguchi M. Leser-Trélat sign associated with Sézary syndrome. *J Dermatol*. 1995 Jan;22:62-67. [PMID:7897028]
- Blázquez E, Fernández-López E, Fernández-Canedo I, de Unamuno P, Martín-Pascual A. Signo de Leser-Trélat asociado a síndrome de Sézary. *Actas Dermosifiliogr*. 2003;94: 309-312.
- Bursztejn AC, Doumat-Batch F, Granel-Brocard F, Perrin A, Cuny JF, Barbaud A, Schmutz JL. Sézary syndrome and Leser-Trélat sign: a chance association? *Ann Dermatol Venereol*. 2008 Apr;135(4):287-290. [PMID:18420075]
- Horiuchi Y, Katsuoka K, Tsukamoto K, Takezaki S. Leser-Trélat sign associated with Sézary syndrome. *Cutis*. 1985 Nov;36(5):409-410. [PMID:2933229]
- Halevy S, Halevy J, Feuerman EJ. The sign of Leser-Trélat in association with lymphocytic lymphoma. *Dermatologica*. 1980;161(3):183-186. [PMID:6447087]
- Wagner RF, Wagner KD. Malignant neoplasms and the Leser-Trélat sign. *Arch Dermatol*. 1981 Sep;117(9):598-599. [PMID:6457570]
- Kaplan DL, Jegasothy B. The sign of Leser-Trélat associated with primary lymphoma of the brain. *Cutis*. 1984 Aug;34(2):164-165. [PMID:6478878]
- Halevy S, Sandbank M. Transformation of lymphocytoma cutis into a malignant lymphoma in association with the sign of Leser-Trélat. *Acta Derm Venereol*. 1987;67(2):172-175. [PMID:2438886]
- Hatamochi A, Kohda M, Ueki H, Ishihara K, Kihara T, Sano K. Sign of Leser-Trélat. *Nishinihom J Dermatol*. 1982;54:373-378.
- Matsumoto, R, Hayashi, M, Takahashi, Y et al. A case of sign of Leser-Trélat. *Rinsho Dermatol (Tokyo)*. 1985;27:1015-1019.
- Greer KE. Leser-Trélat associated with acute leukemia. *Arch Dermatol*. 1978 Oct;114(10):1552. [PMID:152610]
- Kechijian P, Sadick NS, Maniglio J, Schulman P. Cytarabine-induced inflammation in the seborrheic keratosis of Leser-Trélat. *Ann Intern Med*. 1979 Dec;91: 868-869. [PMID:293142]
- Lilly E, Granter SR, Haynes HA, Ibrahim OA. Chemotherapy-induced inflammatory seborrheic keratoses in a man with acute myeloid leukemia: a variant of Leser-Trélat sign? *Cutis*. 2012 Nov;90(5):235-236. [PMID:23270192]
- Yavasoglu I, Kadikoylu G, Bolaman Z. The Leser-Trélat sign is associated with acute myeloid leukemia. *Ann Hematol*. 2011 Mar;90(3):363. [PMID:20703879]
- Fasoldt JJ, Brumwell ER, Lackey JN. Leser-Trélat sign presenting in a patient with recurrent pre-B-cell acute lymphocytic leukemia. *Cutis*. 2012 Jan;89(1):33-35. [PMID:22439308]
- Shinoda H, Nakazato H, Takiguchi K. A case of Leser-Trélat sign associated with leukemia. *Rinsho Derma (Tokyo)*. 1982;24:1008-1009.
- Sidiropoulos KG, Martinez-Escala ME, Yelamos O, Guitart J, Sidiropoulos M. Primary cutaneous T-cell lymphomas: a review. *J Clin Pathol*. 2015 Dec;68(12):1003-1010. [PMID:26602417]
- Holdiness MR. On the classification of the sign of Leser-Trélat. *J Am Acad Dermatol*. 1988 Oct;19:754-757. [PMID:2972760]
- Saraiya A, Al-Shoha A, Brodell RT. Hyperinsulinemia Associated with Acanthosis Nigricans, Finger Pebbles, Acrochordons, and the Sign of Leser-Trélat. *Endocr Pract*. 2013 May-Jun;20:1-15. [PMID:23425641]
- Aylesworth R, Vance JC. Multiple hamartoma syndrome with endometrial carcinoma and the sign of Leser-Trélat. *Arch Dermatol*. 1982 Feb;118:136-138. [PMID:7059218]
- Jemec GB. Hypertrichosis lanuginosa acquisita: report of a case and review of the literature. *Arch Dermatol*. 1986 Jul;122:805-808. [PMID:3729512]
- Rubisz-Brzezifiska J, ~ebracka T, Musia/owicz D. Wsp6fistuienie dwu zespol6w paraneoplastycznych--acrokeratosis Bazex oraz zespo/u Lesera-Tr61ata--wprzypadku raka plaskonab/onkowego krtani. *Przeg Dermatol*. 1983;70:205-208.
- Schwartz RA. Florid cutaneous papillomatosis. *Clin Dermatol*. 1993 Jan-Mar;11:89-91. [PMID:8339205]
- Millard LG, Gould DJ. Hyper Hyperkeratosis of the palms and soles associated with internal malignancy and elevated levels of immunoreactive human growth hormone. *Clin Exp Dermatol*. 1976 Dec;1:363-368. [PMID:137091]
- Elgart GW. Seborrheic keratoses, solar lentigines, and lichenoid keratoses. Dermatoscopic features and correlation to histology and clinical signs. *Dermatol Clin*. 2001 Apr;19(2):347-357. [PMID:11556243]
- Yamamoto T. Leser-Trélat sign: current observations. *Expert Rev Dermatol*. 2013 Oct;8(5):541-545.
- Stone OJ. The sign of Leser-Trélat: a cutaneous sign of internal malignancy: weakened subepithelial matrix from the effect of neoplasms on the extracellular matrix of the host. *Med Hypotheses*. 1993 Jun;40(6):360-363. [PMID:8377673]
- Ellis DI, Kafka SP, Chow JC, Nanney LB, Inman WH, McCadden ME, King LE Jr. Melanoma, growth factors, acanthosis nigricans, the sign of Leser-Trélat, and multiple acrochordons. A possible role for alpha-transforming growth factor in cutaneous neoplastic syndromes. *N Engl J Med*. 1987 Dec;317(25):1582-1587. [PMID:2825016]
- Ellis DI, Kafka SP, Chow JC, Nanney LB, Inman WH, McCadden ME, King LE Jr. Melanoma, growth factors, acanthosis nigricans, the sign of Leser-Trélat, and multiple acrochordons. A possible role for alpha-transforming growth factor in cutaneous neoplastic syndromes. *N Engl J Med*. 1987 Dec;317(25):1582-1587. [PMID:2825016]