

UC Davis

Dermatology Online Journal

Title

Primary malignant melanoma of the ovary arising in a cystic teratoma; case report and review of the literature

Permalink

<https://escholarship.org/uc/item/0tr2b2z9>

Journal

Dermatology Online Journal, 20(10)

Authors

Lee, James
Magpayo, John
Panchari, Charles
et al.

Publication Date

2014

DOI

10.5070/D32010024233

Copyright Information

Copyright 2014 by the author(s). This work is made available under the terms of a Creative Commons Attribution-NonCommercial-NoDerivatives License, available at <https://creativecommons.org/licenses/by-nc-nd/4.0/>

Peer reviewed

Case Report

Primary malignant melanoma of the ovary arising in a cystic teratoma; case report and review of the literature

James Lee¹ MD PhD, John Magpayo² MD, Charles Panchari² MD, Shi-Kaung Peng¹ MD PhD

Dermatology Online Journal 20 (10): 2

¹Harbor-UCLA Medical Center, Torrance CA

²Whittier Medical Center, Whittier California

Correspondence:

James Lee
Harbor-UCLA Medical Department of Pathology
1000 West Carson Street, Torrance CA.
Phone: 310-222-2241
Fax: 310-222-8002
email: jlee91780@gmail.com

Abstract

Primary malignant melanoma of the ovary arising in a cystic teratoma is extremely rare. There is no melanocytic component in the normal ovarian tissue. However, melanocytes may be present in a cystic teratoma of the ovary, especially at the basal layer of squamous epithelium. We report a case of primary malignant melanoma of the ovary arising in a cystic teratoma. We demonstrate junctional activity of melanocytes showing malignant transformation with both radial and vertical growth phases, a feature diagnostic for primary malignant melanoma but not always demonstrated in such cases. We compiled and reviewed twelve cases that are also able to demonstrate junctional activity.

Keywords: Primary Melanoma, teratoma, ovarian cancer, junctional activity

Introduction

An ovarian malignant melanoma is rare with unfavorable prognosis, usually owing to metastases [1]. Primary malignant melanomas are even more rare in the ovary [2,3] and its diagnosis requires fulfillment of established criteria. Boughton et al. [4] and Cronje and Woodruff [5] proposed the following criteria for the diagnosis of primary ovarian melanoma: 1) no other possible sites of a primary tumor; 2) unilateral tumor within the ovarian teratoma; 3) good correlation of the patient's age and symptoms with those of well-documented cases in the literature; and 4) demonstration of junctional activity (desirable but not necessary for diagnosis). A point of controversy for diagnosing the primary nature of this malignancy is whether or not it is necessary to fulfill the last criteria—demonstration of junctional activity. Indeed, establishing junctional activity goes further toward providing evidence that the malignant cells originated from this junctional activity and many cases reported as primary malignancies without junctional activity may actually be metastatic disease, thus portending higher mortality risk for the patient. In this report, we report a case of primary malignant melanoma of the ovary arising in a cystic teratoma. We also compare and contrast the metastatic and mortality rate of these cases showing junctional activity with those of cases without junctional activity in specimens reported as primary malignant melanoma of ovary.

Case synopsis

We report a case of a 38-year-old female who presented with a 2 month history of lower abdominal pain. A 12 x 13 cm left adnexal mass was discovered on CT for which the patient was treated with left salpingo-oophorectomy. The specimen was received in one container fixed in formalin labeled "left tube and ovary" and consisted of an ovary, tan to tan-yellow, with multiloculated

cysts that had been previously opened. It measured 12 x 7 x 3.5 cm. There was an overlying segment of fallopian tube that measured 6.5 cm in length and 1.1 cm in average diameter. The ovary showed some intact cystic structures; some were filled with keratinosebaceous material and others with clear watery fluid. Solid areas, on serial sectioning, revealed a smooth tan-brown cut surface. Some cystic structures were lined by flattened squamous epithelium with pilosebaceous structures, respiratory epithelium with underlying mucinous glands, and a solid area containing cartilage and thyroid tissue (Figure 1). The findings were diagnostic for a mature cystic teratoma.

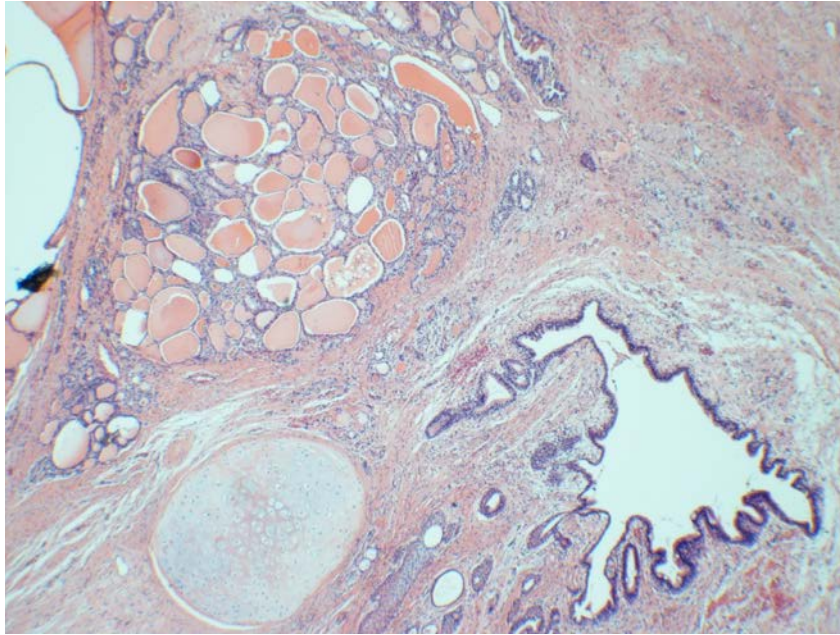


Figure 1. Mature cystic teratoma consisting of cysts lined by flattened squamous epithelium and respiratory epithelium and containing cartilage and thyroid tissue (H&E x 217)

Junctional activity of melanocytes was observed within the squamous epithelium. There was a 2 cm tumor nodule in the cyst wall (Figure 2A). The cytomorphological features of the tumor cells included a moderate amount of eosinophilic cytoplasm with round to ovoid pleomorphic nuclei, which had a vesicular chromatin pattern and prominent nucleoli (Figure 2B). The tumor cells stained positively for S100, Melan-A, HMB 45, and vimentin, which supported a diagnosis of malignant melanoma. The tumor appeared continuous with overlying squamous epithelium, which contained melanocytes in the junctional areas. Junctional melanocytes showed evidence of malignant transformation with radial and vertical growth phases, which were highlighted by immunohistochemical stains for Melan-A and HMB-45 (Figure 3). Vertical grown phase melanoma with formation of a tumor nodule in the cyst wall strongly supported the primary nature of this malignant melanoma of ovary.

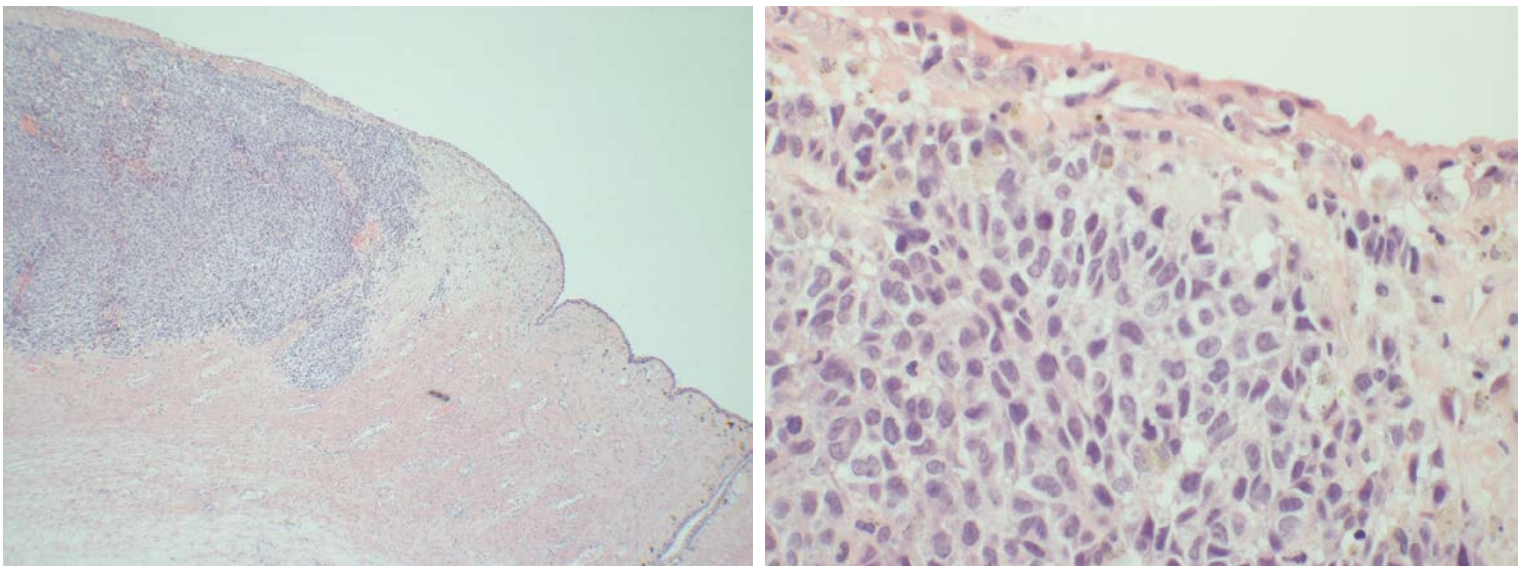


Figure 2. (A) A 2 cm tumor nodule in the cyst wall (H&E stain x 217). (B) Higher magnification showing epithelioid tumor cells and junctional activity of melanocytes in the overlying squamous epithelium (H&E stain x 650)

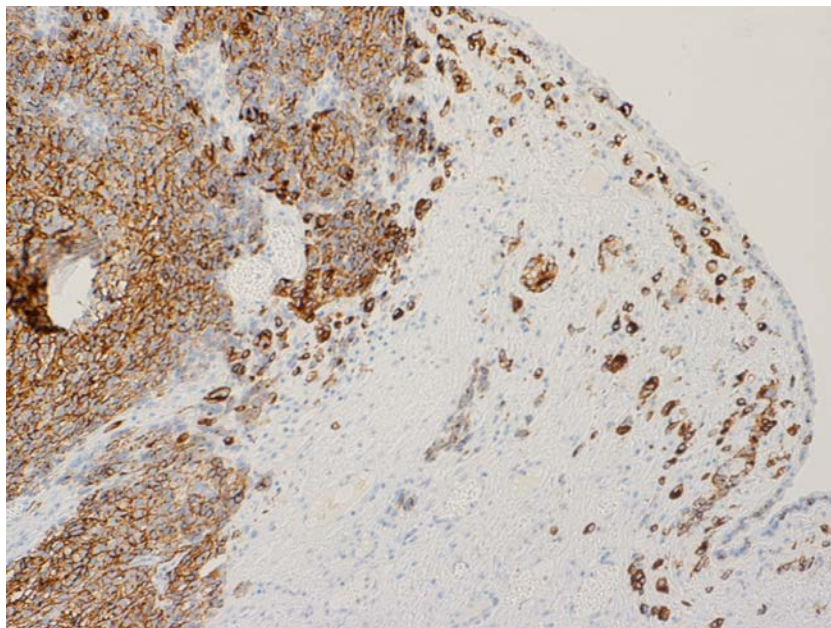


Figure 3. Radial and vertical growth phases of melanocytes are highlighted by immunohistochemical stain for HMB-45.

Other possible primary sites of melanoma, such as the skin, intestine, and eye were examined but no pigmented lesions were found in this patient. The malignant melanoma arose in a unilateral ovarian teratoma, thus fulfilling the main criteria as established by Boughton et al. [4] and Cronje and Woodruff et al [5] for diagnosing primary malignant melanoma of the ovary occurring in association with a dermoid cyst.

Discussion

Lee et al. [6] recently reviewed and compiled 19 cases of primary malignant melanoma of the ovary that matched some of the criteria established by Boughton et al. [4] and Cronje and Woodruff [5]. Amongst these cases, only five cases were identified as establishing junctional activity and thus fulfilling all the established criteria. We additionally found the remaining 5 more cases in the literature whereby junctional activity was also established (Table I), thus completing a comprehensive review of available cases of this entity. The unique histology we show for our case thoroughly establishes this junctional activity as being the origin of malignant cells in that we demonstrate radial and vertical growth phases of junctional melanocytes with progression into malignant melanoma in the cyst wall of cystic teratoma of ovary.

Compared to the cases whereby junctional activity could not be observed (see table II), cases exhibiting junctional activity (see Table I in this report) generally had less occurrence of distant metastases; 4 of the 12 cases with junctional activity had distant metastases, fewer than the 8 of the 13 cases without junctional activity previously reported. Likewise, 4 of the 12 (33%) with junctional activity were dead of disease at follow-up, again a lower frequency than the 8 from the 13 cases (62%) without junctional activity. The improved mortality in cases with junctional activity may suggest that the observation of junctional activity means that the disease was caught at an earlier stage when junctional activity in the primary ovarian malignant melanomas had not yet been destroyed by tumor invasion. An alternative explanation is that several of the cases whereby junctional activity could not be established are not indeed primary malignancies. However, owing to the limited number of cases reported thus far, it remains to be seen if lower metastatic and mortality rate in cases showing junctional activity continues to be observed as more cases become available.

Table I. Clinical-pathologic features of previous cases of primary malignant melanoma of the ovary with established junctional activity.

Author	Age (yr)	Distant metastasis	Follow-up time	Patient outcome
Nanbu et al. ⁷	47	No	ND*	NED ⁺
Parekh et al. ⁸	26	Yes	8 months	DOD ⁺⁺
Marcial-Rojas et al. ⁹	77	Lost to followup	Lost to followup	NED

Author	Age (yr)	Distant metastasis	Follow-up time	Patient outcome
Leo et al. ¹⁰	72	No	8 mo	NED
Park et al. ¹¹	49	Not mentioned	Not mentioned	Not mentioned
O’Gorman and Olaitan. ¹²	49	No	ND	NED
Vigliani et al. ¹³	67	Yes	3 mo	DOD
Takubo et al. ¹⁴	65	No	24 mo	NED
Cronje and Woodruff ⁵	74	Yes	18 mo	DOD
Boughton et al. ⁴	27	No	2 yr	NED
Liberati et al., ¹⁶	74	No	7 months	NED 7 months
Gregg et al. ¹⁷	56	Yes	4 months	DOD

*ND-(Not determined)

+NED-(No evidence of disease)

++DOD-(Dead of Disease)

Table II. Clinical-pathologic features of previous cases of primary malignant melanoma of the ovary where junctional activity could not be determined or established (Table and information adapted from Lee et al.⁶)

Author	Age (yr)	Distant metastasis	Follow-up time	Patient outcome
Carlson and Wheeler ¹⁸	20	Yes	5 year	NED ⁺
O’Leary and Tejura et al. ¹⁹	79	No	2 month	DOD ⁺⁺
Ueda et al. ²⁰	86	No	ND	DOD
Watanabe et al. ²¹	55	No	6 mo	NED
McNeilage et al. ²²	19	Yes	37 days	DOD
Vimla et al. ²³	42	Yes	18 mo	NED
Zarbo et al. ²⁴	60	Yes	4 mo	DOD

Gök <i>et al.</i> ²⁵	67	No	7 mo	DOD
Tsukamoto <i>et al.</i> ²⁶	46	Yes	12 mo	NED
Gao <i>et al.</i> ²⁷	53	Yes	6 mo	DOD
(A) Lee <i>et al.</i> ²⁸	46	Yes	2 mo	DOD
Choi <i>et al.</i> ²⁹	45	Yes	37 mo	NED
(B) Lee <i>et al.</i> ⁶	71	Yes	5 month	DOD

*ND-(Not determined)

+NED-(No evidence of disease)

++DOD-(Dead of Disease)

References

- Gupta D, Deavers MT, Silva EG, Malpica A: Malignant melanoma involving the ovary: a clinicopathologic and immunohistochemical study of 23 cases. *Am J Surg Pathol* 2004, 28:771-780.
- Davis GL: Malignant melanoma arising in mature ovarian cystic teratoma (dermoid cyst). Report of two cases and literature analysis. *Int J Gynecol Pathol* 1996, 15:356-362.
- McCluggage WG, Bissonnette JP, Young RH: Primary malignant melanoma of the ovary: a report of 9 definite or probable cases with emphasis on their morphologic diversity and mimicry of other primary and secondary ovarian neoplasms. *Int J Gynecol Pathol* 2006, 25:321-329.
- Boughton RS, Hughmanick S, Marin-Padilla M. Malignant melanoma arising in an ovarian cystic teratoma in pregnancy. *Journal of the American Academy of Dermatology*. 1987; 17 (5) Part 2: 871-875.
- Cronje HS, Woodruff JD. Primary ovarian malignant melanoma arising in cystic teratoma. *Gynecol Oncol* 1981; 12: 379-83.
- Lee S, Kim JH, Chon GR, et al. Primary malignant melanoma arising in an ovarian mature cystic teratoma. 2011; 45: 659-664.
- Nanbu Y, Fujii S, Konishi I, et al. Primary ovarian malignant amelanotic melanoma arising in cystic teratoma. *Gynecologic Oncology* 1990; 37: 138-142.
- Parekh MA. Primary malignant melanoma in an ovarian cystic teratoma. *Missouri Medicine* 1985; 82 (1): 18-20.
- Marcial-Rojas RA, Ramirez de Arellano GA. Malignant melanoma arising in a dermoid cyst of the ovary. *Cancer* 1956; 523-527. Boughton RS, Hughmanick S, Marin-Padilla M. Malignant melanoma arising in an ovarian cystic teratoma in pregnancy. *J Am Acad Dermatol* 1987; 17(5 Pt 2): 871-5.
- Leo S, Rorat E, Parekh M. Primary malignant melanoma in a dermoid cyst of the ovary. *Obstetrics and Gynecology* 1973; 41 (2): 205-210.
- Park H, Kramer EE, Gray GF. Primary malignant melanoma in an ovarian dermoid cyst. *Amer. J. Obstet. Gynec.* 1970; 106 (6): 942-943.
- O'Gorman T, Olaitan A. Primary malignant melanoma arising in an ovarian cystic teratoma. *Eur J Gynaecol Oncol* 2009; 30: 88-9.
- Vigliani R, Landolo M, Lacivita A. Mature ovarian cystic teratoma with combined squamous cell carcinoma and malignant melanoma. *Virchows Arch* 1998; 433: 381-4.
- Takubo K, Kimura T, Suzuki K, et al. Malignant melanoma arising in ovarian cystic teratoma. *Gynecol Oncol* 1991; 43: 77-80.
- Selak I, Doric M, Kapidzic M. Malignant melanoma arising from a cystic dermoid teratoma of the ovary. *Jugosl Ginekol Perinatol* 1991; 31: 37-9.
- Liberati F, Maccio T, Stefano Ascani, Farabi R, Lancia D, Peciarolo A, Bolis GB. Primary malignant melanoma arising in an ovarian cystic teratoma. *Acta Oncologica*. 1998; 37 (4): 381-3.
- Gregg RH. Primary malignant melanoma arising in an ovarian dermoid cyst. *Am. J. Obstet. Gynecol.* 1982; 143: 25-28.
- Carlson JA Jr, Wheeler JE. Primary ovarian melanoma arising in a dermoid stage IIIc: long-term disease-free survival with aggressive surgery and platinum therapy. *Gynecol Oncol* 1993; 48: 397-401.
- O'Leary AJ, Tejura H. Malignant Melanoma arising in a cystic teratoma of the ovary. *J Obstet Gynaecol* 2005; 25: 626-7.

20. Ueda Y, Kimura A, Kawahara E, Kitagawa H, Nakanishi I. Malignant melanoma arising in a dermoid cyst of the ovary. *Cancer* 1991; 67: 3141-5.
21. Watanabe Y, Ueda H, Nakajima H, Minoura R, Hoshiai H, Noda K. Amelanotic malignant melanoma arising in an ovarian cystic teratoma: a case report. *Acta Cytol* 2001; 45: 756-60.
22. McNeilage LJ, Morgan J, Constable J, Jobling TW. Metastatic malignant melanoma arising in a mature ovarian cystic teratoma: a case report and literature review. *Int J Gynecol Cancer* 2005; 15: 1148-52.
23. Vimla N, Kumar L, Thulkar S, Bal S, Dawar R. Primary malignant melanoma in ovarian cystic teratoma. *Gynecol Oncol* 2001; 82: 380-3.
24. Zarbo R, Scibilia G, Conoscenti G, Scollo P. Ovarian cystic teratoma with primary epithelial cell melanoma. *Eur J Gynaecol Oncol* 2005; 26: 71-4.
25. Gok ND, Yildiz K, Corakci A. Primary malignant melanoma of the ovary: case report and review of the literature. *Turk Patoloji Derg* 2011; 27: 169-72.
26. Tsukamoto N, Matsukuma K, Matsumura M, Kamura T, Matsuyama T, Kinjo M. Primary malignant melanoma arising in a cystic teratoma of the ovary. *Gynecol Oncol* 1986; 23: 395-400.
27. Gao R, Liu NF, Sheng XG. Malignant ovarian melanoma with extensive pelvic and peritoneal metastasis: a case report and literature review. *Chin J Cancer* 2010; 29: 460-2.
28. Lee SH, Lee KB, Shin JW, Chung DH, Park CY. Ovarian malignant melanoma without evidence of teratoma. *Eur J Gynaecol Oncol* 2009; 30: 88-9.
29. Choi YS, Jung CW, Kim J, Park GW, Seo YL, Park SH, Park K. A case of the primary ovarian malignant melanoma arising from a cystic teratoma. *Korean J Med* 2004; 66: 644-8.