

# UC Davis

## Dermatology Online Journal

### Title

Mycobacterium marinum infection of the wrist

### Permalink

<https://escholarship.org/uc/item/0sq646zv>

### Journal

Dermatology Online Journal, 29(2)

### Authors

Chumsaengsri, Chumsaeng  
Khommee, Jirawan  
Uraierkkul, Papitchaya

### Publication Date

2023

### DOI

10.5070/D329260774

### Copyright Information

Copyright 2023 by the author(s). This work is made available under the terms of a Creative Commons Attribution-NonCommercial-NoDerivatives License, available at <https://creativecommons.org/licenses/by-nc-nd/4.0/>

Peer reviewed

# ***Mycobacterium marinum* infection of the wrist**

Chumsaeng Chumsaengsri, Jirawan Khommee, Papitchaya Uraierkkul

Affiliations: Institute of Dermatology, Bangkok, Thailand

Corresponding Author: Dr Papitchaya Uraierkkul, Institute of Dermatology, Bangkok 10400, Thailand. Email: [kowpundpap@gmail.com](mailto:kowpundpap@gmail.com)

## **Abstract**

*Mycobacterium marinum* is a nontuberculous mycobacterium capable of causing skin and soft tissue infections. Most infections are associated with skin trauma and contact with contaminated water in fish tanks, pools, or infected fish. The incubation period is about 21 days but can be prolonged up to 9 months before the onset of symptoms. We report a patient with cutaneous *Mycobacterium marinum* infection with a non-pruritic erythematous plaque on his right wrist for three months. A history of exposure to contaminated freshwater two years prior was the only exposure that could be determined. Treatment with oral ciprofloxacin combined with clarithromycin produced a good outcome.

**Keywords:** cutaneous, infection, *Mycobacterium marinum*

## **Introduction**

*Mycobacterium marinum* infection is an uncommon disease that mainly affects the skin, usually with a chronic, indolent, and benign evolution. *Mycobacterium marinum* has an optimal growth temperature of 30°C, whereas only small colonies or no growth is observed at 37°C. The most common skin manifestation described for about 60% of the cases is a solitary papule or nodule on a finger or hand followed by a sporotrichoid spread that occurs when the infection disperses along the lymphatic vessels to the regional lymph nodes, producing multiple nodules resembling sporotrichosis. Occasionally, pustular, nodulo-ulcerative, granulomatous, or verrucous plaques may be observed [1]. The distribution is predominantly acral.

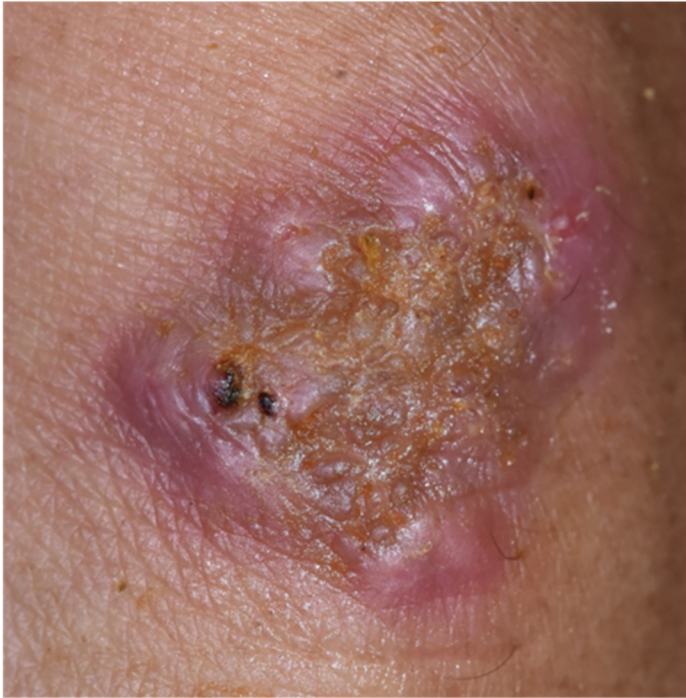Upper extremities such as a finger or hand, are the most common site of infection [2].

Delayed diagnosis of *Mycobacterium marinum* infection has been reported and may result in significant morbidity if left untreated [3]. Clues in the clinical history, such as exposure to fish contaminated water, fish tank, and pools can warrant appropriate further investigation. Knowledge of the incubation period can also be helpful; an incubation period of about 21 days is noted in most cases. However, a previous report suggested a prolonged incubation period of up to 9 months [4].

## **Case Synopsis**

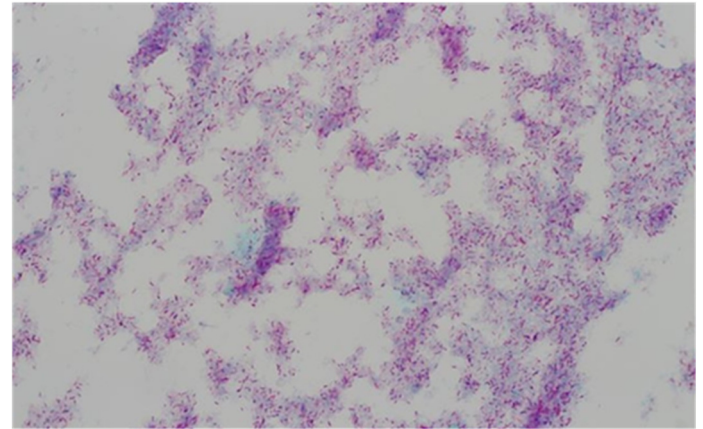
A 52-year-old man, with a history of ischemic stroke and hypertension, presented with a localized well-defined erythematous indurated plaque with yellowish crust on the dorsum of the right wrist for three months. The lesion had started as a solitary papule. Gradual increase in number and coalescence to form plaques without pruritus was noted. He denied a history of fever or weight loss. He worked as a soldier and only recalled the history of fishing at a freshwater canal in Bangkok two years earlier but denied any hand or finger injuries. He had no history of drug allergies. He was treated with various topical medications and had 14 days of oral amoxicillin/clavulanic acid two months before he came to the hospital; the response was poor.

On physical examination, he had a localized well-defined, non-scaly erythematous indurated plaque with some reddish honey-colored crusts on the dorsum of the right wrist without lymphadenopathy (**Figure 1**).



**Figure 1.** Erythematous indurated plaque with some reddish honey-colored crusts on the dorsum of the right wrist, before treatment.

Incisional biopsy of the plaque was performed and histopathology revealed irregular acanthosis with pseudoepitheliomatous hyperplasia and mixed inflammatory cell infiltrate in the dermis to subcutaneous fat with fibrosis. There was no distinct granulomatous formation, but multinucleated giant cells were evident; no microorganisms were seen. (**Figure 2**) The aerobic, anaerobic, and fungal cultures were negative but *Mycobacterium marinum* was isolated from culture on Löwenstein-Jensen medium after 14 days of incubation at 25°C (**Figure 2C**). An acid-fast bacteria (AFB) stain was negative



**Figure 3.** Acid-fast bacilli positive from mycobacterial culture.

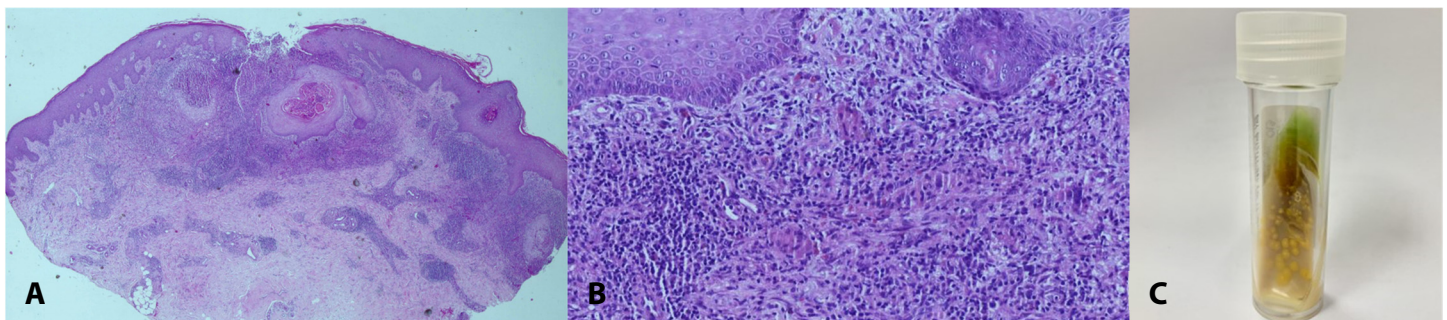
from the tissue biopsy but AFB from the mycobacterial culture was positive (**Figure 3**).

The patient was diagnosed with cutaneous *Mycobacterium marinum* infection and therefore, was treated with ciprofloxacin 500mg twice daily and clarithromycin 500mg twice daily. After 12 weeks of treatment, the plaque gradually resolved (**Figure 4**).

## Discussion

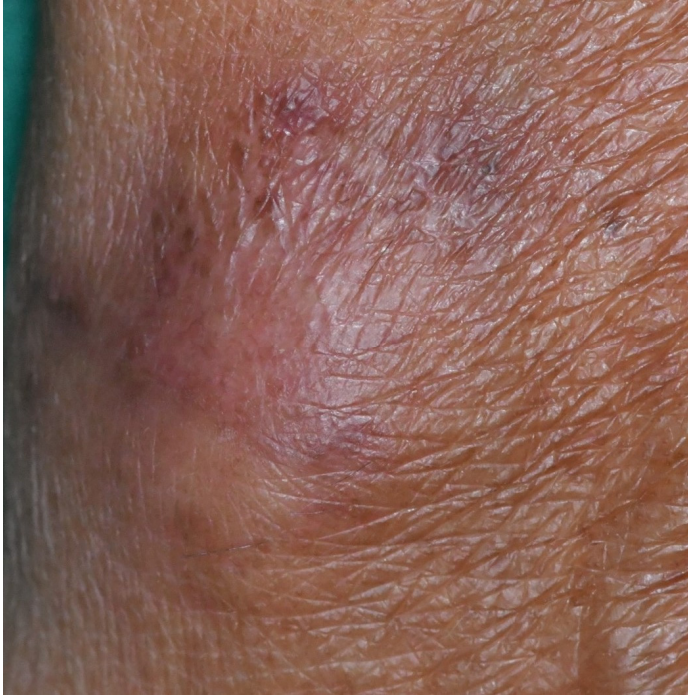
The important exposure history from the patient may not be obtained because of the nonspecific lesion [5]. The reported average time from clinical manifestation to accurate diagnosis varies from one to 27 months with a mean interval of 7 months [6]. A delay in treatment may lead to deeper infections, including osteomyelitis, tenosynovitis, and disseminated disease [7].

Most reviews of previous studies show an incubation period of about 21 days but can prolong up to 9



**Figure 2.** H&E histopathology. **A)** Irregular acanthosis with pseudoepitheliomatous hyperplasia, 2.5×. **B)** Mixed inflammatory cell infiltrate in the dermis with fibrosis. There was no distinct granulomatous formation, but multinucleated giant cells were evident, 20×. **B)** **C)** *Mycobacterium marinum* culture on Löwenstein-Jensen medium identified by molecular genetics department, Institute of Dermatology, Bangkok, Thailand.





**Figure 4.** Evolution after treatment. Dorsum right wrist, 12 weeks after initiation of treatment.

months. Confirmation of the diagnosis can be made by microbiology culture (isolation and identification of *Mycobacterium marinum*) and histopathology.

The treatment of cutaneous infection with *Mycobacterium marinum* has not been standardized. The appropriate treatment depends on several factors, including mainly the severity of the infection and the patient's immune status. Single or a few lesions, which appear as crusted or ulcerated

nodules or plaques are frequently observed in immuno-competent patients in whom spontaneous regression has been reported. However, *Mycobacterium marinum* is a multidrug-resistant organism. Monotherapy antibiotics including clarithromycin, trimethoprim, and ciprofloxacin may be effective therapy. In cases of deeper infections, including with sporotrichoid distribution patterns, a combination of rifampicin and ethambutol may be required [8,9]. The duration of reported therapy ranges from one to 25 months with a median of 3.5 months. The continuation of treatment has been recommended to be at least until the lesions are healed and then for two additional months [1]. Surgical treatment may be required for deep-tissue infections [10].

## Conclusion

In our patient a history of exposure to freshwater was noted two years before he developed the nonpruritic erythematous plaque on the dorsal right wrist. This is not the typical duration of the incubation period but no other exposures could be elicited. Therefore, the history of prior exposure to fresh water provided an impetus for further investigation.

## Potential conflicts of interest

The authors declare no conflicts of interest.

## References

1. Aubry A, Mougari F, Reibel F, Cambau E. *Mycobacterium marinum*. *Microbiol Spectr*. 2017;5:735-52. [PMID: 28387180].
2. Costescu Strachinaru DI, Vanbrabant P, Stinga P, Strachinaru M, Soentjens P. Diagnosis of *Mycobacterium marinum* Infection with Sporotrichoid Pattern. *Acta Derm Venereol*. 2021;101:adv00414. [PMID: 33686447].
3. Dolenc-Voljc M, Zolnir-Dovc M. Delayed diagnosis of *Mycobacterium marinum* infection: A case report and review of the literature. *Acta Dermatovenerol Alp Pannonica Adriat*. 2010;19:35-9. [PMID: 20664920].
4. Jernigan JA, Farr BM. Incubation period and sources of exposure for cutaneous *Mycobacterium marinum* infection: case report and review of the literature. *Clin Infect Dis*. 2000;31:439-43. [PMID: 10987702].
5. Streit M, Böhlen LM, Hunziker T, et al. Disseminated *Mycobacterium marinum* infection with extensive cutaneous eruption and bacteremia in an immunocompromised patient. *Eur J Dermatol*. 2006;16:79-83. [PMID: 16436349].
6. Dodiuk-Gad R, Dyachenko P, Ziv M, et al. Nontuberculous mycobacterial infections of the skin: A retrospective study of 25 cases. *J Am Acad Dermatol*. 2007;57:413-20. [PMID: 17368631].
7. Johnson MG, Stout JE. Twenty-eight cases of *Mycobacterium marinum* infection: retrospective case series and literature review. *Infection*. 2015;43:655-62. [PMID: 25869820].
8. Hashish E, Merwad A, Elgaml S, et al. *Mycobacterium marinum* infection in fish and man: epidemiology, pathophysiology and management; a review. *Vet Q*. 2018;38:35-46. [PMID: 29493404].
9. Rallis E, Koumantaki-Mathioudaki E. Treatment of *Mycobacterium marinum* cutaneous infections. *Expert Opin Pharmacother*. 2007;8:2965-78. [PMID: 18001256].
10. Griffith DE, Aksamit T, Brown-Elliott BA, et al. An official ATS/IDSA statement: diagnosis, treatment, and prevention of nontuberculous mycobacterial diseases. *Am J Respir Crit Care Med*. 2007;175:367-416. [PMID: 17277290].
11. Edelstein H. *Mycobacterium marinum* skin infections. Report of 31 cases and review of the literature. *Arch Intern Med*. 1994;154:1359-

64. [PMID: 8002687].