

UC Davis

Dermatology Online Journal

Title

Polydactyly in neurofibromatosis type I: a potential clue to diagnosis

Permalink

<https://escholarship.org/uc/item/0mw2g28q>

Journal

Dermatology Online Journal, 22(11)

Authors

Kimes, Kate L
Han, Marie J
Brown, Patrick J

Publication Date

2016

DOI

10.5070/D32211033144

Copyright Information

Copyright 2016 by the author(s). This work is made available under the terms of a Creative Commons Attribution-NonCommercial-NoDerivatives License, available at <https://creativecommons.org/licenses/by-nc-nd/4.0/>

Peer reviewed

**Volume 22 Number 11
November 2016**

Case report

Polydactyly in neurofibromatosis type I: a potential clue to diagnosis

Kate L. Kimes DO, Marie J. Han MD, Patrick J. Brown MD

Dermatology Online Journal 22 (11): 7

San Antonio Uniformed Services Health Education Consortium, Lackland Air Force Base, San Antonio, Texas

Correspondence:

Marie J. Han, M.D.
Lt Col, U.S. Air Force
Department of Dermatology
San Antonio Uniformed Services Health Education Consortium
Lackland Air Force Base, San Antonio, Texas
5 Cheshire Court
San Antonio, TX 78218
Email: mariehan7@gmail.com

Abstract

Neurofibromatosis type 1 is a genetic disorder characterized by variable phenotypic manifestations. The diagnostic criteria, established in 1987, are broad to encompass these pleiotropic findings. Included are the specific osseous manifestations of sphenoid dysplasia and dysplasia or thinning of the cortex of long bones. This review highlights recent evidence on the role of neurofibromin in bone development and suggests consideration for additional diagnostic criteria.

Key Words: Neurofibromatosis type 1; neurofibromin; fibroblast growth factor; polydactyly; osseous malformations; sphenoid dysplasia; sonic hedgehog

Introduction

Neurofibromatosis type 1 (NF1) is a common autosomal dominant disorder with a worldwide prevalence of 1 in 3000 individuals. It is characterized by complete penetrance, but variable phenotypic manifestations. These pleiotropic findings include café-au-lait macules, neural tumors, Lisch nodules, and skeletal disorders. The variable phenotypic expression of *NF1* demonstrates the gene's importance in multiple systems. The product of the NF1 gene (*NF1*), neurofibromin, contains a catalytic domain for GTPase activating proteins, which are crucial for the regulation of Ras. The downstream mediators of Ras signaling, MAPK and PI3K, have a major role in cell proliferation and differentiation, thus making neurofibromin a critical multi-system regulatory protein [1].

Variable expression of *NF1* historically made it difficult to establish criteria for the diagnosis of NF1. The National Institutes of Health (NIH) Consensus Development Conference established the current criteria for diagnosis in 1987 [2]. Based on these guidelines, a diagnosis of NF1 can be made with any two of the following clinical features: six or more café-au-lait spots of specific size based on the patient's age, axillary or inguinal freckling, two or more neurofibromas or one or more plexiform neurofibromas, two or more Lisch nodules, an optic glioma, a first-degree relative with NF1, or distinctive osseous lesions. According to NIH criteria, these distinctive osseous lesions include dysplasia of the sphenoid bone or dysplasia/thinning of long

bone cortices [1]. Recent research and enhanced understanding of the role of neurofibromin in bone development suggests a possibility to broaden the criteria for diagnosis of NF1 in regard to osseous manifestations. Herein we describe preaxial polydactyly in a patient meeting criteria for diagnosis of NF1 but lacking the classic osseous findings recognized by NIH criteria.

Case synopsis

A 37-year-old man was referred to the dermatology clinic for evaluation of multiple skin growths as part of his armed forces retirement physical following a successful 20-year military career. At presentation, the patient had at least ten typical café-au-lait macules, each greater than 15mm, and approximately 20 cutaneous neurofibromas, but lacked inguinal freckling, Lisch nodules, scoliosis, a history of a pathologic fracture, neurologic disease, or plexiform neurofibroma. Interestingly, he also had preaxial polydactyly of the right thumb (bifid thumb), stable since birth (Figure 1). The café-au-lait macules arose, to the best of his recollection, during childhood, but never garnered further workup. He started developing cutaneous neurofibromas in the third decade of life, but it wasn't until his mid-30s that they became numerous. He had never been given a diagnosis of NF1, nor was there a known family history of NF1.

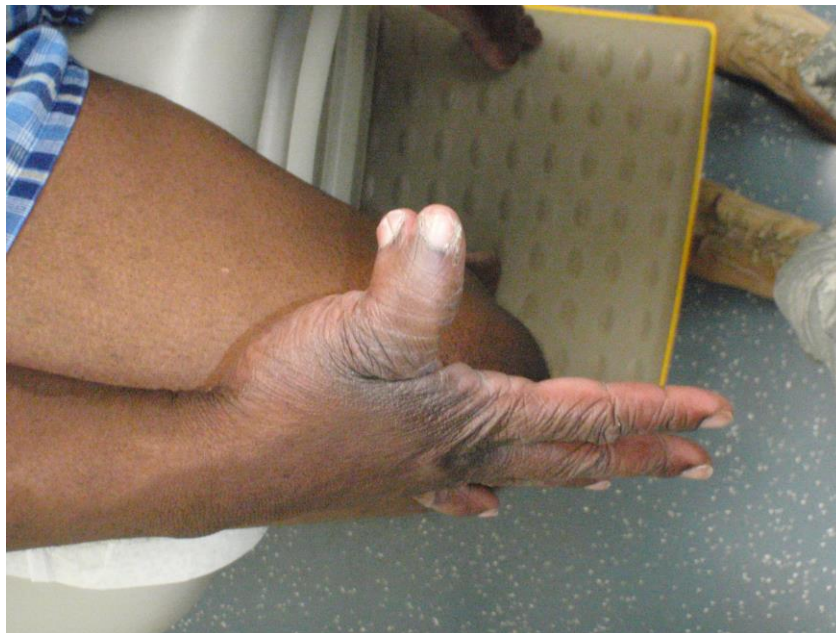

Figure 1. Isolated pre-axial polydactyly of the right thumb. No other bony abnormalities were noted on exam.

Discussion

This case highlights how the utilization of osseous malformations other than the classic lesions outlined by the NIH criteria may be used to heighten suspicion for NF1 from a young age. Skeletal manifestations of NF1 are present in up to 50% of patients [3]. Many are congenital dystrophies, but other abnormalities, such as scoliosis (which occurs in 10-20% of NF1 patients), may be acquired secondary to neurofibromas [1, 3]. The classic, primary lesions include unilateral sphenoid dysplasia, seen in 3-7% of patients, and, in an additional 3% of patients, pseudoarthrosis of the tibia [4, 5]. Other characteristic osseous manifestations may be present such as macrocephaly, sphenoid wing dysplasia, scoliosis, vertebral dysplasia, short stature, pseudoarthrosis, abnormalities of the rib cage, local bony overgrowth, genu varum/valgum, lytic bone lesions, osteosclerosis, syndactyly, and absent patellae [6].

Neurofibromin has multiple roles in skeletal development including joint formation, growth plate function, and control of vessel growth [6]. Osteoblasts, osteoclasts, chondrocytes, fibroblasts, and vascular endothelial cells all express neurofibromin [4]. Although *NF1* is expressed in both endochondral and intramembranous bone, the osseous manifestations of NF1 are more commonly located in bones formed through endochondral ossification, including the sphenoid. This may relate to an absence of functioning neurofibromin in sites of transition from proliferative to mature hypertrophic cartilage, which, under physiological conditions, is essential for progression to mineralized endochondral bone [3, 6]. In addition, improper bone development and homeostasis secondary to disruption of the delicate balance between osteoblasts and osteoclasts may explain other osseous abnormalities common to NF1, such as pseudoarthrosis [4, 6, 7]. This can lead to delayed formation of secondary ossification centers, decreased alkaline phosphatase leading to decreased mineralization, increased porosity, and limb shortening [6].

Considerable overlap in osseous findings exists between NF1 and activation of FGF in murine models [6]. Like neurofibromin, the downstream effects of FGF signaling are mediated via the Ras/MAPK pathway (Figure 2). In concert with sonic hedgehog (SHH) activation, Ras is responsible for cell proliferation in developing limbs [8]. Excess SHH results in ectopic production of digits, leading to polydactyly [9]. Although osseous SHH overexpression in neurofibromin deficient mice has never been demonstrated to the best of our knowledge, the upregulation of SHH in plexiform neurofibromas and other neurofibromin-deficient cells where Ras activity is increased leads us to believe SHH expression would be increased during limb development as well [10, 11].

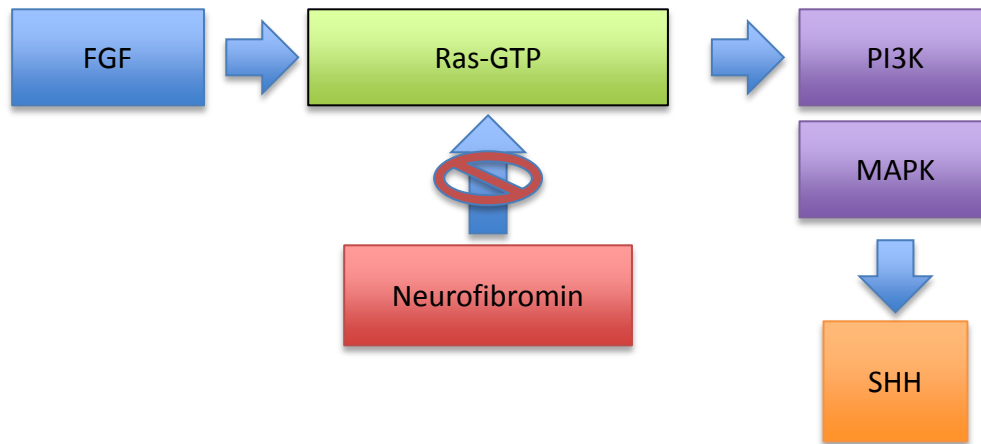


Figure 2. Disruption of activating FGF and inhibitory Neurofibromin effects on Ras results in dysregulation of downstream SHH signaling. SHH signaling is crucial for specifying the identity and number of digits.

If confirmed, our suspected association between neurofibromin deficiency and increased SHH expression in limb development supports the consideration of polydactyly as an associated finding of NF1. Indeed, there is a small body of literature to support such an association (Table 1). In a study of 135 patients with NF1, 12 (8.8%) had congenital bone malformations. Four (2.9%) of the 12 had polydactyly and two of those four had preaxial polydactyly (1.5%). This is more than 20x the prevalence of polydactyly in the general population (0.014-0.12%, [12]). Interestingly, the patients in this study with polydactyly lacked other, more characteristic NF1 osseous abnormalities [12]. Another case report showed bilateral symmetrical polysyndactyly of the great toes (preaxial polydactyly type IV) in a patient with NF1. This patient also did not have any other known bone malformations [13]. In addition, polydactyly has been reported at a rate of 2% in association with Legius syndrome, another syndrome involving the RAS-MAPK pathway [14]. This association further suggests that polydactyly should be an additional clinical clue in a patient with other manifestations indicative of NF1 and/or the RAS-MAPK pathway syndromes.

Table 1. Preaxial polydactyly in patients with NF1.

| Patient | NF1 diagnostic signs | Osseous manifestations |
|-------------------|--|--|
| 37 year old male* | Café-au-lait spots, cutaneous neurofibromas | Preaxial polydactyly R thumb |
| 7 month old male | Café-au-lait spots, maternal FH | Bilat preaxial polysyndactyly great toes and bilat clinodactyly fifth fingers |
| 15 day old female | Café-au-lait spots, freckling, nodular neurofibromas, lisch nodules, FH | Preaxial polydactyly R foot and postaxial polydactyly in bilat hands and L foot |
| 11 year old male | Café-au-lait spots, freckling, dermal and nodular neurofibromas, lisch nodules | Bilat incipient preaxial polydactyly of thumbs with partly duplicated and coalesced short unguinal phalanges |

* Current patient.

Conclusion

Neurofibromatosis type 1 is a complex diagnosis with variable bony manifestations. Since the initial development of NF1 diagnostic criteria 25 years ago, our understanding of the role of neurofibromin in osseous development has expanded significantly. Although further research is necessary to confirm our suspicion of SHH overexpression leading to polydactyly in NF1, we believe clinical consideration of NF1 in patients with atypical bony abnormalities not otherwise meeting established

diagnostic criteria for NF1 is prudent. In our patient, congenital polydactyly with multiple café-au-lait macules forming in childhood could have heightened the suspicion for NF1 from an early age.

References

1. Ward BA, Gutmann DH. Neurofibromatosis type 1: From lab bench to clinic. *Pediatr Neurol* 2005;32:221–8. [PMID: 15797177]
2. Williams VC, Lucas J, Babcock MA, Gutmann DH, Korf B, Maria BL. Neurofibromatosis type 1 revisited. *Pediatrics* 2009;123:124–33. [PMID: 19117870]
3. Kuorilehto T, Nissinen M, Koivunen J, Benson MD, Peltonen J. NF1 tumor suppressor protein and mRNA in skeletal tissues of developing and adult normal mouse and NF1-deficient embryos. *J Bone Miner Res* 2004; 19:983–989. [PMID: 15125795]
4. Schindeler A, Little DG. Recent insights into bone development, homeostasis, and repair in type 1 neurofibromatosis (NF1) *Bone* 2008;42(4):616–622. [PMID: 18248783]
5. Alwan, S., Tredwell, S.J., and Friedman, J.M. Is osseous dysplasia a primary feature of neurofibromatosis 1 (NF1)? *Clin. Genet* 2005;67, 378–390. [PMID: 15811002]
6. Kolanczyk M, Kossler N, Kühnisch J, Lavitas L, Stricker S, Wilkening U, et al. Multiple roles for neurofibromin in skeletal development and growth. *Human Molecular Genetics* 2007; 16(8):874-886. [PMID: 17317783]
7. Wu X, Estwick SA, Chen S, Yu M, Ming W, Nebesio TD, et al. Neurofibromin plays a critical role in modulating osteoblast differentiation of mesenchymal stem/progenitor cells. *Human Molecular Genetics* 2006;15(19):2837–2845. [PMID: 16893911]
8. Thisse B, Thisse C. Functions and regulations of fibroblast growth factor signaling during embryonic development. *Developmental Biology* 2005;287: 390–402. [PMID: 16216232]
9. Lettice LA, Williamson I, Wiltshire JH, Peluso S, Devenney PS, Hill AE, et al. Opposing functions of the ETS factor family define *Shh* spatial expression in limb buds and underlie polydactyly. *Dev. Cell* 2012;22:459–467. [PMID: 22340503]
10. Endo H, Momota Y, Oikawa A, Shinkai H. Psoriatic skin expresses the transcription factor Gli1: possible contribution of decreased neurofibromin expression. *Br J Dermatol* 2006;154:619–623. [PMID: 16536802]
11. Levy P, Vidaud D, Leroy K, Laurendeau I, Wechsler J, Bolasco G, et al. Molecular profiling of malignant peripheral nerve sheath tumors associated with neurofibromatosis type 1, based on large-scale real-time RT-PCR. *Mol Cancer* 2004;3:20. [PMID: 15255999]
12. Ruggieri M, Pavone V, De Luca D, Franzo A, Tine A, Pavone L. Congenital bone malformations in patients with neurofibromatosis type 1 (Nf1). *J Pediatr Orthop* 1999;19:301–305. [PMID: 10344311]
13. Shinawi M, Patel MS. Preaxial polydactyly in neurofibromatosis 1. *Clin Dysmorphol* 2007 Jul;16(3):193-4. [PMID: 17551336]
14. Denayer E, Chmara M, Brems H, Kievit AM, van Bever Y, et al. Legius syndrome in fourteen families. *Hum Mutat.* 2011;32:E1985–98. [PMID: 21089071]

The views expressed are those of the authors and do not reflect the official views or policy of the Department of Defense, or its Components

Abbreviations

| | |
|--------------|----------------------------------|
| NF1: | Neurofibromatosis Type 1 |
| <i>NF1</i> : | Neurofibromatosis 1 gene |
| GTP: | Guanosine-5'-Triphosphate |
| MAPK: | Mitogen-Activated Protein Kinase |
| PI3K: | Phosphoinositide 3-Kinase |
| FGF: | Fibroblast Growth Factor |
| SHH: | Sonic Hedgehog |