

UC Davis

Dermatology Online Journal

Title

Cutaneous collagenous vasculopathy: development after coronary artery bypass surgery

Permalink

<https://escholarship.org/uc/item/0k8258qw>

Journal

Dermatology Online Journal, 24(5)

Authors

Rahnama-Moghadam, Sahand
Burgin, Callie
Gilbert, Juliana
et al.

Publication Date

2018

DOI

10.5070/D3245040142

Copyright Information

Copyright 2018 by the author(s). This work is made available under the terms of a Creative Commons Attribution-NonCommercial-NoDerivatives License, available at <https://creativecommons.org/licenses/by-nc-nd/4.0/>

Peer reviewed

Cutaneous collagenous vasculopathy: development after coronary artery bypass surgery

Sahand Rahnama-Moghadam MD MS, Callie Burgin BS, Juliana Gilbert MD, Simon Warren MBBS

Affiliations: Department of Dermatology, Indiana University School of Medicine, Indianapolis, Indiana, USA

Corresponding Author: Sahand Rahnama-Moghadam MD, MS, 545 Barnhill Drive, Indianapolis, IN 46202, Tel: 260 413 7273, Email: srahnama@iupui.edu

Abstract

Cutaneous collagenous vasculopathy (CCV) is a rare benign microangiopathy of the superficial dermal vessels. Clinically, it is characterized by widespread, asymptomatic development of cutaneous telangiectasia in the absence of systemic symptoms. Morphologically, it most resembles generalized essential telangiectasia and other telangiectatic syndromes such as telangiectasia macularis eruptiva perstans (TMEP), ataxia telangiectasia, and hereditary hemorrhagic telangiectasia. It is distinctive in its histology, showing characteristic dilated thick-walled blood vessels in the superficial dermis. The thickened walls of these superficial dermal blood vessels demonstrate reduplication of the basement membrane on PAS staining. We report a 63-year-old man with CCV with this condition for 20 years, starting in 1996. He was diagnosed in the past as having essential telangiectasia. The development of the telangiectasias occurred after coronary artery bypass grafting, also performed in 1996. This case not only demonstrates the characteristic clinical and histologic findings, but also suggests a possible mechanism. Moreover, it illustrates that cases of generalized essential telangiectasia may in fact be CCV that are misclassified.

Keywords: cutaneous collagenous vasculopathy, generalized essential telangiectasia

Introduction

Cutaneous collagenous vasculopathy (CCV) is a rare benign idiopathic microangiopathy of the superficial dermal vessels. Initially described in 2000 [1], it is a likely underdiagnosed cause of generalized telangiectasia as we are aware to date of only 28

cases that have been reported in the literature. Clinically, the condition starts with asymptomatic development of telangiectasia, often on the extremities, that insidiously progresses to the development of widespread telangiectasia. The clinical differential diagnosis includes generalized essential telangiectasia, telangiectasia macularis eruptiva perstans, and sometimes a pigmented purpuric dermatosis. However, the histology is distinctive: dilated superficial dermal vessels with thickened hyalinized blood vessel walls. These walls stain positively with PAS or Masson trichome stains and demonstrate immunoreactivity to collagen IV, suggesting reduplication of the vessel basement membrane [2]. The etiopathogenesis is unknown but has been hypothesized to be related to a deleterious stimulus such as localized ischemia.

Case Synopsis

A 63-year-old man presented to the dermatology clinic for an asymptomatic eruption present for 20 years. The eruption had first developed distally on the forearms and lower legs and then later included the inner thighs and the lower back. The patient noted that he had developed these lesions a few weeks after he had coronary artery bypass surgery. His medical history was significant for coronary artery disease and hypertension. He was a former smoker. He denied having photosensitivity. He denied applying any topical medications, chemicals, or cosmetics to the affected areas. He had no constitutional symptoms such as fevers, night sweats, or weight loss. He did not have diarrhea, flushing, arthralgias, or joint stiffness. There was no family history of any skin disorders, autoimmune

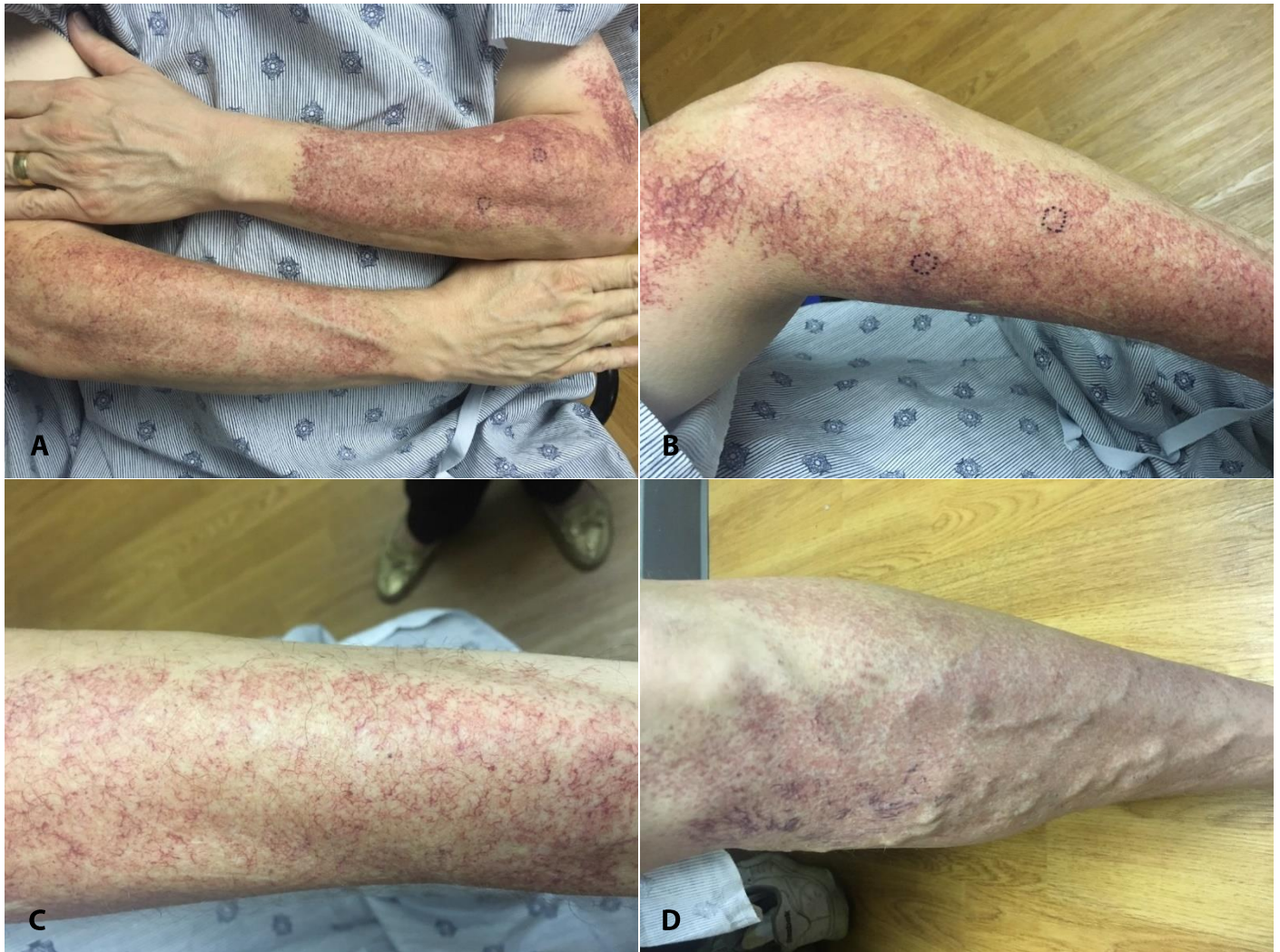

Figure 1: Clinical presentation of cutaneous collagenous vasculopathy with macular telangiectasia on the arms (A, B, C) and lower leg (D).

disease, neurologic disorders, bleeding disorders, or cancer.

On examination, there was an eruption consisting of well-demarcated patches of telangiectasia on the forearms, lower legs, inner thighs, and lower back (**Figure 1**). The telangiectasias were non-blanchable and linear—no mat-like telangiectasia nor dome-shaped telangiectasias were present. The oral and ocular mucosa were clear, no telangiectasias were present on the ears. The patient had no neurologic deficits.

Two punch biopsies were taken of the skin of the left forearm. On histopathology, there were telangiectasias in the superficial dermis with collagen deposition around the vessel lumen. PAS

stain was positive supporting the finding of collagen deposition. Congo red stain was negative ruling out the deposition of amyloid around vessel walls (**Figure 2**).

Case Discussion

We report a 63-year-old man who developed an asymptomatic eruption shortly after coronary artery bypass graft twenty years prior to presentation and was initially misdiagnosed with essential telangiectasia. He has remained asymptomatic and recently presented to dermatology clinic where punch biopsy revealed his definitive diagnosis of CCV.

Cutaneous collagenous vasculopathy is an uncommon, benign, idiopathic microangiopathy

first described in 2000 by Salama and Rosenthal in a 54-year-old man with five-year history of asymptomatic generalized telangiectasia [1]. As the typical clinical presentation of CCV is of asymptomatic blanchable macules on lower extremities that spread to the trunk and upper extremities over time while sparing mucosal surfaces and nail beds, it often mimics generalized essential telangiectasia [3]. Histopathological evaluation reveals the defining characteristics of CCV: dilation of superficial dermal vessels with perivascular hyalinization with hematoxylin and eosin staining that is enhanced by PAS-D staining. Although morphologically similar to amyloid, the perivascular thickening of CCV is Congo red negative. Immunohistochemical staining with an antibody to

collagen type IV also reveals basement membrane duplication [1, 4].

To date, 28 cases of CCV have been reported; all were recently summarized in literature reviews accompanying case reports [5, 6]. CCV has been diagnosed in adult patients from 41- 85 years old with the average age of onset being 62 years. One case has been described in an adolescent who was diagnosed at age 16 [7]. Development of CCV shows no significant gender bias, has never been reported to involve oral mucosa or conjunctiva, and is overwhelmingly asymptomatic at presentation [5]. The most common co-morbidities are cardiovascular, similar to the ones our patient had, including diabetes mellitus, hypertension, hyperlipidemia, myocardial infarction, venous

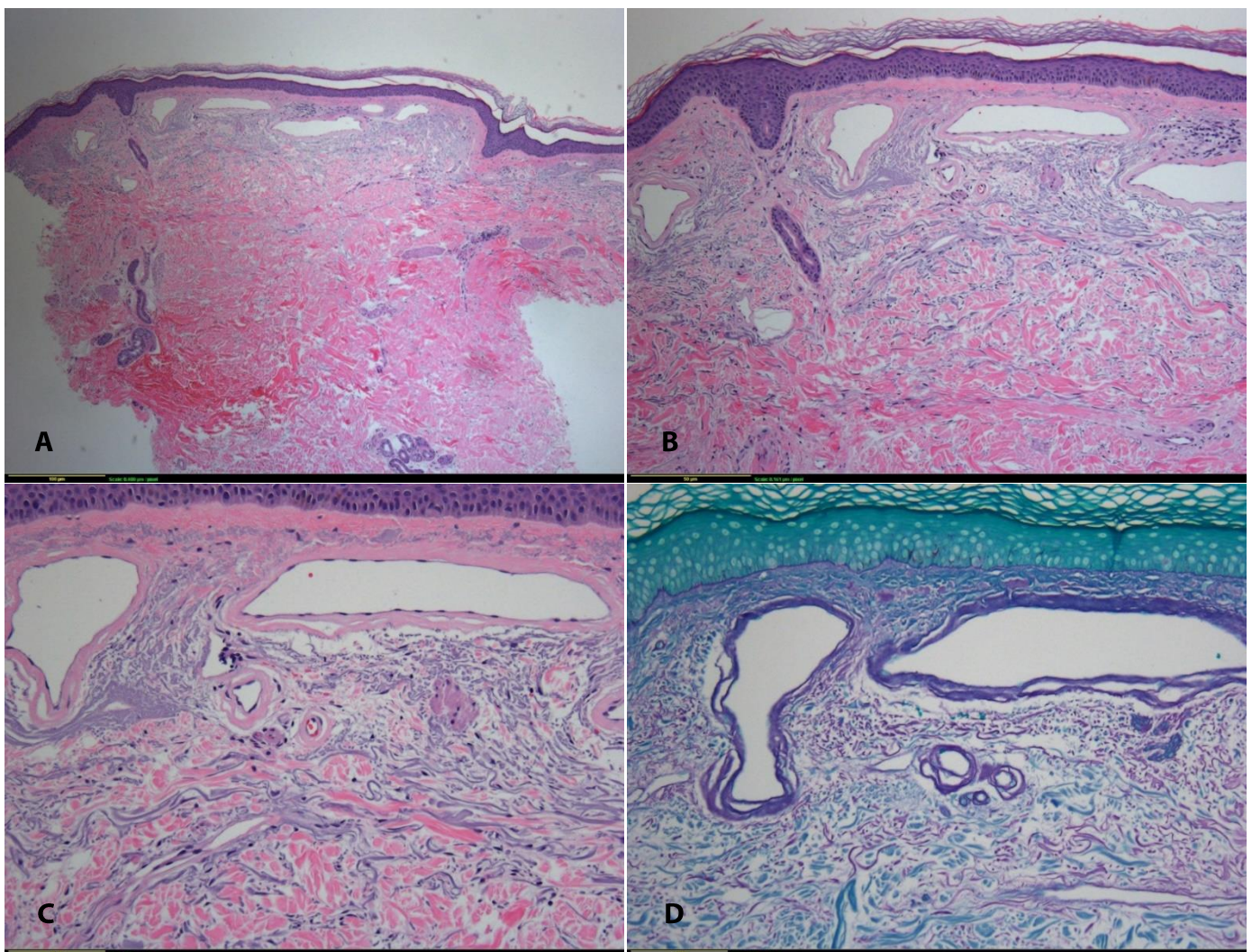


Figure 2: H&E staining showing telangiectasias in the superficial dermis and collagen deposition around vessel lumen at 4× (A), 10× (B) and 20× (C). Periodic acid-Schiff staining confirming collagen deposition around vessel lumen at 20× (D).

insufficiency, mitral valve disease, atrial fibrillation, supraventricular tachycardia, and Raynaud phenomenon [6]. The pathogenesis of CCV is not yet known with certainty. However, a genetic defect leading to production of disorganized collagen in dermal microvasculature was proposed in the initial case report[1]. Later case reports failed to demonstrate the characteristic Luse bodies or fusiform widely spaced collagen with abnormal banding.

A second mechanism implicated veil cells and their role in vessel repair and potential to deposit the abnormal collagen in vessel walls [1]. Intravascular factors or systemic disease that leads to vascular damage could play a role in CCV pathogenesis.

Interestingly, a recent report described CCV development in a woman with metastatic breast cancer being treated with gemcitabine [8]. She presented with hypotension, tachycardia, malaise, and telangiectasias on the legs after 8 days of gemcitabine. Supportive treatment allowed resolution of symptoms and improvement of the rash.

References

1. Salama S, Rosenthal D. Cutaneous collagenous vasculopathy with generalized telangiectasia: an immunohistochemical and ultrastructural study. *J Cutan Pathol*. 2000 Jan;27(1):40-8. [PMID: 10660131].
2. Burdick LM, Lohser S, Somach SC, Billings SD. Cutaneous collagenous vasculopathy: a rare cutaneous microangiopathy. *J Cutan Pathol*. 2012 Aug;39(8):741-6. [PMID: 22804092].
3. Brady BG, Ortleb M, Boyd AS, Powers J. Cutaneous Collagenous Vasculopathy. *J Clin Aesthet Dermatol*. 2015 Nov;8(11):49-52. [PMID: 26705441].
4. Davis TL, Mandal RV, Bevona C, Tsai KY, Moschella SL, Staszewski R, Zembowicz A. Collagenous vasculopathy: a report of three cases. *J Cutan Pathol*. 2008 Oct;35(10):967-70. [PMID: 18537865].
5. Castiñeiras-Mato I, Rodríguez-Lojo R, Fernández-Díaz ML, Bal-Nieves F. Cutaneous Collagenous Vasculopathy: A Case Report and Review of the Literature. *Actas Dermosifiliogr*. 2016 Jun;107(5):444-7. [PMID: 26829992].
6. Motegi SI, Yasuda M, Yamanaka M, Amano H, Ishikawa O. Cutaneous collagenous vasculopathy: Report of first Japanese case and review of the literature. *Australas J Dermatol*. 2017 May;58(2):145-9. [PMID: 26820098].
7. Lloyd BM, Pruden SJ 2nd, Lind AC, Berk DR. Cutaneous collagenous vasculopathy: report of the first pediatric case. *Pediatr Dermatol*. 2011 Sept-Oct;28(5):598-9. [PMID: 21916964].
8. Leone JP. Gemcitabine Induced Cutaneous Collagenous Vasculopathy in a Breast Cancer Patient. *Breast J*. 2016 Sept;22(5):580. [PMID: 27346284].
9. Krell JM, Sanchez RL, Solomon AR. Diffuse dermal angiomatosis: a variant of reactive cutaneous angioendotheliomatosis. *J Cutan Pathol*. 1994 Aug;21(4):363-70. [PMID: 7798394].
10. Rongioletti F, Rebora A. Cutaneous reactive angiomatoses: patterns and classification of reactive vascular proliferation. *J Am Acad Dermatol*. 2003 Nov;49(5):887-96. [PMID: 14576670].

In our case, our patient developed the telangiectasias during the post-operative period after CABG. This is in keeping with the hypothesis that a noxious stimulus such as hypoxia or possibly a drug exposure sometimes plays a role in the development of CCV. This is most analogous to the pathophysiology of diffuse dermal angiomatosis, in which there is diffuse proliferation of endothelial cells between collagen bundles in the setting of arterial insufficiency [9, 10].

In conclusion, cutaneous collagenous vasculopathy is an uncommon idiopathic microangiopathy that is clinically identical to generalized essential telangiectasia. However, on histopathologic exam it is differentiated by PAS or Masson trichome-positive collagen IV deposition in the walls of vessels in the superficial dermis. Although the specific pathogenesis remains unknown, the case presented here suggests that a history of cardiovascular disease and a systemic stressor such as coronary artery bypass grafting may contribute to development of cutaneous collagenous vasculopathy